

Idiopathic intracranial hypertension: case report

G. Iacob¹, Andreea Marinescu²

¹Neurosurgery Clinic - University Hospital, Bucharest, Romania

²Radiology Clinic - University Hospital, Bucharest, Romania

Abstract: Idiopathic intracranial hypertension – IIH (synonymous old terms: benign intracranial hypertension - BIH, pseudotumor-cerebri - PTC) it's a syndrome, related to elevated intracranial pressure, of unknown cause, sometimes cerebral emergency, occurring in all age groups, especially in children and young obese womans, in the absence of an underlying expansive intracranial lesion, despite extensive investigations. Although initial symptoms can resolve, IIH displays a high risk of recurrence several months or years later, even if initial symptoms resolved. *Results:* A 20-year-old male, obese since two years (body mass index 30, 9), was admitted for three months intense headache, vomiting, diplopia, progressive visual acuity loss. Neurologic examination confirmed diplopia by left abducens nerve palsy, papilledema right > left. At admission, cerebral CT scan and cerebral MRI with angio MRI 3DTOF and 2D venous TOF was normal. Despite treatment with acetazolamide (Diamox), corticosteroid, antidepressants (Amitriptyline), anticonvulsivants (Topiramate) three weeks later headache, diplopia persist and vision become worse, confirmed by visual field assessment, visual evoked potential (VEP). A cerebral arteriography demonstrate filling defect of the superior sagittal sinus in the 1/3 proximal part and very weak filling of the transverse right sinus on venous time. Trombophylic profile has revealed a heterozygote V factor Leyden mutation, a homozygote MTHFR and PAI mutation justifying an anticoagulant treatment initiated to the patient. The MRI showed a superior sagittal sinus, right transverse and sigmoid sinus thrombosis, dilatation and buckling of the optic nerve sheaths with increased perineural fluid especially retrobulbar, discrete flattening of the posterior segment of the eyeballs, spinal MRI showed posterior epidural space with dilated venous branches, with mass effect on the spinal cord, that occurs pushed anterior on sagittal T1/T2 sequences cervical and thoracic. The opening pression of lumbar puncture, done with the patient in the lateral decubitus position, was 60 cm H₂O, the cytochemical CSF study were normal. The patient was operated: a lombo-peritoneal with a variable pressure valve was inserted. Two months after the patient general condition improved: he was without headache, abducens palsy and the visual field assessment, ocular motility examination, ophthalmoscopy were normal. *Conclusion:* IHH is rare, variable in evolution, and in many cases it disappears on its own within 6 months without affecting life expectancy.

Weight loss, fluid or salt restriction, in conjunction with medical treatment, angioplasty and venous stenting across the sinus stenosis under general anesthesia and surgical treatment (shunting, optic nerve sheath decompression and fenestration, gastric by-pass surgery) are treatment alternatives. Such disorder should be closely monitored because 10 to 25% of cases could be affected by recurrences or by permanent vision loss to those patients with resistant papilledema despite treatment.

Key words: idiopathic intracranial hypertension-IIH, benign intracranial hypertension - BIH, pseudotumor-cerebri - PTC, superior sagittal and transverse sinus thrombosis, intracranial pressure, visual evoked potential (VEP)

Introduction

Idiopathic intracranial hypertension – IIH (synonymous old terms: benign intracranial hypertension - BIH, pseudotumor-cerebri - PTC) it's a syndrome, related to elevated intracranial pressure of unknown cause, sometimes cerebral emergency, occurring in all age groups, especially in children and young obese women, with several symptoms including visual loss; without underlying expansive intracranial lesion, hydrocephalus, dural sinus thrombosis; with a recurrence potential months or even years later, even if initial symptoms resolved. (1-12)

Case report

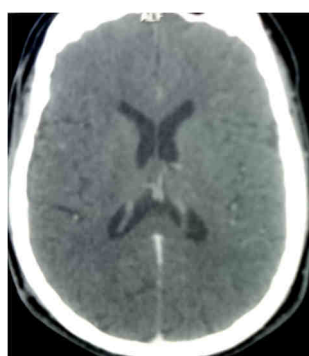
A 20-year-old male, obese since two years (body mass index 30,9), was admitted June 2015 in a neurology department for three months intense headache, vomiting, diplopia, progressive visual acuity loss. From his medical records we noticed: left otomastoiditis since childhood, a car accident with cranio-cerebral trauma in 2007 with a 3 mm nonoperated left subdural haematoma and epicranial haematoma. Clinical examination

revealed good clinical condition, without motor or sensitive deficits, orientated, no ataxia, ocular motility examination diplopia by left abducens nerve palsy, visual function tests: both eyes 2/3 without corrections, visual field assessment is normal with light colour desaturation for red and green, ophthalmoscopy: papilledema right > left, with peripapillary flame hemorrhages, venous engorgement. Angiofluoroscopy: arteriolar filling at 11 seconds, papillary leakage of contrast substance, both papilla becomes hyperfluorescent on late exposures, dilated vessels. The study of visual evoked potentials (VEP) has shown on the right eye latency of P100 wave 145 ms (normal value = 110 ms) and amplitude of 71 mV (normal value > 5 μV). To the left eye, the latency of P100 wave was 121 ms, amplitude of 58 mV.

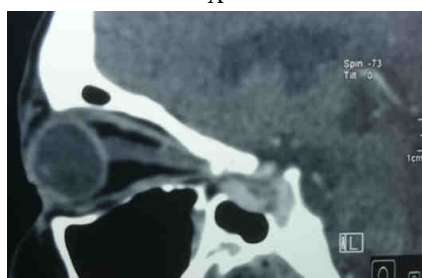
An immunologic screening demonstrated CRP positive, ANA positive, Ac anti DNA dc, Ac anti SM, Ac anti Ro, Ac anti La, cANCA, pANCA, Ac anti U1RNP, Ac anti GP1beta. An infectious screening was negative for Ac anti HIV, Ac anti HCV, Ag HBS, Ac anti CMV, Ac anti EBV, Ac anti HSV, Ac anti

Borrelia, Ac anti Mycoplasma, Ac anti Chlamydia, Ac anti Toxoplasma. TheRIA-screening for TSH, FSH, LH, PRL and GH found normal levels.

At admission, cerebral CT scan was normal (Figure 1). Cerebral MRI with angio MRI 3DTOF and 2D venous TOF showed: supra and infratentorial structures with normal morphology and normal MRI signal, no acute cerebral lesions visible in diffusion. On T2 EG sequence no hemorrhages supra or infratentorial, ventricular system with normal dimensions, shapes, topography. Selar and paraselar region, orbital region and optic nerves with normal MRI signal, no vascular malformations, normal dural sinuses.



A



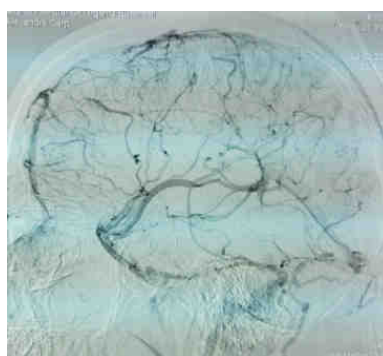
B

Figure 1 - Normal cerebral CT scan at admission:
A axial section, B sagittal section

The patient was put on a low calories diet, corticosteroid therapy was initiated and consisted of a bolus methylpredisolone - 1g/d for 5 days, followed by an oral corticosteroid dose decreasing over three weeks), associated with acetazolamide (Diamox 1g/d), antidepressant (Amitriptyline), anticonvulsant (Topiramate).

Three weeks later headache, diplopia persist and vision become worse (1/10 on the right side and 3/10 on the left side). A cerebral arteriography demonstrate normal arteriography on right side - arterial time; filling defect of the superior sagittal sinus in the 1/3 proximal part and very weak filling of the transverse right sinus on venous time. On the left side cerebral angiography was normal (Figure 2)

The opening pressure of lumbar puncture, done with the patient in the lateral decubitus position, was 60 cm H₂O, the cytochemical CSF study were normal (protein concentration: 0.23 g/l, CSF glucose: 0.42 g/l and 3 white cell /mm³).



A

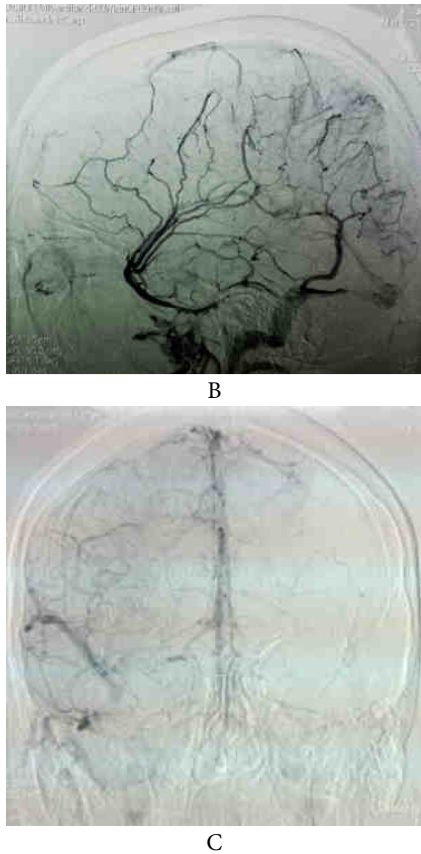


Figure 2 - Cerebral arteriography revealing venous filling defect of the superior sagittal sinus in the 1/3 proximal part (A&B sagittal view, C coronal view)

Trombophylic profile has revealed a heterozygote V factor Leyden mutation, a homozygote MTHFR and PAI mutation justifying an anticoagulant treatment initiated to the patient.

A new cerebral and spinal MRI revealed (Figure 3):

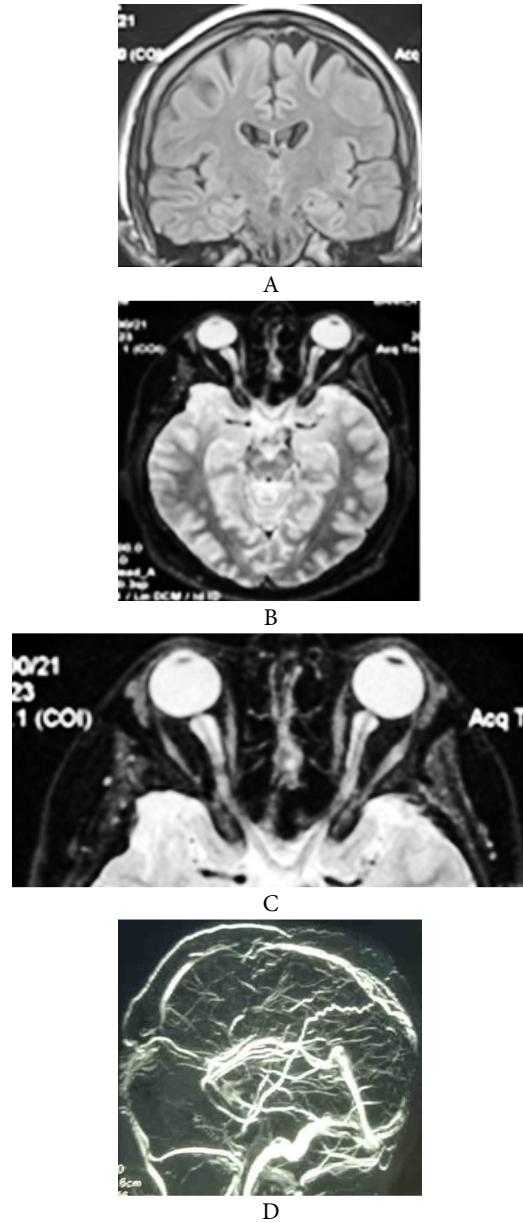


Figure 3 - Cerebral MRI

A coronal cerebral MRI (FLAIR): venous sinuses with gracile lumen

B&C detail: cerebral MRI (axial STIR): dilatation and buckling of the optic nerve sheaths with increased

perineural fluid especially retrobulbar, discrete flattening of the posterior segment of the eyeballs
 D: cerebral MRI (TOF sequence) confirming filling defect of the 1/3 anterior part of the superior sagittal sinus (SSS)

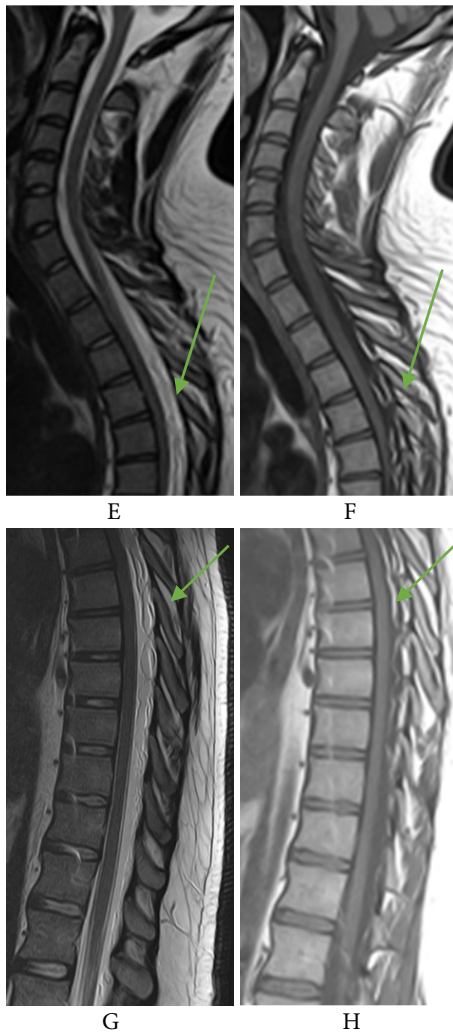


Figure 3 - Spinal MRI

EFGH: spinal MRI showed posterior epidural space with dilated venous branches, with mass effect on the spinal cord, that occurs pushed anterior on sagittal T1/T2 sequences cervico-thoracic and thoracic (arrows)

A week after, headache increased and the patient was transferred and operated to the Neurosurgery Department. A lombo-peritoneal shunt with a variable pressure Medtronic valve was performed. At operation the opening pressure of lumbar puncture, done with the patient in the lateral decubitus position was 85 cm H₂O. Two months after, the patient general condition improved: he was without headache, abducens palsy and the visual field assessment, ocular motility examination, ophthalmoscopy, visual evoked potentials were normal.

The peculiarity of this case lies in the progressive emergence of a severe idiopathic intracranial hypertension syndrome at a young male, age of 20 years, obese - recently installed, not leated to a endocranial cause, with normal hormonal tests, to which trombophylic profile has revealed a heterozygote V factor Leyden mutation, a homozygote MTHFR and PAI mutation; also the opening pressure of lumbar puncture, done with the patient in the lateral decubitus position, was initial 60 cm H₂O and at operation 85 cm H₂O. The medical treatment failed, but lombo-peritoneal shunt with a variable pressure Medtronic valve was beneficial.

Discussion

Idiopathic intracranial hypertension – IIH occurs in about 1-2 per 100,000 people, each year, with severe visual loss in 10-30% of patients, at a median age of 20-45 years and affects women four to nine times more frequent than men (6, 12, 13). In young obese women, the incidence of IIH has been shown

to reach 20 cases per 100,000 (1, 2, 13, 14). Although this condition has no genetic or ethnic predilection, studies have shown a higher prevalence of IIH in overweight and obese people (1, 2, 15).

Historical considerations (10, 11, 16, 17)

1893 Quincke Heinrich (18) is credited with the first report of IIH, wrong referring to serous meningitis

1904 Nonne Max (19) introduced the term "pseudo-tumor-cerebri" to define those patients in whom no tumour was found, but a disease mimicking a brain tumor was described

1937 Dandy Walter (20) identified the diagnostic criteria for IIH and introduced subtemporal decompressive surgery in the treatment of this disease

1949 ventriculo-peritoneal shunts were first used and were later replaced in 1971 by lumbo-peritoneal shunts, with better results

1954 Sir Charles Symonds (21) suggested middle ear infection as a cause of venous sinus thrombosis and otitic hydrocephalus

1955 same condition was renamed "benign intracranial hypertension" by Foley, cited by (11)

1969 Buchheit, cited by (16), introduced the term idiopathic intracranial hypertension, replacing the term 'benign intracranial hypertension', abandoned due to visual disturbances.

1989 the terminology of this disease was revised to "idiopathic (of no identifiable cause) intracranial hypertension"

1988-1993 optic nerve fenestrations – first described in 1871 were made after negative reports on shunting in the 1980s

Several conditions have been associated with IIH (2, 3, 5, 10, 11, 15, 22)

- obesity: obese women of childbearing age are more likely to the disorder due to elevated intraabdominal pressure, venous and even intracranial venous pressure. In our case obesity was recently installed, not related to an endocranial cause, with normal hormonal tests.

- onset of menstruation (menarche)
- pregnancy - at any stage
- medications (no fully clarified causal relation with this disorder) including: high-dose vitamin A > 100,000 U/day - see isotretinoin for acne, long-term antibiotherapy with penicillin, cyclosporine, minocycline, tetracycline, nalidixic acid, nitrofurantoin, carbidopa, levodopa, indomethacin, ketoprofen, corticosteroids - topical and systemic, phenytoin, growth hormone, oral contraceptives, tamoxifen, lithium and anabolic steroids
- diseases such as: Addison, Cushing's, Behcet's (23), polycystic ovary syndrome, systemic lupus erythematosus, multiple sclerosis, herpetic encephalitis, Reye syndrome, sleep apnea, chronic kidney disease, chronic respiratory insufficiency, familial mediterranean fever or others disorders, such as iron deficiency, anemia, uremia, thrombocytopenic purpura, hypothyroidism, hypoparathyroidism, psittacosis, metabolic, toxic causes
- disorders of cerebral venous drainage: secondary thrombosis due to coagulopathy, relative stenosis due to a venous flow anomaly or even extravascular tumors that may impair due absorption of CSF; increased venous red

blood cell (RBC) aggregation and relatively elevated fibrinogen concentrations.

To explain the pathogenesis of IIH, starting from 4 evidences: a high rate of occurrence in obese women during the childbearing years, CSF outflow has reduced conductance, normal ventricular size, no hydrocephalus and no histologic evidence of cerebral edema, several theories have been advanced, generating pathological conditions acting simultaneously as follows: (1-3, 11, 13, 24-26)

- the increased production of cerebrospinal fluid was the first hypothesis to be proposed, but later dismissed following experimental data (27)

- the increased resistance to cerebrospinal fluid absorption (13, 24)

- the increased blood flow to the brain or cerebral tissue was suggested using phase contrast MRA studies and biopsy samples. IIH is only an incomplete intracranial hypertension syndrome initial: increased intracranial pressure is very important, up to 60–80 mmHg, but the brain vascular auto regulation compensates the increase in intracranial pressure and maintains cerebral blood flow (24)

- restricted venous drainage, by narrowing or stenosis of two large sinuses in the brain low grade stenosis of the SSS and transverse sinus

- a condition which could be an effect or a cause of IIH: raised intracranial pressure causes venous narrowing in the transverse sinuses, resulting in venous hypertension (raised venous pressure), with decreased cerebrospinal fluid resorption via arachnoid granulations and further lead to a rise of

intracranial pressure and cerebral oedema (4, 17, 28-33)

- obesity increases intra-abdominal pressure, raises cardiac filling pressures and impedes venous return from the brain due to the valveless venous system that exists from the brain to the heart, with a subsequent elevation in intracranial venous pressure, chronic interruption of the axoplasmic flow of the optic nerves and ensuing papilledema as a consequence of this pressure, leading to irreversible optic neuropathy (2)

IIH diagnosis (1, 3), is based on the criteria devised by Dandy in 1937 (20) and subsequently modified by:

- Smith 1985 (34) replaced ventriculography with CT scan

- Digre and Corbett 2001 (3) added the requirement that the patient is awake and alert, no other cause for the raised ICP is found, including exclusion of venous sinus thrombosis as an underlying cause

- Friedman and Jacobson 2002 (35) MR venography is only required in atypical cases: men and woman with normal weight age over 44 years, prepubertal children.

- the lumbar puncture should be performed with patient lying sideways

Current diagnostic IIH criteria (1-3, 5, 15, 29, 35, 36) require the following:

1. signs and symptoms of intracranial hypertension syndrome

- moderate to severe headaches in 92–94% of cases, revealing, progressive, starting retroorbital, worsening with eye movement, generalized in character and throbbing in nature, especially in the morning or during

physical activity; exacerbated by coughing and sneezing

- radicular pain - uncommon symptom, usually in the neck and shoulders

- nausea, vomiting

- dizziness

- pulsatile tinnitus in one or both ears (64–87%), synchronous with the pulse (37)

- visual disturbances (80 % of cases): blurred or distortion (metamorphopsia) of central vision - caused by macular wrinkling and subretinal fluid spreading from the swollen optic disc, often predominantly orthostatic, initially in the periphery, in the nasal inferior quadrant but progressively towards the center of vision; loss of color vision; visual obscurations affecting one or both eye – seconds lasting episodes or blindness in 30% of cases; photopsia - light flashes; sudden visual loss in 91% of cases due to ischemic optic neuropathy or a retinal vascular occlusion associated with the papilledema; diplopia by abducens palsy uni or bilateral. Rarely, patients presenting with increased ICP with related optic nerve edema may be asymptomatic. Visual acuity is usually normal until significant peripheral visual field loss with progressive postpapilledema by optic atrophy has occurred (23). In children, numerous nonspecific signs and symptoms may be present: numbness of the extremities, generalized weakness, loss of smell and coordination; rarely third, fourth or even facial nerve palsy uni or bilateral may appear (15, 35), papilledema in addition to subretinal hemorrhages are poor visual prognostic signs. Uncontrolled papilledema results in

progressive peripheral visual field constriction or nerve fiber bundle defects (11).

2. normal neurological examination excepting diplopia by abducens palsy, uni or bilateral

3. the patient is awake and alert

4. normal cranio-cerebral and spinal investigations (1-3, 36, 38-42)

- CT with and without contrast, angio-CT venous time

- emergency MRI including the following sections: native in sagittal T1, axial: T2 flair, diffusion T2*;with contrast (Gadolinium)T1 fat sat on orbits, axial cuts T1 on the brain; using axial and coronal sections 2 mm thick centered on orbits FSE T2

- MR venography, a cerebral angio MRV with gadolinium and manometry to exclude the possibility of an intracranial mass, a cerebral venous sinus thrombosis, venous sinus stenosis/obstruction or a dural fistula, to explain physiopathology or even for therapeutic interest to implant a stent (4, 5, 15, 32, 35).

IIH commonly presents with: normal or small (slit-like) and symmetric lateral ventricles, tortuous optic nerves, dilatation and buckling of the optic nerve sheaths with increased perineural fluid (42), minimal flattening of the posterior segment of the eyeballs, bulging optic discs, possible moderate to severe smooth-walled venous stenosis affecting the longitudinal or transverse sinus; "empty sella sign" (flattening of the pituitary gland due to increased pressure) and enlargement of Meckel's caves (41). Occasionally: T2 signal intensity of the optic nerve, discreet ptosis of cerebellar tonsils

(40). Follow-up MRI or CT scans may be needed to rule out hidden cancer.

5. increased opening pressure of lumbar puncture, performed with the patient in the lateral decubitus position, CSF pressure > 25 cmH₂O with normal biochemical and cytological composition of CSF

6. no other explanation for the raised intracranial pressure as metabolic, toxic or hormonal

In addition to IHH diagnostic criteria the following investigations should be performed (1-3, 11, 15):

Visual function tests, visual field assessment, ocular motility examination, ophthalmoscopy (funduscopy) are mandatory to diagnose and monitor patients with IHH. At ophthalmoscopy: papilledema is seen in 95% of cases, without correlation with visual impairment severity, absent or unilateral especially in young children, sometimes bilateral, asymmetric; peripapillary flame hemorrhages, venous engorgement, hard exudates, telangiectatic vessels on the disc surface, opticociliary shunt veins. Chronic papilledema is associated with optic disc pallor, Paton lines (arc-shaped retinal wrinkles concentric with disc margin) along the temporal side of inferior pole of disc. Late chronic optic atrophy can also be seen: decreased visual acuity with significant peripheral visual field loss especially in the inferior nasal quadrant of the visual field, diffuse pallor of disc and absence of small arterial vessels on surface are noted, with very little disc elevation. Disc margin in the upper and lower poles and nasal margin is obscured by some residual edema in nerve fiber layer

and gliosis that often persists even after all edema has resolved. In general the impact of idiopathic HIC on visual function is usually appreciated by repeated studies of the visual field, also by altered visual evoked potential (VEP) - see our case too (41).

- blood tests to patients with IHH (1, 2, 5) are necessary for ruling out systemic lupus erythematosus, collagen-vascular diseases, to identify the procoagulant profile, etcetera. They include: complete blood count, erythrocyte sedimentation rate, serum iron, iron-binding capacity, full procoagulant profile regardless to those patients of previous history of thrombosis or MRI - including protein S, protein C, homocysteine levels, antithrombin III, factor V Leiden variant, antiphospholipid/anticardiolipin antibodies, lupus anticoagulant and platelet aggregation studies; also antinuclear antigen (ANA) profile (eg, anti-dsDNA and anti-ssDNA), Lyme screening test - enzyme-linked immunosorbent assay ELISA to those patients who have a history of exposure to Lyme in areas of endemic disease.

- cerebrospinal fluid studies (2, 11) include the following: opening pressure, white blood cell and differential counts, red blood cell count, total protein, quantitative protein electrophoresis, glucose, bacterial culture and sensitivity, Cryptococcal antigen - especially in patients with HIV, Syphilis markers - eg, rapid plasma reagin- RPR, tumor markers and cytology (in patients with a history of cancer or with clinical features suggesting occult malignancy)

IHH treatment goals are (2, 3, 15, 23, 31, 39, 43, 44): the prevention of visual loss and

blindness, symptom control, weight loss, fluid or salt restriction.

Medical treatment (1-3, 7, 43, 44) is based on: acetazolamide (Diamox) for six months - in conjunction with a low-sodium weight-reduction diet modestly improved vision, reduced intracranial pressure, improved quality of life and reduced papilledema; furosemide; digoxin (reduces CSF production by as much as 78% in humans, probably by inhibiting the Na-K-ATPase pump); analgesics: primary headache prophylaxis with antidepressants (Amitriptyline), anticonvulsants (Topiramate); corticosteroids - as in our case is useful especially in patients with papilledema (reducing CSF production by as much as 78% in humans, probably by inhibiting the Na-K-ATPase pump binder). Repeated lumbar punctions to control ICP should be abandoned due to questionable results and infectious risks (11).

For patients with raised ICP due to severe transverse sinus stenosis, angioplasty and venous stenting across the stenosis, under general anesthesia, may improve CSF resorption, decrease and even cure IIH symptoms as well as papilloedema (28, 38, 45, 46).

Surgical treatment of IIH (1-3, 43) is recommended if: medical therapy proves unsuccessful or is not tolerated, vision deteriorate; as in our case. In the absence of randomized controlled trials, surgical treatment include: shunting - lombo-peritoneal or ventriculo-peritoneal with ventricular catheter inserted stereotactically preferably with a variable pressure valve (42,

47-51), optic nerve sheath decompression and fenestration (52, 53), gastric bypass surgery for obese patients (5). IIH may resolve after initial treatment, may go into spontaneous remission (although it can still relapse at a later stage) or may continue chronically (5, 35).

Conclusion

IHH is rare, variable in evolution, and in many cases it disappears on its own within 6 months without affecting life expectancy (2). Weight loss, fluid or salt restriction, in conjunction with medical treatment, angioplasty and venous stenting across the sinus stenosis under general anesthesia and surgical treatment (shunting, optic nerve sheath decompression and fenestration, gastric by-pass surgery) are treatment alternatives. Therefore a long term follow up of these patients is essential to improve the prognosis, because 10 to 25% of cases (5, 23) could be affected by recurrences or by permanent vision loss to those patients with resistant papilledema despite treatment.

References

1. Bandyopadhyay S - "Pseudotumor cerebri". Archives of Neurology, 2001, 58 (10), 1699-701
2. Gans M.S. - Idiopathic Intracranial Hypertension, emedicine, medscape, overview, 2014, 02.05
3. Digre K.B., Corbett J.J. - "Idiopathic intracranial hypertension (pseudotumor cerebri): A reappraisal", Neurologist 2001, 7, 2-67
4. Farb R.I., Vanek I., et al. - Idiopathic intracranial hypertension: The prevalence and morphology of sinovenous stenosis, Neurology. 2003, 60, 1418-1424
5. Binder D.K., Horton J.C., et al. - "Idiopathic intracranial hypertension", Neurosurgery 2004, 54 (3), 538-51; discussion 551-552
6. Jencean S.M., Ciurea A.V. - Intracranial hypertension:

- classification and patterns of evolution, *J. Med Life* 2008, 15, 1(2), 101-107
7. Dhellemmes P., Defoort S., Vinchon M. - Hypertension intracrânienne bénigne: place du traitement médical, *Neurochirurgie* 2008, 54, 717-720
8. Klein O. - Hypertension intracrânienne bénigne - pseudotumore cérébri préambule, *Neurochirurgie* 2008, 54, 703
9. Lesler A., Fattal-Valevski A. - Idiopathic intracranial hypertension in the pediatric population, *J. Child Neurol* 2002, 17, 745-758
10. Pearce J.M. - From pseudotumore cérébri to idiopathic intracranial hypertension, *Pract. Neurol.* 2009, 9, 353-356
11. Wall M. - Idiopathic Intracranial Hypertension, *Neurol Clin*, 2010, 28(3), 593-617
12. George D. - Idiopathic intracranial hypertension. A prospective study of 50 patients, *Brain* 1991, 114, 155-180
13. Jencean, S.M. - Idiopathic intracranial hypertension and idiopathic normal pressure hydrocephalus: diseases with opposite pathogenesis?, *Medical Hypotheses* 2003, 61, 5-6, 526-528
14. Radhakrishnan K, Ashlskog F, et al. - Idiopathic intracranial hypertension: subject review, *Mayo Clin Proc* 1994, 69, 169-180
15. Soler D, Cox T, et al. - "Diagnosis and management of benign intracranial hypertension". *Archives of Disease in Childhood* 1998, 78 (1), 89-94
16. Johnston I. - "The historical development of the pseudotumor concept". *Neurosurgical Focus* 2001, 11 (2), 1
17. Mihorat T.H.. - Classification of the cerebral edemas with reference to hydrocephalus and pseudotumore cérébri, *Childs Nerv Syst.* 1992, 8, 301-306
18. Quincke H.I. - "Meningitis serosa", *Sammlung Klinischer Vorträge* 1893, 67, 655
19. Nonne M. - "Über Falle vom Symptom komplex "Tumor Cerebri" mit Ausgang in Heilung (Pseudotumor Cerebri)", *Deutsche Zeitschrift für Nervenheilkunde* 1904, 27, (3-4), 169-216
20. Dandy W.E. - "Intracranial pressure without brain tumor - diagnosis and treatment", *Annals of Surgery* 1937, 106 (4), 492-513
21. Symonds C.P. - "Otitic hydrocephalus", *Brain* 1931, 54 (3705), 55-71
22. Horton JC, Lawton MT, McDermott MW - "Idiopathic intracranial hypertension", *Neurosurgery* 2004, 54 (3), 538-51; discussion 551-2
23. Acheson JF - "Idiopathic intracranial hypertension and visual function", *British Medical Bulletin* 2006, 79-80 (1), 233-44
24. Jencean S.M. - Idiopathic intracranial hypertension. Review and hypothesis of the pathogenesis, *Res J Med and Medical Sciences*, 2006, 1, 104-108
25. Cognard C, Casasco A, et al. - Dural arterio-venous fistulas as a cause of intracranial hypertension due to impairment of cranial venous outflow, *J Neurol. Neurosurg. Psychiatry* 1998, 65, 308-316
26. Bloomfield G.L, Ridings P.C, et al. - A proposed relationship between raised intra-abdominal, intrathoracic, and intracranial pressure, *Crit Care Med* 1997, 25, 496-503
27. Binder DK, Horton JC, et al. - "Idiopathic intracranial hypertension", *Neurosurgery* 2004, 54 (3), 538-551, discussion 551-552
28. Ahmed R.M., Wilkinson M., et al. - "Transverse sinus stenting for idiopathic intracranial hypertension: a review of 52 patients and of model predictions", *American Journal of Neuroradiology* 2011, 32 (8), 1408-14
29. Biousse V., Ameri A., Bousser M.G. - Isolated intracranial hypertension as the only sign of cerebral venous thrombosis, *Neurology* 1999, 53, 1537-1542
30. Stevens S.A., Stimpson J. - A model for idiopathic intracranial hypertension and associated pathological ICP wave-forms, *IEEE Trans Biomed Eng.* 2008, 55, 388-398
31. Corbett J.J., Digre K. - Idiopathic intracranial hypertension: an answer to, "the chicken or the egg?", *Neurology* 2002, 58, 5-6
32. King J.O, Mitchell P.J, et al. - Cerebral venography and manometry in idiopathic intracranial hypertension. *Neurology* 1995, 45, 2224-2228
33. Karahalios D.G, Rakate H.L, et al. - Elevated intracranial venous pressure as a universal mechanism in pseudotumore cérébri of varying etiologies, *Neurology* 1996, 46, 198-202
34. Smith JL - "Whence pseudotumore cérébri?", *Journal of Clinical Neuroophthalmology* 1985, 5 (1), 55-56
35. Friedman DI, Jacobson DM - "Diagnostic criteria for idiopathic intracranial hypertension", *Neurology* 2002, 59 (10), 1492-1495
36. Degnan A., Levy L. - Pseudotumore cérébri; brief review of clinical syndrome and imaging findings, *AJNR* 2011, 1-8
37. Sismanis A. - "Pulsatile tinnitus. A 15-year experience". *American Journal of Otolaryngology* 1998, 19 (4), 472-7
38. Bracard S., Schmitt E. et al. - Hypertension intracrânienne "bénigne": imagerie et thérapeutiques

- endovasculaires, Neurochirurgie 2008, 54, 6, 721-723
39. Klein O., Joud A., Marchal J.C. – Prise en charge de l'hypertension intracrânienne bénigne: analyse de la série nancéenne, Neurochirurgie 2008, 54, 710-713
40. Jirari M., Behr J. et al. – Aspects IRM de l'hypertension intracrânienne idiopathique, <http://pe.sfrnet.org/Data/ModuleConsultationPoster/pdf/2011>
41. Makri S., Abdellaoui W., et al. - "Hypertension intracrânienne idiopathique avec selle turcique vide : A propos de deux observations", RMNSCI.NET 2009, 4 <http://www.rmnscl.info/document.php?id=721>.
42. Peter P., Philip N., Singh Y. - Reversal of MRI findings following CSF drainage in idiopathic intracranial hypertension, *Neurol. India* 2012; 60, 267-268
43. Corbett J.J., Thompson H.S. - The rational management of idiopathic intracranial hypertension, *ArchNeurol* 1998, 46, 1049-1051
44. Johnson L.N., Krohel G.B., et al. - The role of weight loss and acetazolamine in the treatment of idiopathic intracranial hypertension, *Ophthalmology* 1998, 105, 2313-2317
45. Teleb M.S., Cziep M.E. et al. - "Idiopathic Intracranial Hypertension. A Systematic Analysis of Transverse Sinus Stenting", *Interventional neurology* 2013, 2 (3), 132-143
46. Rajpal S., Niemann D.B., Turk A.S. – Transverse venous sinus stent placement as treatment for benign intracranial hypertension in a young male: case report and review of the literature, *J. Neurosurg.* 2005, 102, 342-346
47. Curry W.T., Butler W.E, Barker F.G. - "Rapidly rising incidence of cerebrospinal fluid shunting procedures for idiopathic intracranial hypertension in the United States, 1988-2002", *Neurosurgery* 2005, 57 (1), 97-108; discussion 97-108
48. Yadav Y.R. Parihar V. Sinha M. - "Lumbar peritoneal shunt", *Neurology India*, 2010, 58 (2), 179-184
49. Garton H.J. – Cerebral fluid diversion procedures, *J Neuro Ophthalmol.* 2004, 24, 146-155
50. Rosenberg M.L, Corbett J.J., et al. – Cerebrospinal fluid diversion procedures in pseudotumor cerebri, *Neurology* 1993, 43, 1071-1072
51. Eggenberger E.R, Miller N.R, Vitale S. - Lumboperitoneal shunt for the treatment of pseudotumor cerebri, *Neurology* 1996, 46, 1524-1530
52. Keltner J.L. - Optic nerve sheath decompression. How does it work? Has its time come? *ArchOphthalmol* 1988, 106, 1365-1369
53. Maalouf T., George J.L. – Traitement chirurgical de l'hypertension intracrânienne bénigne: fenestration des gaines du nerf optique, *Neurochirurgie* 2008, 54, 714-716.