

## Spontaneous regression of lumbar herniated disc Case presentation

A. Chiriac, Giorgiana Ion\*, Z. Faiyad\*, I. Poata

“Grigore T. Popa” University of Medicine and Pharmacy, Iasi  
“Prof. Dr. N. Oblu” Clinic Emergency Hospital, Iasi

**Abstract:** Intervertebral disc herniation is a common disease that usually requires surgical intervention. However, in some cases, neurological symptoms may improve with conservative treatment. In this article, we present a case with spontaneous regression of extruded lumbar herniated disc correlated with clinical improvement and documented with follow up MRI studies.

**Key words:** intervertebral disc herniation, spontaneous regression

### Introduction

The intervertebral disc herniation of the lumbar spine is one of the most common muscle-skeletal diseases usually characterized by low back pain and nerve root radiculopathy. Even if it passes more than 60 years from the first reported surgery for lumbar disc herniation some aspects concerning the most effective treatment are still in discussion. Most of patients with extruded lumbar disc herniation require surgical intervention due to their clinical manifestation. Also, there are many reports of total clinical symptoms remission after conservative treatment and imagistic spontaneous regression of intervertebral disc herniation.

In this paper we present one case with spontaneous regression of extruded lumbar

herniated disc documented on follow up MRI studies, in which the clinical symptoms improved with time. A short review of literature and mechanisms, precipitating factors of spontaneous disc regression, and proper treatment are discussed.

### Case presentation

A 38-year-old man with a 6-months history of low back and right leg pain was admitted to our department on February 2014. The patient declares a history of intermittent low back pain over the previous 2 years. The neurological examination revealed a slight peripheral L5 radiculopathy and paresthesias predominantly at right big toe. Straight leg raising test was positive on the right side. The patient was able to walk normally, but presented difficulty walking on their toes. He declares a treatment

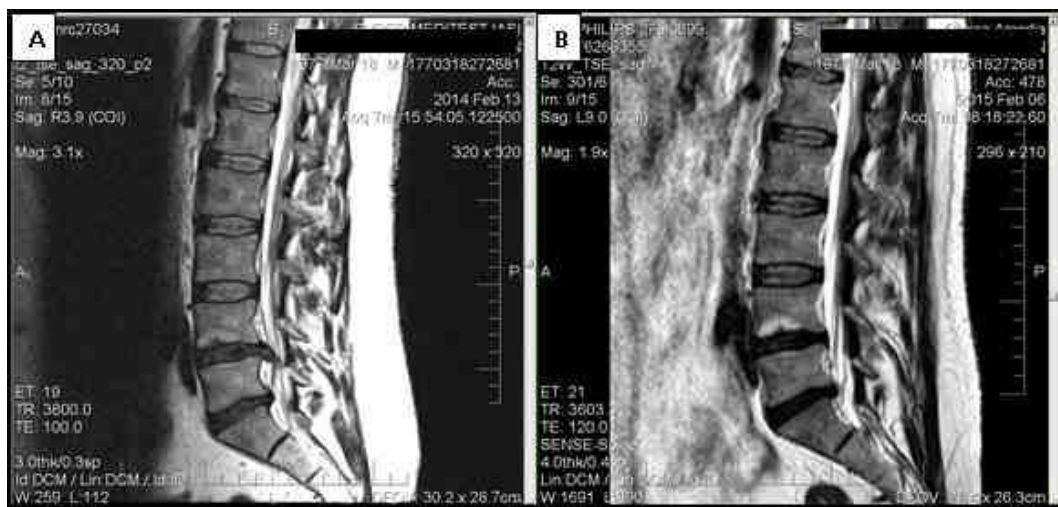
with anti-inflammatory and muscle relaxants medication.

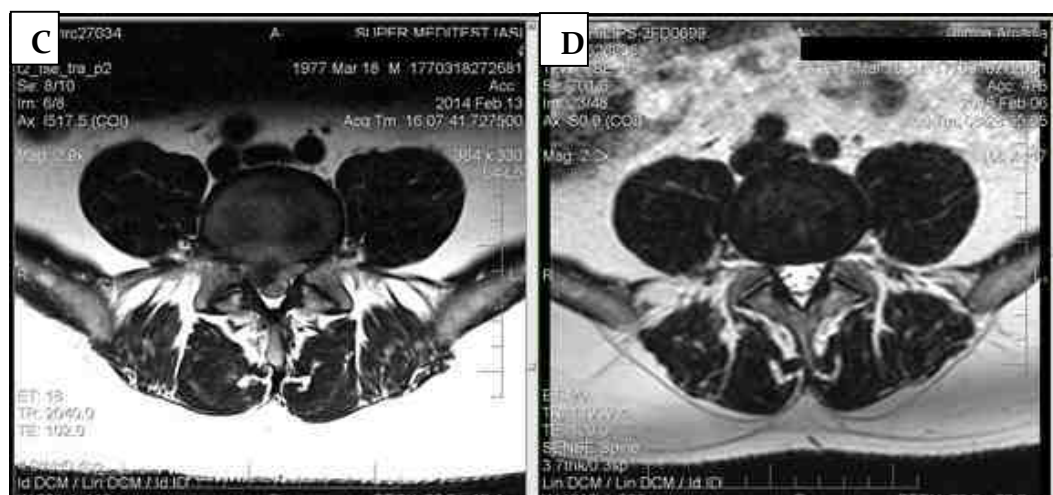
Magnetic resonance imaging (T2-weighted) of the lumbar spine performed shortly after his admission to our department had shown a large right-sided paracentral extruded disc fragment at the L4–L5 disk space, compressing the traversing L5 nerve root and the dural sac. The pathological MRI image found corresponds with the patient's clinical symptoms (Figure 1A, C).

Even if we had offered an operative treatment, the patient preferred to follow a conservative treatment that included physical and medical therapy with bed rest.

After the next six weeks at first clinical control, the patient no longer had leg pain or physical findings of nerve root tension. He did have residual left-sided grade 4 out of 5 weakness of his great toe extensor.

The patient came 12 months later to our outpatient clinic for follow-up lumbar spine MRI examination. This second magnetic resonance imaging study showed substantial regression of the extruded L4–L5 disc fragment without significantly reduction of height disc space compared to other levels (Figure 1B, D).





**Figure 1** - T2 weighted MRI sagittal and axial sequences showing A, C - L4/L5 herniated disc and B, D - spontaneous regression of L4/L5 herniated disc

## Discussions

The intervertebral disc disease is a very well documented disorder characterized by high work disability and healthcare costs. Although the first reported case of spontaneous regression of herniated intervertebral disc was published by Guinto et al in 1984, there still had remains particular aspects to be discussed. Regression of herniated discs has been described not only in the lumbar region but also in the thoracic and cervical spine, and for different clinical presentation as radiculopathy or myelopathy [11].

The exact mechanism causing the spontaneous disc regression remains an important discussion in the present literature. We identified three possible mechanism of spontaneous disc regression stated in literature.

The first mechanism assumes gradual dehydration and shrinkage of the herniated nucleus pulposus and its regression via tear in

the annulus. The second mechanism states that the herniated nucleus pulposus and annulus retracts back into the intervertebral space in the flexed position of bed rest. This situation is typical to protrude or bulge disc, not for the situation of completely extruded or separated disc material. The last hypothesis is based on enzymatic degradation and phagocytic cellular resorptive mechanisms. Thus, the exposure of the herniated material to the vascular environment of the epidural space favors the mechanisms triggering the above due to inflammatory reaction and neovascularization of disc herniation. The “vascular response” represented by local reaction around the disc fragment (proliferation of the blood vessels and migration of the phagocytosis of the disc material) plays an important role in disc resorption. Also, production of matrix proteinases and increased cytokine levels are very strong implicated in the spontaneous

regression process [1, 7]. Some histological studies have shown that sequestered discs are characterized by a faster resorption due to its higher potential of granulation tissue generation and heavier chronic inflammatory cell infiltration than other types of disc protrusion [1, 3, 7].

A number of studies have shown that MRI imaging may play a role as predictability factor of herniated disc regression. Thus, the presence of rim enhancement on Gd-enhanced MR around herniated mass showed a significant decreases or total disappearance in 75-100% of cases with herniated discs. Rim enhancement on MR images represents accumulation of contrast material within the hypervascularized granulation tissue surrounding the avascular herniated disc. The hyperintense signal on T2 MRI sequence around sequestered discs represents high water content of the material disc or edema due to neovascularization and inflammatory reaction [1, 2, 3, 7].

Usually, regression of the herniated disc coincided with the improvement of associated neurological symptoms.

## Conclusions

Spontaneous regression of herniated disc is not a common condition, but conservative treatment may be considered in patients without neurological deficits and highlighting MRI imaging signs suggestive for herniated disc regression. We considered that all three mechanisms described by literature for herniated disc regression may have been involved in this particular phenomenon.

## References

1. Kim, S. G., Yang, J. C., Kim, T. W., & Park, K. H. (2013). Spontaneous regression of extruded lumbar disc herniation: three cases report. *Korean Journal of Spine*, 10(2), 78-81;
2. Macki, M., Hernandez-Hermann, M., Bydon, M., Gokaslan, A., McGovern, K., & Bydon, A. (2014). Spontaneous regression of sequestered lumbar disc herniations: Literature review. *Clinical neurology and neurosurgery*, 120, 136-141;
3. Martínez-Quiñones, J. V., Aso-Escario, J., Consolini, F., & Arregui-Calvo, R. (2010) Spontaneous regression from intervertebral disc herniation. *Propos of a series of 37 cases, Neurocirugia (Asturias, Spain)*, 21(2), 108-117;
4. Monument J.Michael, Salo T. Paul (2011) Spontaneous regression of a lumbar disk herniation, *CMAJ*, April 19, 183(7):823;
5. Orief T, Orz Y, Attia W, Almusrea K: (2012) Spontaneous resorption of sequestered intervertebral disc herniation. *World Neurosurg* 77:146-152;
6. Parag Suresh Mahajan, Nawal M. Al Moosawi, and Islam Ali Hasan (2014) A Rare Case of Near Complete Regression of a Large Cervical Disc Herniation without Any Intervention Demonstrated on MRI," *Case Reports in Radiology*, vol. 2014, Article ID 832765, 4 pages;
7. Sabuncuoğlu, H., Ozdoğan, S., & Timurkaynak, E. (2008). Spontaneous regression of extruded lumbar disc herniation: report of two illustrative case and review of the literature. *Turkish neurosurgery*, 18(4), 392;
8. Slavin KV, Raja A, Thornton J, Wagner FC Jr: (2001) Spontaneous regression of a large lumbar disc herniation: report of an illustrative case. *Surg Neurol* 56:333-336;
9. Tarukado K, Ikuta K, Fukutoku Y, Tono O, Doi T. (2013) Spontaneous regression of posterior epidural migrated lumbar disc fragments: case series. *Spine J* 13:981-988;
10. Veli Çitişli, Muhammet İbrahimoglu (2015) Spontaneous Remission of a Big Subligamentous Extruded Disc Herniation: Case Report and Review of the Literature, *Korean J Spine*. Mar;12(1):19-21;
11. Chun-Wei Chang, Ping-Hong Lai, Chi-Man Yip, Shu-Shong Hsu (2009) Spontaneous Regression of Lumbar Herniated Disc, *Chin Med Assoc* , Vol 72, 12:650-3.