

Dumbell hydatid disease of spine with posterior paraspinal muscle involvement

Ranjeet Ramesh Jagadale¹, Kanicka Yashi², Umamaheswara Reddy V.³, Amit Agrawal⁴

¹Consultant Radiologist at Max Superspeciality hospital, Maharashtra, India

²Kasturba Medical College Hospital, Manipal, Karnataka, India

³Assistant Professor of Radiology, Department of Radiology, Narayana Medical College Hospital, Chinthareddypalem, Nellore, Andhra Pradesh, India

⁴Professor of Neurosurgery, Department of Neurosurgery, Narayana Medical College Hospital, Chinthareddypalem, Nellore, Andhra Pradesh, India

Abstract: Spinal hydatid disease is a rare form of hydatid disease caused by the larval form of *Echinococcus granulosus* (*E. granulosus*). Dogs are primarily the definitive hosts of *E. granulosus* with man and sheep serving as intermediate hosts. Spinal HD contributes to approximately 45 % of all skeletal hydatid disease cases. Spinal HD is perhaps the worst form of parasitic infestations associated with morbidity requiring surgical correction. Braithwaite and Lees have classified spinal hydatids into five types (1) intramedullary (2) intradural extramedullary (3) extradural intraspinal disease (4) vertebral hydatid (5) paravertebral hydatid. When hydatid disease from spinal canal extends into retroperitoneal space through the neural foramen, it gives dumbbell formation (similar to nerve sheath tumors). Symptoms of hydatid are mainly due to compressive effects of the cyst, low back pain accompanying motor weakness, sensory disturbances, bowel and bladder disturbances and cauda equina syndrome. Extensive vertebral hydatidosis can cause fractures of vertebrae. Serology tests are used in diagnosing suspected cases of hydatid disease. MRI with soft tissue detail is more preferable than other modalities in diagnosing spinal hydatid. Successful treatment of spinal hydatid disease necessitates adequate neuroimaging evaluation, careful surgical removal without spillage of cystic components and adding adjuvant chemotherapy in few cases is the mainstay of treatment. Sometimes when it is difficult to retrieve all the cysts in toto, debulking is advised.

Key words: Spinal Hydatid, dumbell Hydatid, echinococcosis.

Introduction

Spinal hydatid disease is a rare form of hydatid disease caused by the larval form of *Echinococcus granulosus* (*E. granulosus*). (1-4) Dogs are primarily the definitive hosts of *E. granulosus* with man and sheep serving as intermediate hosts. Hence, the disease is

prevalent in sheep-rearing communities. (1-4) Hydatid disease in man begins with ingestion of ova-contaminated water or food. The egg hatches in the intestines and the larvae migrate into the lungs and liver via the portal venous system. Hydatid commonly affects liver followed by lung, CNS and spine. Osseous hydatid accounts for approximately 0.5 - 4 %

of all cases. (4) Spinal HD contributes to approximately 45 % of all skeletal hydatid disease cases. (5) Thoracic region is commonly affected in hydatid disease followed by cervical and lumbar regions. (3, 5, 6) We report a case of dumbbell spinal HD of the lumbar region which had paraspinal cystic component and was effectively managed by laminectomy and facetectomy.

Case report

A 64-year-old diabetic man presented with complaints of painful swallowing for three days, epigastric pain radiating to back, abdominal pain accompanied by bilious vomitus and urinary retention. Abdomen was soft on palpation. However, there was severe tenderness in epigastric region and a palpable swelling was noticed in the back which was soft in consistency. Neurological assessment of the lower extremities revealed 4/5 power in bilateral lower limbs, bilateral +1 knee reflexes, areflexia of bilateral ankle joints and bilateral babinski sign positive. Additionally, sensory system was intact in both limbs and there were no cerebellar signs. Laboratory investigations revealed hyponatremia, raised erythrocyte sedimentation rate, leukocytosis and elevated amylase and lipase. Chest X-ray showed minimal left pleural effusion with basal consolidation. Abdominal USG showed bulky pancreas with increased echogenicity of the surrounding fat, no necrosis, no fluid collections and a retroperitoneal cystic lesion. Ultrasound of back lesion (Figure 1). Magnetic resonance imaging of the lumbar spine revealed hydatid disease of the retroperitoneum, spinal canal and paraspinal muscles and a diagnosis of acute pancreatitis, dumbbell hydatid cyst with paraspinal component was made (Figure 2 and 3). The patient was initially managed symptomatically with intravenous normal saline, oral nystatin drops and antibiotics. Besides, patient was catheterized to relieve urinary retention.

Posterior paraspinal exploration of the swelling with laminectomy and facetectomy was done and cysts were extracted carefully (Figure 4). The procedure was successful and a sample was taken for histopathology to confirm diagnosis (Figure 5). Post operative period was uneventful. Surgery for retroperitoneal component was planned on a later date. The patient was discharged on Mebendazole 1gram daily for 3 months. On follow up, patient showed improvement in power and reflexes of bilateral lower limbs.

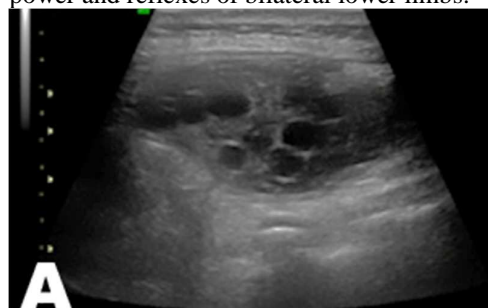

Figure 1 - Ultrasound image of paraspinal region showing numerous round cystic lesions (Daughter cysts)

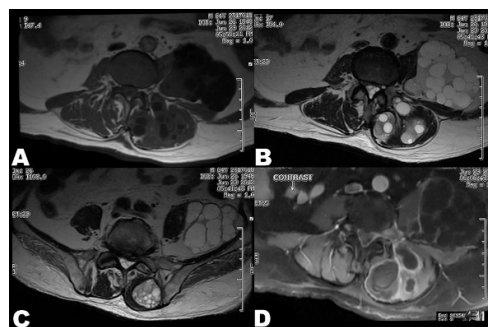


Figure 2 - Axial T1 and T2 (A,B,C) images showing daughter cysts in intradural space displacing the nerve roots which are seen to extend through neural foramina to paravertebral space. Numerous daughter cysts are also seen in the paraspinal muscles to the left. Axial T1W contrast image showing peripheral enhancement of the cysts and enhancement of adjacent muscles

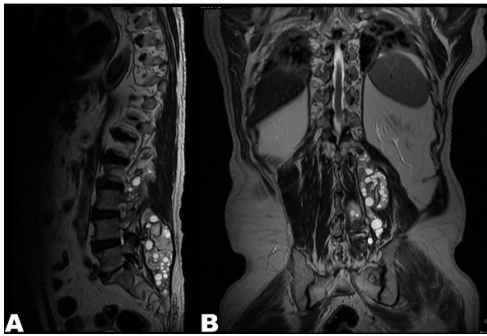


Figure 3 - Sagittal and coronal T2W weighted images showing crumpled membranes and daughter cysts

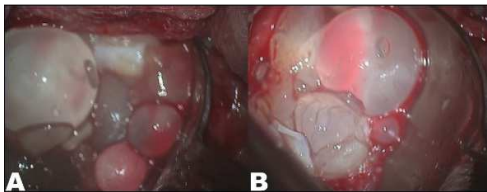


Figure 4 - Intraoperative picture showing removal of rounded glistening transparent daughter cysts

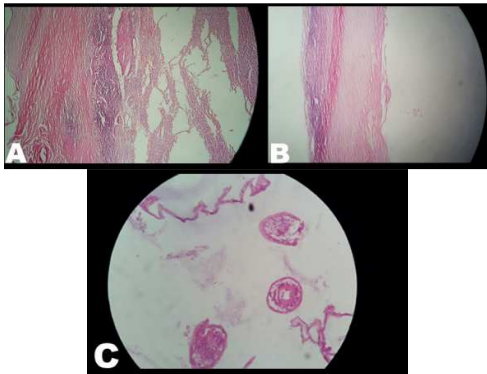


Figure 5 - Histopathology (A, B, C) showing cyst wall and multiple daughter cysts

Discussion

Spinal HD is perhaps the worst form of parasitic infestations associated with morbidity requiring surgical treatment. (5) Because of its aggressive nature it is compared with locally aggressive neoplasms and the mortality is approximately 50% after onset of

symptoms. (2, 4-6) Braithwaite and Lees have classified hydatids into five types (1) intramedullary (2) intradural extramedullary (3) extradural intraspinal disease (4) vertebral hydatid (5) paravertebral hydatid. When hydatid disease from spinal canal extends into retroperitoneal space through the neural foramen, it gives dumbbell configuration, (similar to nerve sheath tumors). (7) Symptoms of hydatid are mainly due to compressive effects of the cyst, low back pain accompanying motor weakness, sensory disturbances, bowel and bladder disturbances and caudaequina syndrome. (1, 2, 8-11) Extensive vertebral hydatidosis can cause fractures of vertebrae. (3, 4) Serology tests are used in diagnosing suspected cases of hydatid disease. Identifying antibody to echinococcal polypeptide antigen has the highest specificity. ELISA, complement fixation tests and indirect hemagglutination (IHA) are other specific tests for diagnosing hydatid disease with specificity ranging from 80% to 100%. (12) Imaging is more sensitive than serodiagnosis in spinal hydatid disease. To confirm ELISA and IHA immunoblotting (Antigen 5 precipitation: Arc-5) techniques can be used. However it is important to note sensitivity and specificity of this test for extrahepatic hydatid diseases is very low. Spinal hydatid can be evaluated by ultrasound, computed tomography and MRI, sometimes combination of all the modalities is required for achieving diagnosis and treatment. (2, 3, 6-8, 13) MRI with soft tissue detail is more preferable than other modalities in diagnosing spinal hydatid. When presented with paraspinal cystic component numerous differentials like epidermoid, teratoma, dermoid, cystic hamartoma (tail gut cyst), tarlov cyst and neurenteric cysts can be considered. (5) When hydatid is involving the bone along with other tissues, common differentials to be thought are chordoma and aneurysmal bone cyst. (5) Successful treatment of spinal hydatid disease necessitates adequate neuroimaging

evaluation, careful surgical removal without spillage of cystic components and adding adjuvant chemotherapy in few cases is the mainstay of treatment. (1, 3, 5, 6) Sometimes when it is difficult to retrieve all the cysts, in toto debulking is advised. However it is important to note that recurrences are high in case of spinal hydatids (40-50%). Follow up imaging should be performed frequently to detect the recurrences as early as possible. (1, 3, 5, 6)

Correspondence

Dr. Umamaheswara Reddy. V (MD)
Assistant Professor, Department of Radiology
Narayana Medical College Hospital
Chinthareddypalem.
Nellore-524003
Andhra Pradesh (India)
Email- mahesh.rd2112@gmail.com
Mobile- +91 9959632228

References

1. Emara KM, Abd Elhameed D. Hydatid disease of the lumbar spine: combined surgical and medical treatment—a case report. *Am J Orthop (Belle Mead NJ)* 2007;36:E12-14.
2. Joshi K, Jagannath A, Varma R. Dumbbell shaped spinal hydatidosis. *Neurology India* 2014;62:113.
3. Neumayr A, Tamarozzi F, Goblirsch S, Blum J, Brunetti E. Spinal cystic echinococcosis—a systematic analysis and review of the literature: part 2. Treatment,

follow-up and outcome. *PLoS neglected tropical diseases* 2013;7:e2458.

4. Prabhakar MM, Acharya AJ, Modi DR, Jadav B. Spinal hydatid disease: a case series. *The journal of spinal cord medicine* 2005;28:426.
5. Bhake A, Agrawal A. Hydatid disease of the spine. *Journal of neurosciences in rural practice* 2010;1:61.
6. Vujović R, Živković N, Stanić M. Spinal echinococcosis: Review of the literature. *Materia medica* 2012;28:777-779.
7. Braithwaite PA, Lees RF. Vertebral hydatid disease: radiological assessment. *Radiology* 1981;140:763-766.
8. Berk C, Ciftci E, Erdoğan A. MRI in primary intraspinal extradural hydatid disease: case report. *Neuroradiology* 1998;40:390-392.
9. Karadereler S, Orakdögen M, Kiliç K, Özdoğan C. Primary spinal extradural hydatid cyst in a child: case report and review of the literature. *European Spine Journal* 2002;11:500-503.
10. Karakasli A, Yilmaz M, Mucuoglu AO, Yurt A. A large primary dumbbell hydatid cyst causing neural foraminal widening of the thoracic spine: A case report and literature review. *International Journal of Surgery Case Reports* 2015.
11. Tekkök IH, Benli K. Primary spinal extradural hydatid disease: report of a case with magnetic resonance characteristics and pathological correlation. *Neurosurgery* 1993;33:320-323.
12. Babba H, Messedi A, Masmoudi S, et al. Diagnosis of human hydatidosis: comparison between imagery and six serologic techniques. *The American journal of tropical medicine and hygiene* 1994;50:64-68.
13. Doganay S, Kantarci M. Role of conventional and diffusion-weighted magnetic resonance imaging of spinal treatment protocol for hydatid disease. *The journal of spinal cord medicine* 2009;32:574.