

## Intraventricular entrapment of shunt catheter causing shunt malfunction

Amit Agrawal<sup>1</sup>, Umamaheswara Reddy V.<sup>2</sup>, Yashwant Sandeep<sup>3</sup>

<sup>1</sup>Professor of Neurosurgery, Department of Neurosurgery, Narayana Medical College Hospital, Chinthareddypalem, Nellore, Andhra Pradesh (India)

<sup>2</sup>Assistant Professor of Radiology, Department of Radiology, Narayana Medical College Hospital, Chinthareddypalem, Nellore, Andhra Pradesh (India)

<sup>3</sup>Resident of Neurosurgery, Department of Neurosurgery, Narayana Medical College Hospital, Chinthareddypalem, Nellore, Andhra Pradesh (India)

**Abstract:** Intraventricular septations can lead to compartmentalization of the ventricles that can result in “complex or loculated hydrocephalus”. We report a case of 7 year old female child who underwent multiple shunt revisions where there was intraventricular entrapment of shunt catheter leading to obstruction of the shunt and malfunction. In present case we placed the ventricular catheter in contra-lateral ventricle with good clinical outcome. With the recent advancements endoscopic guided removal of the old malfunctioning ventricular catheters is considered the safest option.

**Key words:** Shunt malfunction, mechanical failure, loculation, entrapment

### Introduction

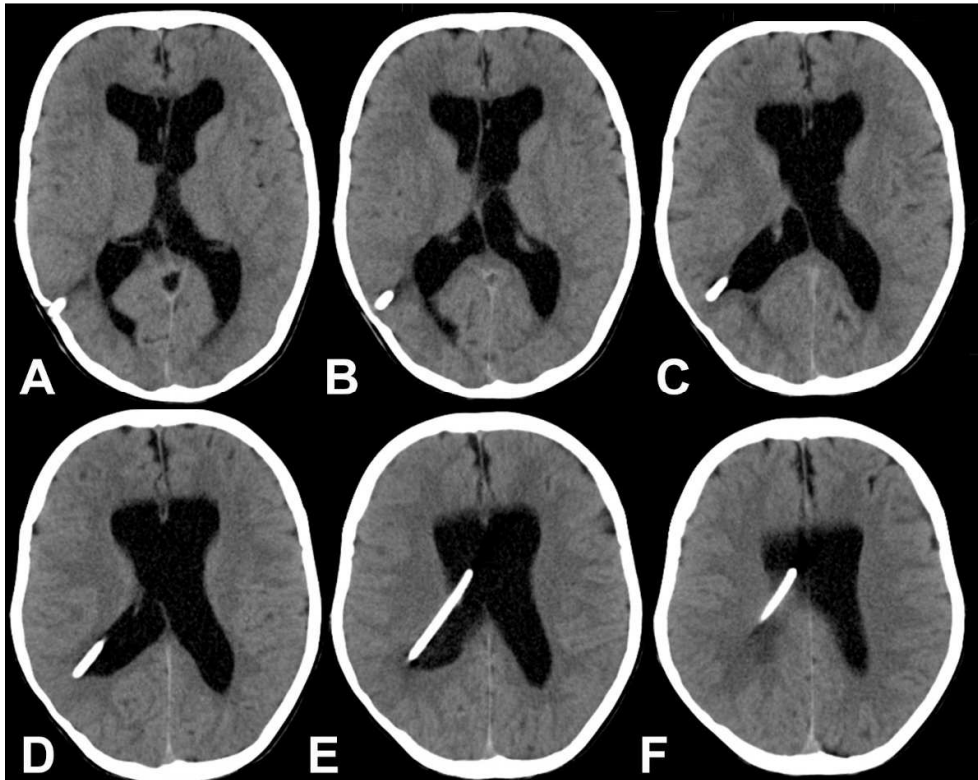
Many complications can be associated with VP shunt procedures requiring multiple shunt revisions during lifetime. (1-3) Out of many, mechanical failure (obstruction either proximal or distal and displacement) and shunt infection are most commonly encountered problems. (3-6) We report a case of female child where intraventricular entrapment and subsequent obstruction lead to the malfunctioning of the shunt and worsening in contra lateral hydrocephalus.

### Case report

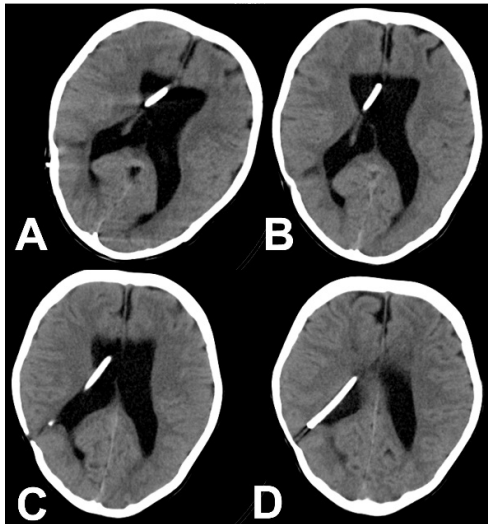A 7 year old female child underwent right ventriculo-peritoneal shunt for congenital hydrocephalus (presented with increase in head size at that time) at the age six months. She presented with headache associated with vomiting and medial deviation of eye balls.

There was no history of fever, seizures or abnormal posturing. On examination the child was dull and apathetic. She was opening eyes to call, obeying command and moving all four limbs. She had bilateral rectus palsy with medial deviation of both eyes. Motor and sensory examination was normal. On pressing the shunt chamber it was not filling well. She had similar episode one month back and a shunt revision was performed (Figure 1, A-F). During surgery lower end of the catheter was retrieved from the peritoneal cavity and there was a good flow of CSF. It was suspected that the obstruction was distal and the abdominal end of the catheter was placed in fresh position. A repeat CT scan was performed and it showed asymmetrical dilation of the ventricles (left more than right) and shunt tube was trapped in the right lateral ventricle probably causing functional ventricular shunt catheter obstruction responsible for features of shunt malfunction. Her blood investigations

and CSF analysis were normal. Following the fresh revision the child is doing well at follow up.



**Figure 1** - Plain axial CT images of brain (A-F) showing ventriculoperitoneal shunt inserted through parietal burr hole and inserted into the frontal horn. There is persistence of hydrocephalus, close observation revealed adhesions in the midportion of right ventricle causing entrapment of shunt resulting in improper drainage



**Figure 2** - Repeat plain CT of the brain (A-D) showing no significant reduction in the hydrocephalus, however notice the asymmetry or upper portion the right lateral ventricle due to preferential drainage

## Discussion

Intraventricular septations can lead to compartmentalization of the ventricles leading to a challenging neurosurgical problem called “complex or loculated hydrocephalus”. (7, 8) Although silicone catheter is supposed to be chemically inert and should not provoke inflammatory reactions. However, these silicone made catheters may contain many impurities and when it comes in contact with CSF (which can also contain cells or blood) or tissue (chorioids plexus, ventricular ependyma or debris) there may be an inflammatory response leading to gliosis and blockage of shunt catheter. (9-11) Apart from that the intraventricular inflammatory response may lead to septations, these can alter the ventricular anatomy and normal CSF flow leading to loculated accumulation of CSF with progressive and asymmetric dilatation of the ventricles and mass effect. (12) Patients with shunt malfunction present with features of raised intracranial pressure (headache,

vomiting, deviations of the eye balls suggestive of sixth nerve paresis). On local examination where shunt malfunctions is suspected due to the blockage of the ventricular catheter, on pumping of the shunt chamber it is slow to refill, or may not refill at all. Plain CT scan of the brain is the initial investigation of choice in suspected cases of shunt malfunction. (12) It will show the disproportionately dilated ventricular system and position of the ventricular catheter. (12) However for the delineation of the intraventricular septations MRI (with gadolinium) of the brain is a superior modality of imaging. (12) Neurosurgical intervention is aimed to convert multiple compartments into a single communicating cavity and neuroendoscopic procedures can best achieve this goal. (7, 8, 13, 14) With the recent advancements endoscopic guided removal of the old malfunctioning ventricular catheters is considered the safest option as the scarred or adherent tissue can be easily separated and the catheter can be withdrawn safely without risk of intraventricular hemorrhage. (15)

## Correspondence

*Dr. Amit Agrawal*  
*Professor of Neurosurgery*  
*Department of Neurosurgery*  
*Narayana Medical College Hospital*  
*Chinthareddy palem*  
*Nellore-524003*  
*Andhra Pradesh (India)*  
*Email- dramitagrawal@gmail.com*  
*dramit\_in@yahoo.com*  
*Mobile- +91-8096410032*

## References

- 1.Chiriac A, Poata I, Iliescu B. Mechanical failures of ventriculo-peritoneal shunts. Romanian Neurosurgery 2012; XIX:226 - 229.
- 2.Agrawal A, Rao GM. Subcutaneous shunt catheter calcification: An uncommon cause of shunt failure. Saudi Journal of Medicine and Medical Sciences 2014;2.
- 3.Dickerman RD, McConathy WJ, Morgan J, et al. Failure rate of frontal versus parietal approaches for proximal catheter placement in ventriculoperitoneal

- shunts: revisited. *Journal of clinical neuroscience* 2005;12:781-783.
4. Di Rocco C, Marchese E, Velardi F. A survey of the first complication of newly implanted CSF shunt devices for the treatment of nontumoral hydrocephalus. *Child's Nervous System* 1994;10:321-327.
5. Ventureyra EC, Higgins MJ. A new ventricular catheter for the prevention and treatment of proximal obstruction in cerebrospinal fluid shunts. *Neurosurgery* 1994;34:924-926.
6. Satow T, Saiki M, Kikuchi T. *Complications Associated with Surgical Treatment of Hydrocephalus*: INTECH Open Access Publisher, 2012.
7. Ross DA, Muraszko K, Dauser R. A special cyst puncture catheter for use in thick-walled or mobile intracranial cysts. *Neurosurgery* 1994;34:191-192.
8. Schultz P, Leeds NE. Intraventricular septations complicating neonatal meningitis. *Journal of neurosurgery* 1973;38:620-626.
9. Ivan LP, Choo SH, Ventureyra EC. Complications of ventriculoatrial and ventriculoperitoneal shunts in a new children's hospital. *Canadian journal of surgery* 1980;23:566-568.
10. McLaurin RL. *Ventricular shunts: complications and results*. Pediatric neurosurgery Saunders, Philadelphia 1989;219.
11. Kalsbeck JE, DeSousa AL, Kleiman MB, Goodman JM, Franken EA. Compartmentalization of the cerebral ventricles as a sequela of neonatal meningitis. *Journal of neurosurgery* 1980;52:547-552.
12. Nida TY, Haines SJ. Multiloculated hydrocephalus: craniotomy and fenestration of intraventricular septations. *Journal of neurosurgery* 1993;78:70-76.
13. Oi S, Abbott R. Loculated ventricles and isolated compartments in hydrocephalus: their pathophysiology and the efficacy of neuroendoscopic surgery. *Neurosurgery clinics of North America* 2004;15:77-87.
14. Browd SR, Gottfried ON, Ragel BT, Kestle JRW. Failure of cerebrospinal fluid shunts: part II: overdrainage, loculation, and abdominal complications. *Pediatric neurology* 2006;34:171-176.
15. Leszek H, Regina S, Józef R, Aleksandra H, Leszek S. Fluoroscopy Neuro-Guided Endoscopic Removal of a Lost Ventricular Catheter in Hydrocephalic Girl with Staphylococcal Shunt Infection. *Open Journal of Modern Neurosurgery* 2012;2012.