

Long segment composite split cord malformation with double bony spur

Anand Sharma, Achal Sharma, R.S. Mittal

SMS Medical College, Jaipur, India

Abstract: A composite type of SCM is very rare and only a few cases have been reported until today. The frequency of composite- type SCM is lower than 1% in the literature. In this report, we presented an unusual case of long segment composite type split cord malformation with double level bony spur with multiple associated bony anomalies.

Key words: composite split cord malformation, double bony spur

Introduction

Split cord malformations (SCM) are rare, congenital spinal anomalies involving splitting of the cord. Here, a segment or whole of the spinal cord is divided into two parts by a rigid or a fibrous septum. These are usually diagnosed in children, up to 20% may be present in adulthood (6). Scoliosis and skin lesions are the main physical findings in patients with SCMs. Composite type SCM is very rare and results from two separate foci of ectoendodermal adhesions and endomesenchymal tracts (7) leading to development of different SCM types with intervening normal cord in the same patient (4). Only a few cases of composite type SCM have been reported in literature. In this report, we presented an unusual case of long segment composite type split cord malformation with double level bony spur and multiple associated bony anomalies.

Case Report

A 4-year girl with hypertrichosis over lower back since birth came to our institute. There is no history of delayed milestone, fever and bladder and bowel involvement. On physical examination, excessive hairs were present at lower lumbar region without other cutaneous stigmata. Muscle tone and power was normal bilaterally in the lower limbs. Deep tendon reflexes and uroflometry were also normal. NCCT scan shows evidence of two large bony spurs located at D6 and L2 vertebral levels with multiple fused vertebrae at D7, D8, and D9 with spina bifida at L1. (Figures 1, 3A, 3B, and 3C). MR imaging revealed two bony septum at D6 and L2 with fibrous band at D7 with long segment of split cord without intervening normal single cord extending from D5 vertebral body level to L3 and the conus medullaris at L4. (Figures 2, 3D, 3E)

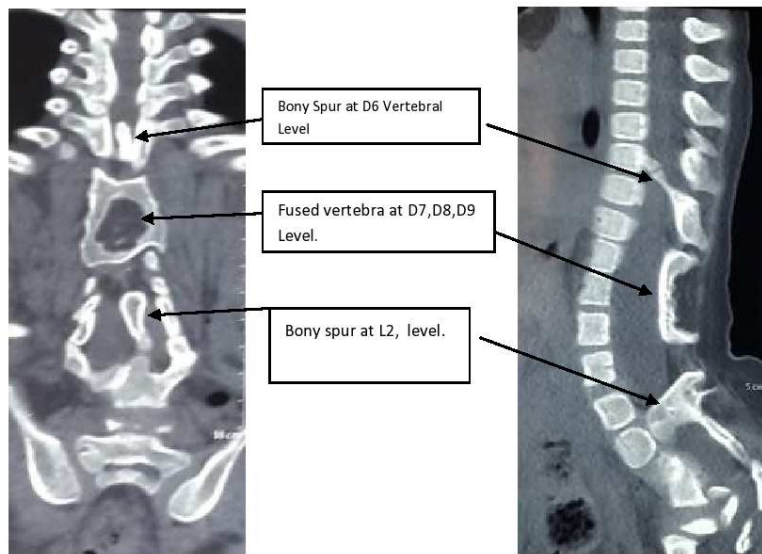


Figure 1 – Coronal and sagittal CT whole spine

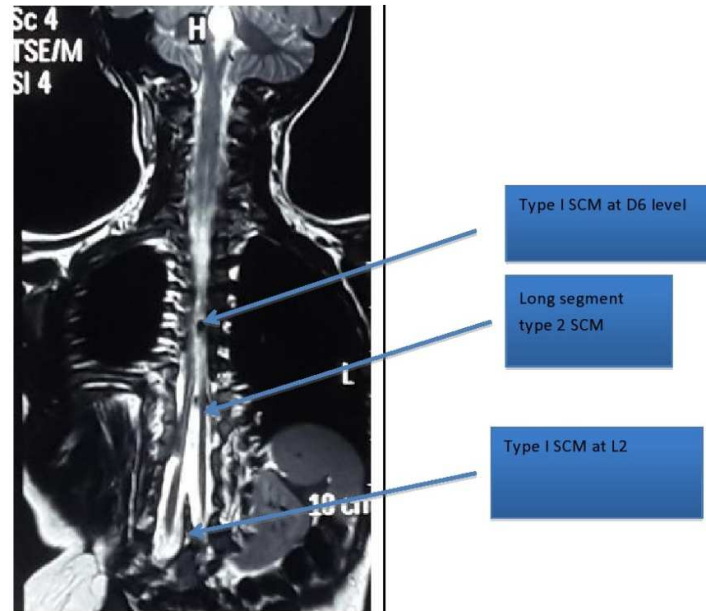


Figure 2 – MRI Spine coronal sections showing long segment splitting of cord extending from D5 vertebral level to L4 vertebral level with double bony spurs

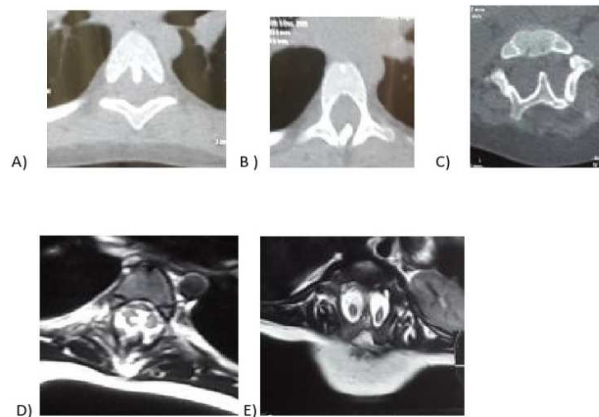


Figure 3 – CT scan **A, B** – axial images at D6 level showing bony spur. **C** – axial images showing another located bony spur at L2 level. **D, E** – MRI T2 axial images at D6 (**A**) and L2 (**E**) level

Management

Surgery was performed to prevent the progress of the neurologic damage resulting from tethering of the conus. The patient underwent laminectomies at D5–7, and L2, L3, L4 to remove the splitting lesions. Specifically, two spinal cords with their own dural sheaths were noted at D-5 and L2 and two hemicords in single dural sac were observed at D7. We resected bony spurs and fibrous band, reconstruction of dural sac done with the released of conusmedullaris by cutting the terminal filum via a L-4 laminectomy. Postoperatively patient develop CSF leak from operative site, which were managed by reexploration and repair of dural defect with fibrin glue.

Discussion

SCMs are rare congenital malformations of the spinal cord and its covering that were first described by Ollivier (5) in 1837 and which he termed diastematomyelia. He used this term to describe an abnormality of the spinal cord in which the dura is separated by a bone spur or rigid fibrous bands to create 2 sleeves, each containing a portion of spinal cord divided sagittally into 2 parts. Bruce et al (1) used the term “diastematomyelia” to describe a spinal

cord split by a midline bony spur, and reserved the term “diplomylelia” for a true doubling of the spinal cord without a spur. Pang (8) in 1992 gave a new classification recommending the term “SCM” for all double spinal cord malformations. In type I the hemi cords are always invested with individual dural sacs and the medial walls of the sacs always ensheath a rigid (bony or cartilaginous) midline spur, whereas in type II the hemi- cords are always within a single dural sac and the midline septum is always composed of nonrigid fibrous or fibro-vascular tissues. A composite type of SCM is very rare and only a few cases have been reported. The frequency of composite- type SCM is lower than 1% in the literature (3). The most constituents of composite SCM are a type 1-type 2-type 1 combination (9). Pang et al (6, 7) proposed a unified theory to explain the embryogenetic mechanisms of all variants of SCMs. According to the theory, the formation of an “accessory neurenteric canal” between the yolk sac and amnion through the midline embryonic disc was the main cause of the defects. This canal gets subsequently invested with the mesenchyme to form an endomesenchymal tract, which causes the splitting between the notochord and neural

plate. The accessory neurenteric canal is the key point of this malformation. This canal may be alone, or multiple canals may occur. The presence of multiple accessory neurenteric canals results in two or more septa that divide the spinal cord into two hemi-cords. According to this theory, one or more types of SCM may develop in patients at many different levels. Pang (6) reported on 2 cases of composite-type SCM among 39, and Erşahin et al. (2) reported on 4 cases of this type among 74 patients.

Our case represent unusual variant of SCM comprising of composite split cord malformation with two level bony spur. Another important finding were long segment of split cord (D5 to L4), usually the two hemi cords reunite caudally to the split, but in our case the split did not reunite and represents the true duplication of the spinal cord, So it has three elements two bony spur at ends and one fibrous band with long segment of split cord malformation. These three elements are continuous, suggesting that entire lesion results from a single (but very large) endomesenchymal tract in which meninx primitive precursor cells have been included at both ends to cause type 1 lesion, but not in midline where medial septa remain fibrous (9).

MR imaging is the diagnostic modality of choice for such lesions and imaging of the whole spine is essential to rule out other associated anomalies. CT scan is complimentary to MRI and is helpful in evaluating the nature of the spur and associated vertebral body anomalies. The location of the bony spur was thoracic and lumbar in our case.

Surgery is the treatment of choice wherein the bony spur should be excised microsurgically. Low-lying conus should also be addressed along with the excision of bony spur and dural sac reconstruction. Exploration and excision of the bony spur was followed by filum detethering in the same

stage using standard microneurosurgical principles.

Conclusion

Composite SCMs are uncommon, complex conditions of spinal dysraphism. Etiology and pathogenesis is not clearly defined. The clinical radiological findings in our patient could not be explained by multiple accessory neurenteric canal theory. Physical and neurological signs of SCM in a patient should prompt the neurosurgeon to consider performing the screening MRI of whole spine with brain to rule out other composite type SCM and associated anomaly.

Correspondence

Dr. Anand Sharma

Mch Neurosurgery

Associate consultant, Neurosurgery

Artemis health sciences, Gurgaon, 122003(India),

Ph: +91-9873190047

Email: dranandsharma100123@gmail.com

References

1. Bruce A, M'Donald S, Pirie JH. A second case of partial doubling of the spinal cord. *Rev Neurol Psychiatry*. 1906;4:6-19.
2. Erşahin Y, Mutluer S, Kocaman S, Demirtas E: Split spinal cord malformations in children. *J Neurosurg* 1998; 88: 57-65.
3. Harwood-Nash DC, McHugh K: Diastematomyelia in 172 children: the impact of modern neuroradiology. *Pediatr Neurosurg* 1990; 16: 247-251.
4. Khandelwal A, Tandon V, Mahapatra AK: An unusual case of 4 level spinal dysraphism: Multiple composite type 1 and type 2 split cord malformation, dorsal myelocystocele and hydrocephalous. *J Pediatr Neurosci*. 2011;6:58-61.
5. Ollivier C: *Traité des maladies de la moelle épinière*. Paris, Mequignon-Marvis, 1837.
6. Pang D, Dias MS, Ahab-Barmada M: Split cord malformation. I. A unified theory of embryogenesis for double spinal cord malformations. *Neurosurgery* 1992; 31:451-80.
7. Pang D: Split cord malformation: Part II: Clinical syndrome. *Neurosurgery*. 1992;31:481-500.
8. Pang D. Split cord malformation, Proposal for a New Clinicoradiological. *Neurosurg Clin N Am*. 1995;3:339-52.

9.Schmidek & sweet operative Neurosurgical techniques.
ELSEVIER SAUNDERS 2012,727-728.