

Pedicle screw fixation for low lumbar burst fracture with grade 4 retrolisthesis without any neurological deficit

Rahul Pramod Patil¹, Gaurav Jaiswal², Tarun Kumar Gupta³

Department of Neurosurgery, R.N.T. Medical College, Udaipur, Rajasthan, India

¹Resident M.Ch Neurosurgery; ²Neurosurgery, Asst. Prof. Dept. of Neurosurgery

³Neurosurgery, Prof. and Head Dept. of Neurosurgery

Abstract: Burst fractures of the spine account for 14% of all spinal injuries. Lower lumbar burst fracture with retrolisthesis is a rare presentation of traumatic cause. Management of this type of fracture are controversial and depends on plenty of factors like age of patient, type of injury, neurological deficit, associated comorbid injury. Here we are discussing a rarest case of traumatic burst fracture of L4 vertebrae with grade 4 retrolisthesis of L4 on L5 vertebrae with severe secondary canal stenosis and neurologically intact, which was managed with pedicle screw fixation.

Key words: Low lumbar burst fracture, pedicle screw fixation, retrolisthesis.

Introduction

Each year, there are approximately 5 million new vertebral fractures worldwide¹. Burst fractures of the spine account for 14% of all spinal injuries (11). Most common site is thoraco-lumbar spine followed by cervical spine (11). Burst fractures of the low lumbar (L4 and L5) spine represent a small percentage of all spine injuries. The ilio-lumbar ligaments, major muscle support and location in the pelvic brim and size of lumbar canal are main features unique to these fractures compared to those that occur at the thoraco-lumbar region (12). The rarity of these injuries is evident from their limited discussion in the literature. Treatment must be individualised and the recommendations for thoraco-lumbar trauma management cannot necessarily be transferred to low lumbar fractures. Management of this type of fracture are controversial and depends on plenty of factors like age of patient, type of injury, neurological deficit, associated comorbid injury. Here we

are discussing a rarest case of traumatic burst fracture of L4 vertebrae with grade 4 retrolisthesis of L4 on L5 vertebrae with severe secondary canal stenosis but neurologically intact, which was managed with pedicle screw fixation.

Case

35 year old male fell from tree and had severe back pain on admission to hospital. On examination power in both lower limbs was Grade V, without sensory deficit, without bladder and bowel involvement and deep tendon reflexes were normal. Local tenderness of lower lumbar spine was present. CT scan of lumbo-sacral spine showed burst fracture of L4 vertebra with retrolisthesis of L4 on L5 (Figure 1). MRI of lumbo-sacral spine showed burst fracture of L4 vertebra with retropulsion of fracture fragments into the bony spinal canal causing compression on ventral aspect of thecal sac and impingement on nerve root of filum terminale with obliteration of spinal canal with grade IV retrolisthesis of L4 over

L5 vertebra with mild diffuse disc bulge at L3-4 and L5-S1 (Figure 2). We had perform bilateral pedicle screw fixation at L3 and L5 with rod fixation with decompressive laminectomy via posterior approach (Figure 3). To avoid canal compromise and development of iatrogenic cauda equina syndrome due to posterior migration of fracture fragments we had perform decompressive laminectomy. Patient was mobilise with brace on postoperative day 3. Post-operatively power in both lower limbs was 4+/5 and did not develop radiculopathy or cauda equina syndrome.

Discussion

Burst fracture of the lumbar spine is defined as a failure of at least the anterior and middle columns of a vertebral segment because of axial compression, usually associated with some flexion (2). Burst fracture are offer associated with some degree of kyphotic deformity of lumbar spine with or without retrolisthesis.

Low lumbar burst fracture are rare spine injuries. They differ significantly from thoraco-lumbar fracture and their treatment must be individualised. The content and size of the neural canal distinguish the low lumbar area from other region of spine. The cauda equine, containing the nerve roots occupies the lumbar spinal canal below L2 vertebra. So any anatomical distortion due to injury at or below this level stimulates peripheral nerve injury with potential for spontaneous recovery unlike injury above this level which affects the conus medullaris or the spinal cord. Additionally, the dimensions of the spinal canal are greater here than in any other region and, indeed, there have been several reports of decreases of as much as 90% in the cross-sectional area of the spinal canal without a neurological deficit especially at L4-L5. These features help to explain the infrequency of severe neurological deficits and the potential neurological recovery when such a fracture is present (8).

Treatments for low lumbar burst fractures are conservative or surgical, either posterior or by applying an anterior approach (1, 9). But, there is no strict guideline or consensus regarding the proper approach for such lesion. Injury pattern, neurological status, age of patient, associated comorbid injury and anatomical approaches available should all be taken into consideration while deciding the line of management. In the neurologically intact patients, conservative care including initial bed rest with postural reduction, subsequent wearing of brace and ambulation has been an effective treatments for low lumbar burst fractures (3, 6).

Kostuik et al, suggested surgical stabilization is required in burst fracture of thoraco-lumbar and low lumbar region without neurological deficit, when there is canal compromise of more than 50% or there is local kyphosis (5).

Yazar et al, also share the same opinion, that anterior decompression and stabilization should be performed for low lumbar burst fractures in case of more than 70% of canal compromise due to risk of future displacement, even though there were no neurologic deficits (13).

Finn et al, reported no correlation of the degree of neurologic deficits with the amount of canal compromise at time of injury. He also said that there is no progression of posterior displacement of bone fragments in low lumbar burst fractures and no significant kyphosis with brace treatment (4).

Our patient had burst fracture of L4 vertebra with retrolisthesis of L4 over L5 causing more than 90% of canal compromises, but neurologically intact. We had performed pedicle screw fixation via a posterior approach as patient was neurologically intact. Such surgery helps in immediate pain relief, elimination of donor site pain, reducing blood loss and short operative time, early mobilisation. There was no post-operative complication like displacement of bone

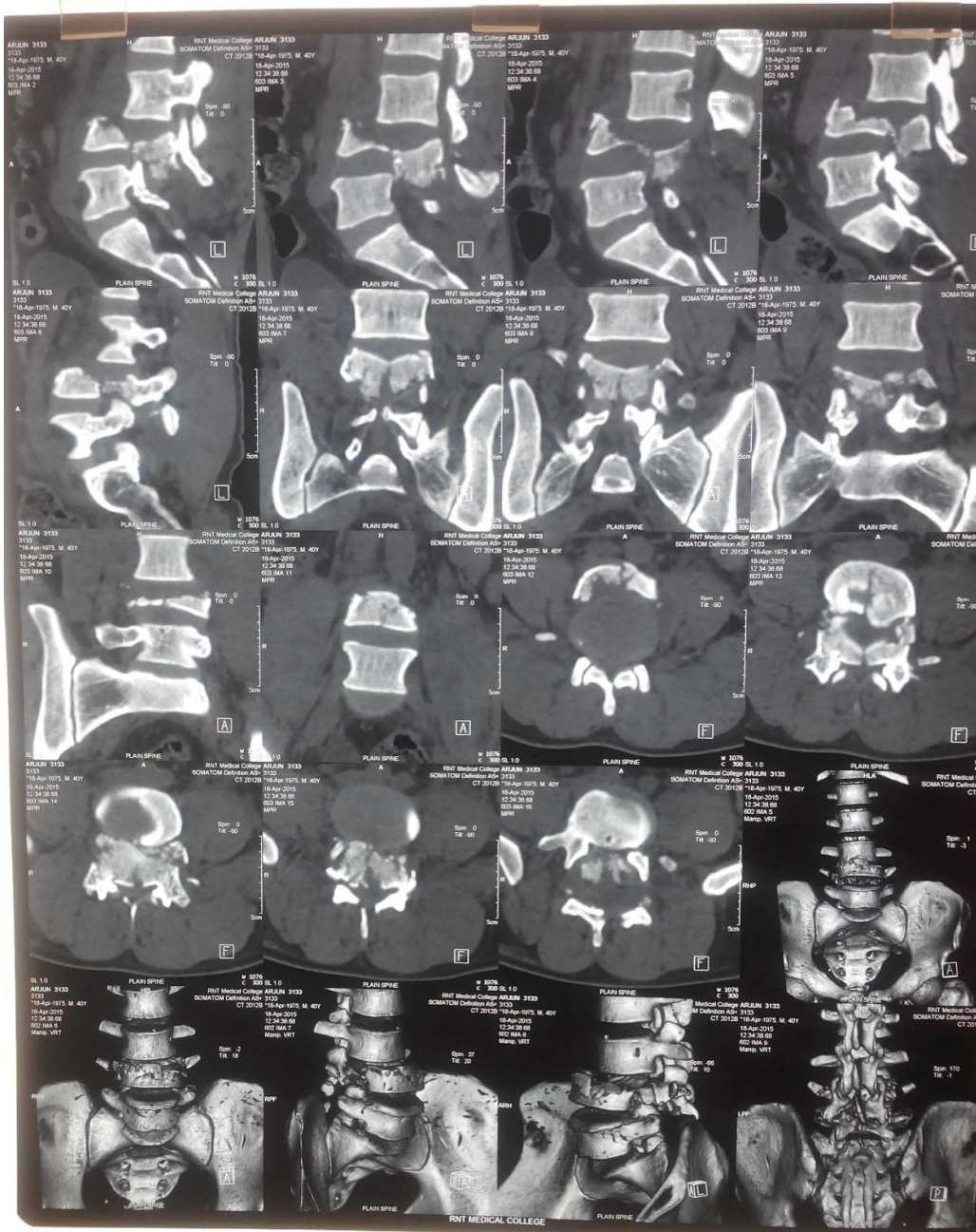fragments causing neurological deterioration or cauda equina syndrome.

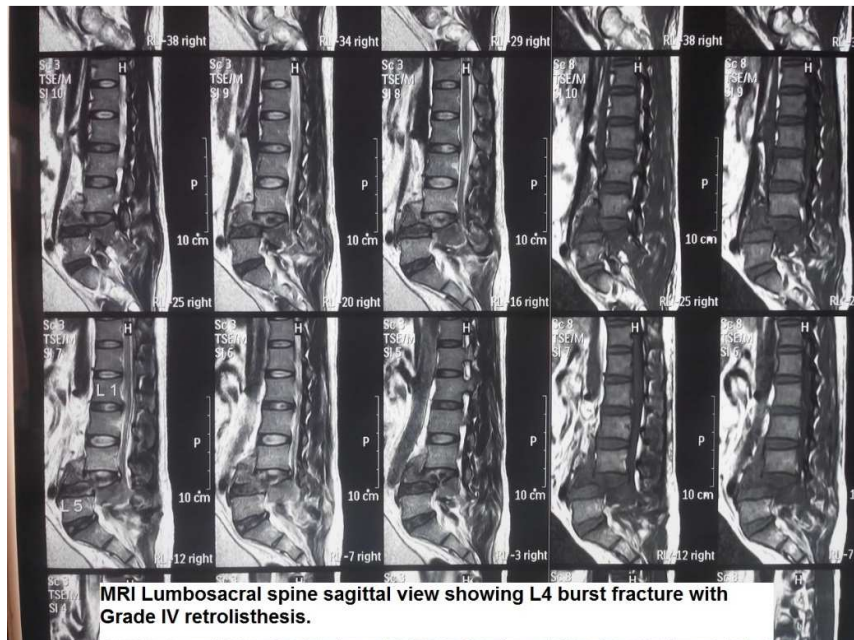
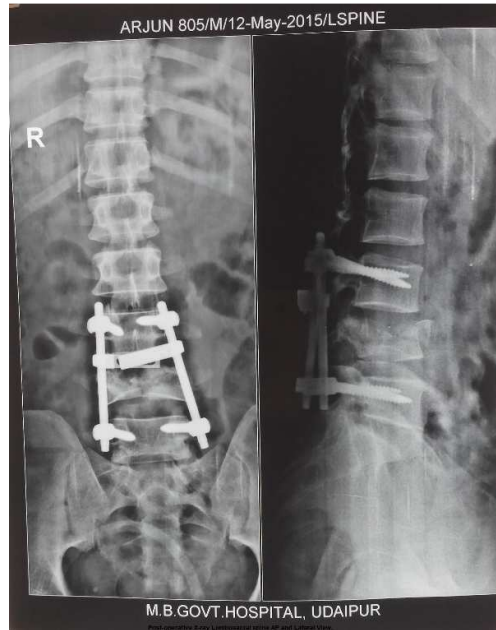
Kun Soo Jang et al, reported a similar case of L4 burst fracture with 85% of canal compromise and no neurological deficit, treated with short segment posterior fixation

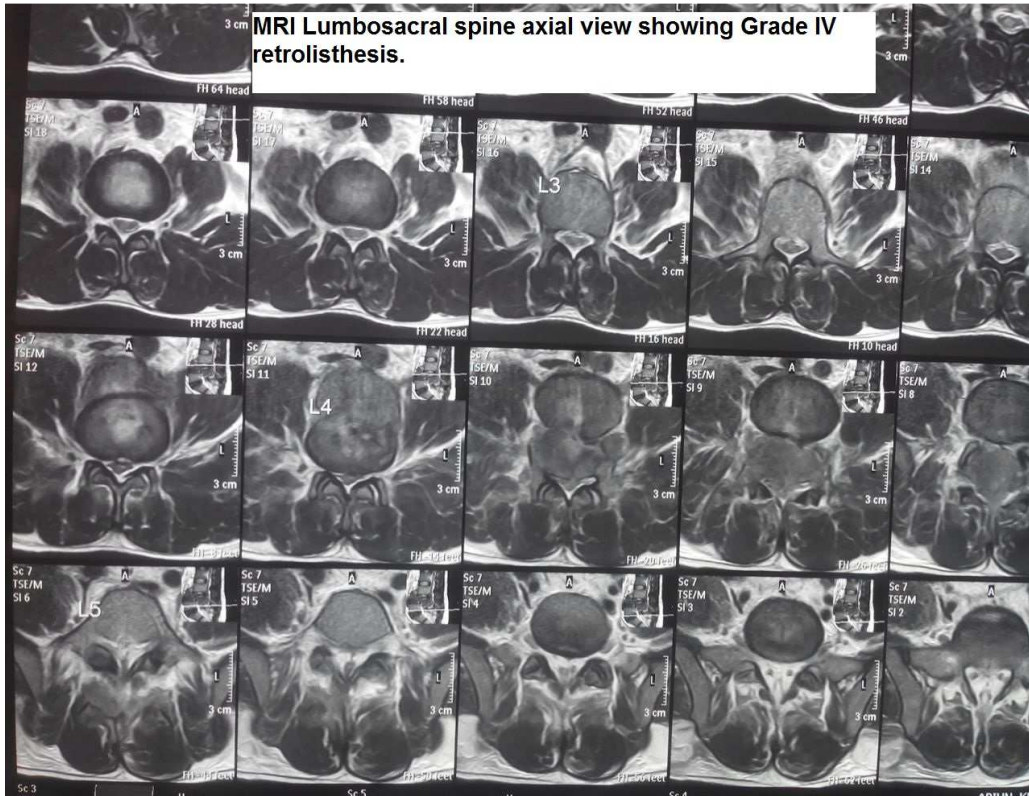
without bone fusion. He had convincing result in his patient (7).

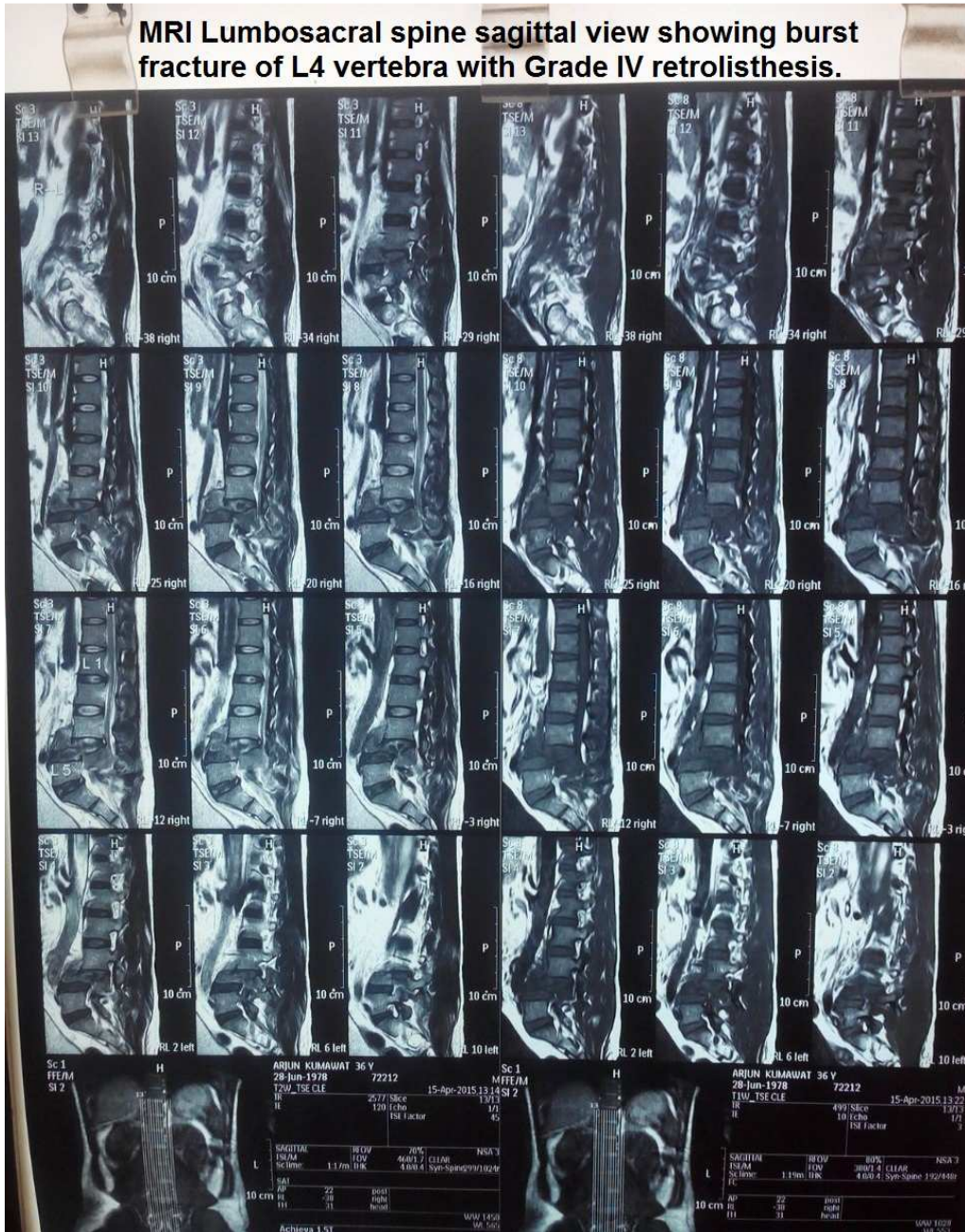
Pelegri C et al, reported a retrospective study of 15 pt of thoraco-lumbar and lumbar burst fracture treated with percutaneous osteosynthesis via pedicle screw fixation without fusion with good results (10).

CTscan of Lumbosacral spine showing burst fracture of L4 vertebra with Grade IV retrolisthesis.









Conclusion

There is no definitive correlation between the spinal canal compromise and neurological

deficit in burst fracture of low lumbar vertebra fracture, unlike fracture at other vertebral levels. Neurological deficit may not be present even if there is canal compromise of more than 90%. Short segment posterior stabilization with pedicle screw is a simple and reliable method of treatment if patient is neurologically intact due to advantage of early pain relief and early mobilisation.

Correspondence

Rahul Patil

*Room No. - 107-109, P.G. Boys Hostel,
R.N.T.Medical College, Udaipur- 313001,
Rajasthan, India*

E-mail address: dr.rahulpatil@hotmail.com

References

1. Andreychik DA, Alander DH, Senica KM (1996) Burst fractures of the second through fifth lumbar vertebrae. *J Bone Joint Surg Am* 78:1156–1166.
2. Brant-Zawadzki M, Jeffrey RB, Minagi H (1982) High resolution CT of thoracolumbar fractures. *AJR Am J Roentgenol* 138:699–704
3. Chan DP, Seng NK, Kaan KT. Nonoperative treatment in burst fractures of the lumbar spine (L2-L5) without neurologic deficits. *Spine*. 1993;18:320–325
4. Finn CA, Stauffer ES. Burst fractures of the fifth vertebra. *J Bone Joint Surg Am*. 1992;74:398–403.
5. Kostuik JP. Anterior fixation for burst fractures of the thoracic and lumbar spine with or without neurological involvement. *Spine*. 1988;13:286–293.
6. Kraemer WJ, Schemitsch EH, Lever J, McBroom RJ, McKee MD, Waddell JP. Functional outcome of thoracolumbar burst fractures without neurological deficit. *J Orthop Trauma*. 1996;10:541–544.
7. Kun Soo Jang, Chang Il Ju, Seok Won Kim, and Sung Myung Lee; Screw Fixation without Fusion for Low Lumbar Burst Fracture : A Severe Canal Compromise But Neurologically Intact Case; *J Korean Neurosurg Soc*. 2011 Feb; 49(2): 128–130.
8. Mohanty SP, Venkatram N. Does neurological recovery in thoracolumbar and lumbar burst fractures depend on the extent of canal compromise? *Spinal Cord*. 2002;40:295–299.
9. Okuyama K, Abe E, Chiba M, Ishikawa N, Sato K. Outcome of anterior decompression and stabilization for thoracolumbar unstable burst fractures in the absence of neurologic deficits. *Spine*. 1996;21:620–625.
10. Pelegri C, Benchikh El Fegoun A, Winter M, Brassart N, Bronsard N, Hovorka I, de Peretti F; Percutaneous osteosynthesis of lumbar and thoracolumbar spine fractures without neurological deficit: surgical technique and preliminary results; *Rev Chir Orthop Reparatrice Appar Mot*. 2008 Sep;94(5):456-63.
11. Robert F Heary and Sanjeev Kumar Decision-making in burst fractures of the thoracolumbar and lumbar spine. *Indian J Orthop*. 2007 Oct-Dec; 41(4): 268–276.
12. Seybold EA, Sweeney CA, Fredrickson BE, Warhold LG, Bernini PM. Functional outcome of low lumbar burst fractures. A multicenter review of operative and nonoperative treatment of L3-L5. *Spine*. 1999;24:2154–2161.
13. Yazar T, Cebesoy O, Soydan C, Köse C. Acute burst fracture of the low lumbar vertebra managed by anterior surgery. *Journal of Ankara Medical School*. 2004;26:41–45.