

## Growing skull fracture in a 2 months old child

A. Tascu<sup>1</sup>, Iulia E.B. Vapor<sup>1</sup>, A. Iliescu<sup>1</sup>, Irina Tudose<sup>1</sup>,  
St.M. Iencean<sup>2</sup>

<sup>1</sup>Pediatric Neurosurgical Department, "Bagdasar-Arseni" Clinical Hospital, Bucharest, Romania

<sup>2</sup>"Gr. T. Popa" University of Medicine and Pharmacy, Iassy, Romania

**Abstract:** A growing skull fracture, also called posttraumatic leptomeningeal cyst, is a rare complication of skull fractures - less than 1%, usually encountered in children younger than 3 years old. Although rare, this complication must be recognized early and treated to prevent permanent neurologic deficits. We present the case of a 2 months old child who had suffered a closed head trauma in a car accident 2 weeks before he was admitted in our clinic with a left parietal growing skull fracture. He was submitted to surgery and leptomeningeal cyst was evacuated, dural defect repaired and bone fragments fixed. Child was discharged 6 days postoperative without neurologic deficits. Growing skull fractures represent a rare complication of head trauma in small children. It is imperious to be recognized and treated in early phases to prevent debilitating permanent neurologic deficits in that category of population.

**Key words:** growing skull fracture, leptomeningeal cyst.

### Introduction

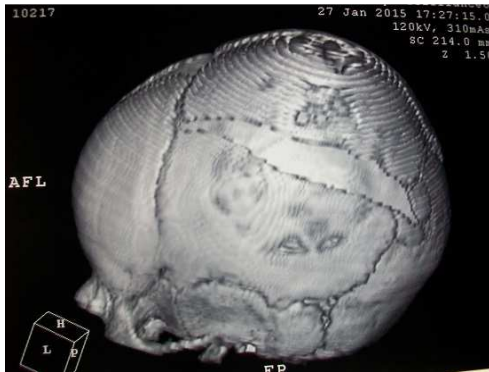
Growing skull fracture is a rare complication of paediatric skull fracture. It is a poorly understood complication of head trauma and it results in dural tear and brain lesion that can enlarge the initial linear fracture. It is also called posttraumatic leptomeningeal cyst and the usual site is parietal bone, with a palpable bony defect. We present the case of a 2 months old child with a closed head trauma in a car accident 2 weeks before the admission in our clinic.

### Case presentation

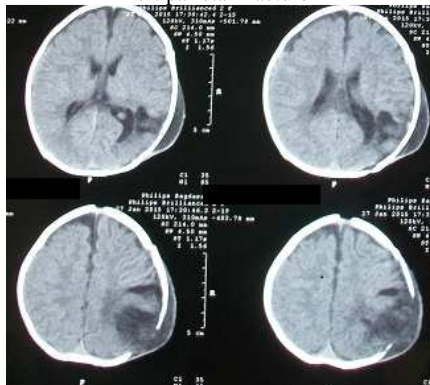
In this paper we present the case of a child who was admitted in our clinic at the age of 11 weeks with a big subgaleal fluid collection in the left parietal region. Two weeks before admission in our clinic the child suffered a head trauma in a car accident. CT-scan

performed at that time revealed a left parietal hemorrhagic contusion and left parietal fracture. The child was discharged one week after trauma with good neurologic condition. At admission in our clinic the child was alert, had no neurologic deficits and at the local exam of the scalp was noticed a tumefaction approximately 5/6 cm, with fluid consistency. CT-scan performed revealed a diastatic left parieto-occipital skull fracture with an underlying porencephalic cyst and subgaleal fluid collection (Figures 1, 2). The child underwent surgery. After incision of the scalp approx 50 ml clear liquid were evacuated. We noticed a diastatic parietal skull fracture from coronal suture to lambdoid suture and part of occipital bone. Through fracture edges herniated cerebral tissue (Figure 3). The craniotomy was made considering the fact that ruptured dura mater usually is retracted under the edges of the fracture. After removing the bone flap, margins of dura were adjusted,

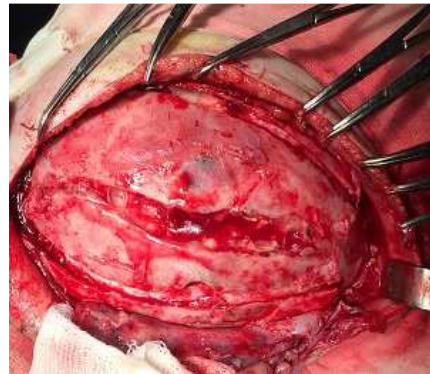leptomeningeal cyst evacuated and scarred brain tissue removed (Figure 4). After that we made duraplasty using pericranium. The two bone fragments were rigidly fixed (Figure 5). CT-scan performed 24 hours postoperatively revealed total evacuation of leptomeningeal cyst without subgaleal fluid collection and fixation of bone flap. Child was discharged 6 days postoperative alert, without neurologic deficits and normal healing of wound.



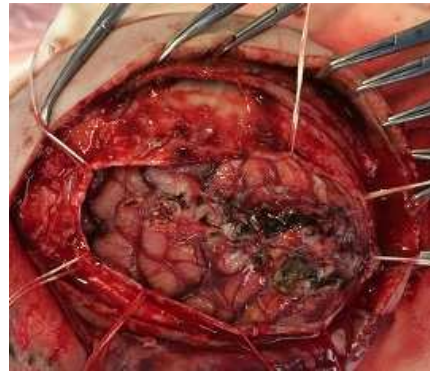
**Figure 1** - Preoperative CT scan showing a diastatic left parietal fracture



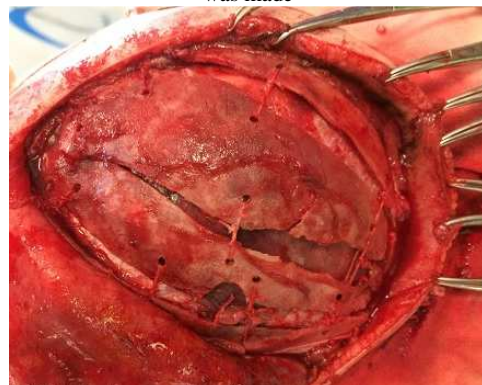**Figure 2** - Preoperative CT scan showing diastatic fracture with an underlying porencephalic cyst and subgaleal fluid collection



**Figure 3** - Through fracture edges can be noticed cerebral tissue



**Figure 4** - Intraoperative aspect before the duraplasty was made



**Figure 5** - Intraoperative aspect after fixation of bone flaps

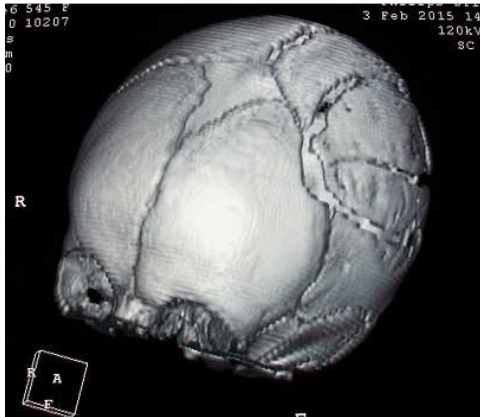


Figure 6 - postoperative 3D reconstruction CT-scan

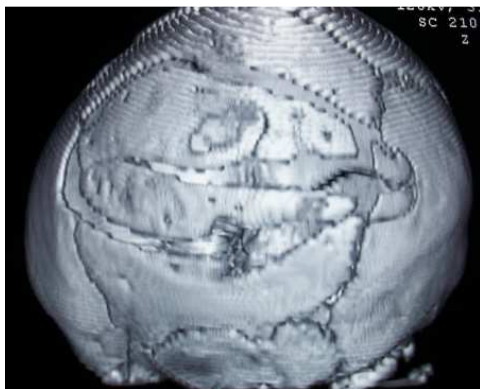

Figure 7 - postoperative 3D reconstruction CT-scan

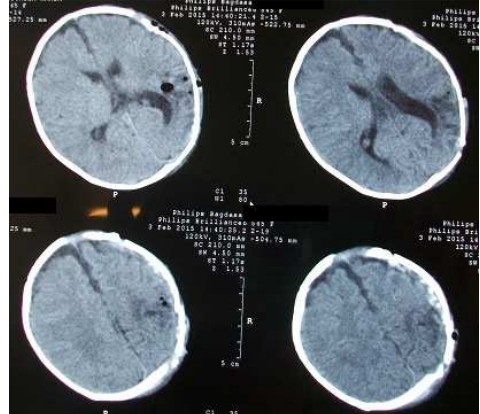


Figure 8 - postoperative CT-scan

A growing skull fracture is a rare but significant complication of pediatric head trauma, occurring almost exclusively in children who are younger than 3 years of age. It usually develops from a linear skull fracture, as sometimes occurs in a closed-head injury. Therefore, it is often misdiagnosed or the treatment is either wrong or delayed.

First condition in recognizing and proper treating a GSF is understanding of pathogenesis of this condition. It is unanimously accepted that a skull fracture, with underlying dural tearing and entrapment of the arachnoid membrane or brain tissue within the fracture margins, is the most important factor for GSF pathogenesis. In small children brain growing leads to increasing bone defect and herniation of cerebral tissue through the bone defect. In the early stage of GSF, the main damages to the brain and bone are caused by the injury itself. However, the damages as well as the neurological deficits will increase during the progression of GSF, especially in the late stage. The neurological deficits cause the main disruption in the quality of life for most patients with GSF. Against this background, reasonable classification of the progression of GSF as well as early diagnosis and rational surgical treatment for GSF will lead to improvement in prognosis. Xue-Song Liu classified GSF in 3 stages: prephase of GSF from the time of injury until the beginning of enlargement of fracture; early phase of GSF 2 months from beginning of enlargement of fracture and late phase of GSF that begins at 2 months after initial enlargement. Best surgical results are obtained in the first two stages. Stanford proposes a strategy he used for 35 years to prevent development of GSF. He explores surgically all linear fractures wider than 5 mm, in which brain IRM reveals herniated brain tissue through fracture margins.

Regarding surgery, there are certain aspects you must take into consideration.

## Discussions

Scalp incision must be made so that whole fracture must be visualized and included in bone flap. After inspection of fracture, bone flap is made considering that dural margins are retracted 1-2 cm under fracture margins. After removing bone flaps intact dura is identified and carefully freed from herniated brain tissue. The most important step of surgery is water-tight closure of the dural defect. Pericranium, fascia lata, cadaveric dural grafts, and artificial dura have been used in this step. In our opinion, the autologous material is the best choice because of its tissue compatibility, convenience, inexpensiveness, and low rate of infection. Rigid bone fixation is also important or else pulsating brain will lead to bone resorption. In small children new lateral bone growth will leave no defect over time. In case of persistent bone defect cranioplasty will be made.

### Conclusion

Follow-up after head injury is very important to avoid misdiagnosis in GSF. Most delays in diagnosis and treatment of GSF's are

related to the lack of knowledge and awareness of the condition among doctors, parents and caregivers. The parents should be informed about the possibility of GSF and be instructed to watch for any persistent or progressive scalp swelling and onset of any neurological signs and symptoms.

### References

1. Howship J: Practical Observations in Surgery, and Morbid Anatomy. London: A. Strahan, 1816
2. Khandelwal S, Sharma G L, Gopal S, Sakhi P. Growing skull fractures/leptomeningeal cyst. Indian J Radiol Imaging 2002;12:485-6
3. Naim-u-Rahman, Jamjoom Z, Jamjoom A, Murshid WR. Growing skull fractures: Classification and management. Br J Neurosurg;8: 667-79. 1994
4. Robert A. Sanford: Prevention of growing skull fractures. J Neurosurg Pediatrics 5:000-000, 2010
5. Xue-song Liu, M.D., Chao You, M.D., Ph.D., Ma Lu, M.D., Ph.D., and Jia-gang Liu, M.D. Growing skull fracture stages and treatment strategy J Neurosurg Pediatrics 9:670-675, 2012]
6. Ziyal IM, Aydin Y, Türkmen CS, Salas E, Kaya AR, Ozveren F: The natural history of late diagnosed or untreated growing skull fractures: report on two cases. Acta Neurochir (Wien) 140:651-654, 1998