

Partial thrombosed parasagittal AVM, complete resection. Case report

Aurelia Mihaela Sandu¹, M.R. Gorgan²

¹PhD Student in Neurosurgery, University of Medicine and Pharmacy "Carol Davila" Bucharest, Faculty of Medicine, Department of Neurosurgery; Clinic of Neurosurgery, Fourth Department of Neurosurgery, Emergency Clinical Hospital Bagdasar-Arseni, Bucharest

²Professor in Neurosurgery, University of Medicine and Pharmacy "Carol Davila" Bucharest, Faculty of Medicine, Department of Neurosurgery; Clinic of Neurosurgery, Fourth Department of Neurosurgery, Emergency Clinical Hospital Bagdasar-Arseni, Bucharest

Abstract: INTRODUCTION: Arteriovenous malformations (AVMs) are congenital lesions formed by a network of dysplastic vessels. CASE REPORT: We report a case of a 63 years old man, admitted with seizures and headache. Imaging findings, angio-CT, angio-MR and angiography revealed a partially thrombosed right parasagittal frontal AVM, with fully thrombosed associated flow-related aneurysm on the main arterial feeder. The patient underwent surgery and we performed total resection of the AVM. The particularity of this case is the rare possibility of outcome with regression of the vascular malformation. CONCLUSIONS: Brain AVMs are evolutive lesions. Regression, through progressive thrombosis of the nidus is a rare possible outcome in brain AVMs. In thrombosed AVMs angiography is not reliable, and angio-CT and/or angio-MR are mandatory, in order to correctly evaluate nidus size and associated lesions. Symptomatic AVMs require surgery. Partial thrombosed AVMs can be safely resected.

Key words: arteriovenous malformation, AVM surgery, thrombosed nidus

Introduction

Vascular malformations of the brain are a heterogeneous group of non-neoplastic anomalies of cerebral blood vessels, arteries, veins, capillaries, with modified flow. (14;44) Vascular malformations of the brain occur as a consequence of persistence of a primitive model secondary to a defect in embryological development. (44) McCormick divided vascular malformations of the brain in: arteriovenous malformations (AVMs), cavernomas, venous angiomas, capillary telangiectasia and arteriovenous fistulas. (23)

Brain AVMs are congenital non-neoplastic lesions, containing a high complexity network of dysplastic vessels. The network of vessels, called nidus, is formed by complex direct

connections between arteries and veins through vascular shunts, thus oxygenated blood is carried from the arterial system directly into the venous system without passing through capillary bed. The nidus is fed through dilated arteries and blood is drained through arterialized veins. (14;21;22;38;44)

Brain AVMs are rare lesions. The incidence of symptomatic AVMs is 0.89-1.34 cases/100,000 inhabitants/year (4;5;19) and prevalence is 0.02-0.2% (2;3;19;37;42). Although they are no common pathology, brain AVMs represent a continuous and prolific field of research (10-12;33-35), because social impact of this disease is high. AVMs are commonly found in young people, mean age at diagnosis being 33.7-35

years.(3;4;15;19) Natural history reveals a o mortality rate of 0.7-2.9%/year.(4;19;28)

Case report

We report a case of a right parasagittal frontal, partial thrombosed AVM who was operated by the senior neurosurgeon into the Fourth Department of Neurosurgery, Emergency Clinical Hospital Bagdasar-Arseni from Bucharest. We reviewed medical records, imaging, treatment and follow-up. A man, 63 years old was admitted in department with grand mal seizures for four years and headache. The patient presented history of ischemic coronary disease, old myocardial infarction, coronary stent and diabetes mellitus type II. The neurological exam revealed no neurological deficits.

Brain CT-scan showed a right frontal lesion, inhomogeneous, contrast enhancing, with calcifications. Angio-CT showed an right parasagittal frontal AVM, with nidus sizing 3/2 cm, containing partial calcified vessels, with feeding arteries coming from right anterior cerebral artery (ACA), which is enlarged (3 mm in diameter). A saccular aneurysm was found on the A2 segment of right ACA (4 mm dome, 2 mm neck).

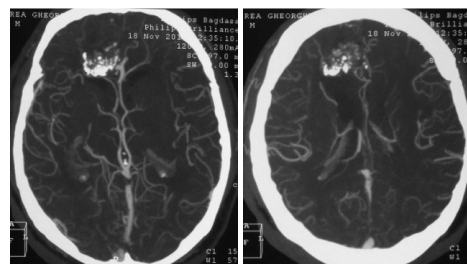
Brain MRI showed a right parasagittal frontal AVM, located in girus cinguli and superior frontal lobe, with 3 cm maximal diameter, with feeding arteries from right ACA and venous drainage into a dilated anterior frontal vein and finally into the superior sagittal sinus (SSS). Right ACA is enlarged, 3 mm in diameter and had high flow. The saccular aneurysm from A2 segment of right ACA had no vascular flow void inside. In the surrounding brain there are hemosiderin deposits, areas of calcifications and gliosis. A porencephalic cavity is a sign of previous bleeding.

Four vessels angiography showed a low flow right frontal AVM, fed from the right callosomarginal artery. Right callosomarginal artery presented areas of stenosis and irregular

caliber. The nidus was 1 cm in size. Venous drainage is not detected and is probably done into the SSS. The angiography also revealed marked atherosclerosis.

The patient underwent surgery. We entered the interhemispheric fissure and we found an AVM corticalized on the medial surface of the frontal lobe. The nidus was composed of patial thrombosed vessels. We identified and coagulated two feeding arteries coming from the right callosomarginal artery. The nidus was circumferentially dissected and mobilized into the interhemispheric fissure to facilitate deep dissection. The deep part of the nidus reached the ependymal surface, and frontal horn of the lateral ventricle was opened. Finally, two draining veins, into the SSS and into the inferior sagittal sinus were occluded with vascular clips. An external ventricular drainage was left in the frontal horn of the lateral ventricle. The wound was closed in anatomical layers.

The outcome was favorable, the patient presented no postoperative neurological deficits. Following surgery, the patient presented no seizures under 600 mg Carbamazepin/day. The external ventricular drainage was kept for 3 days.



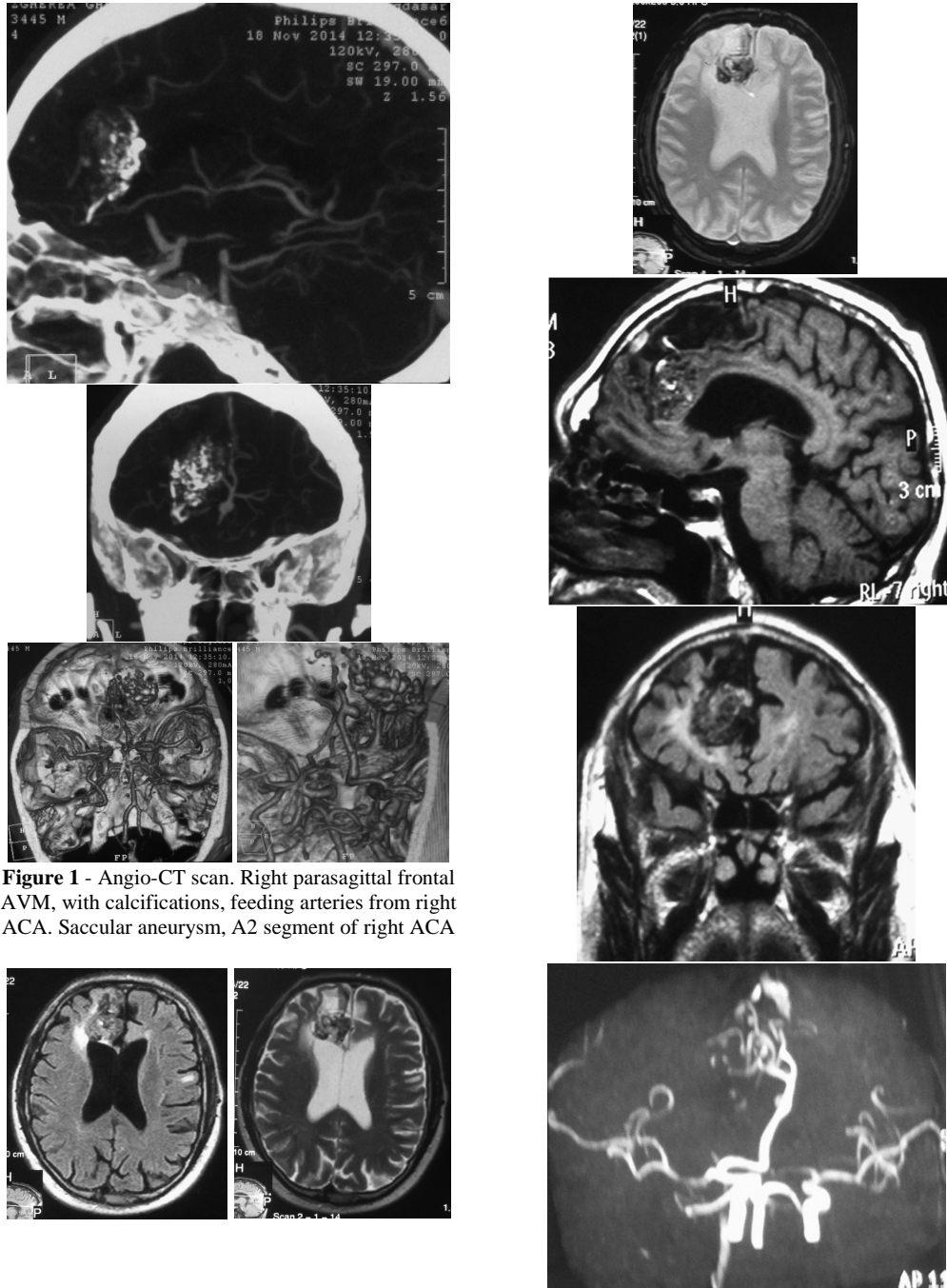


Figure 1 - Angio-CT scan. Right parasagittal frontal AVM, with calcifications, feeding arteries from right ACA. Saccular aneurysm, A2 segment of right ACA

Figure 2 - Brain MRI. Right parasagittal frontal AVM, with feeding arteries from right ACA and venous drainage into a dilated anterior frontal vein. Hemosiderin deposits, areas of calcifications and gliosis in the surrounding brain

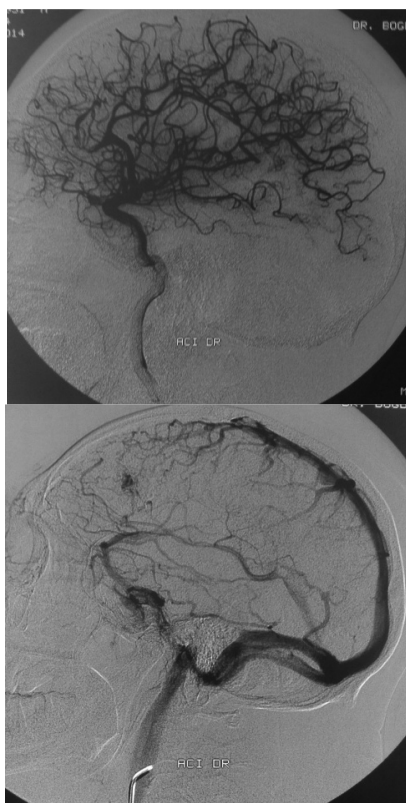


Figure 3 - Right ICA angiography. Low flow right frontal AVM, with feeding artery from right callosomarginal artery. Nidus is 1 cm in diameter, injected in the venous phase. Atherosclerosis

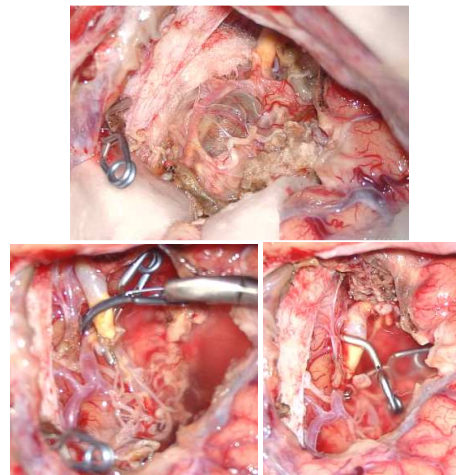
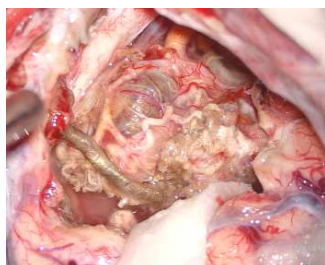

Figure 4 - Intraoperative images

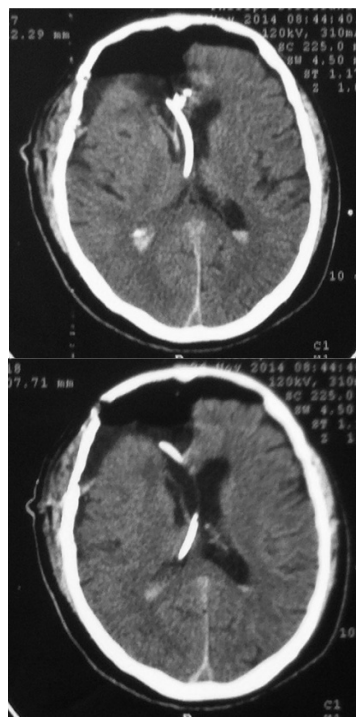


Figure 5 - Postoperative CT-scan. Catheter located into the right lateral ventricle

Discussions

Approximately 90% of the AVMs are asymptomatic during the patients' life and become necrotic discoveries. Among the hospitalized cases only 2.5% of cases are asymptomatic. (4) Annual rate of patients who develop symptoms is 0.14-0.8%/year. (17) Lately there is an increase in number of newly diagnosed asymptomatic cases, this seem to be a consequence of widely spreading routine cerebral imaging studies.(19) The case report by us was 63 years old, much older than mean age for AVMs diagnosis, which is 33.7-35 years. (3;4;15;19)

The most common form of clinical presentation is cerebral hemorrhage, secondary to AVM's rupture. AVMs accounts for 3% of ischemic stroke and 33% of hemorrhagic stroke in young people.(17) The second most common form of clinical presentation is epilepsy. In patients who present with seizures, following surgery through resection of the irritative lesions, seizures' control is good. In time, if patients present no seizures, progressive reduction of antiepileptic drugs can be tried. (36)

In our patient we found a partial thrombosed AVM. AVMs are evolutive lesions. In most cases AVMs tend to enlarge in size and velocity from childhood to adulthood. In some cases AVMs tend to regress. In such cases the nidus is partially or completely thrombosed. Spontaneous regression of AVMs is rare, so far in literature being reported only 67 cases demonstrated angiographically. (1;7;20;29;30) Mechanism of AVM regression is represented by spontaneous thrombosis of the nidus. Factors that lead to spontaneous thrombosis of the AVM are represented by atherosclerosis of feeding arteries, thromboembolism starting in associated thrombosed aneurysm, neighboring hematoma or edema compressing the nidus, perilesional gliosis, partial endovascular embolization and hypercoagulable state.(1;7;20;29;30) Usually spontaneous regression occurs in small lesions, with few

feeding arteries and single draining vein.(27) One factor favoring thrombosis of the nidus, found in our case is marked cerebral atherosclerosis, mainly on the feeding artery. Another favoring factor is represented by the associated aneurysm. It was located on the main feeding artery, A2 segment of right ACA. The aneurysm can be seen on the angio-CT scan, the angio-MR reveals no flow void inside it and is not visible on the angiography, therefore it can be assumed that the aneurysm is also thrombosed, and can lead to nidus embolization with thrombi. Calcifications are also signs of nidus involution. The particularity of this case is the rare possibility of outcome with regression of the vascular malformation.

Flow-related aneurysms occur as a consequence of hemodynamic changes in blood flow induced by the malformative lesion. Unruptured flow-related aneurysms need no surgery, because they are a consequence of blood flow changes, and after AVM resection and restoring of normal flow they will disappear. (8;9;16;40) Only ruptured aneurysms require surgery.

Thrombosed AVM is easier to operate compare with a patent one. It has low flow, the vessels are filled with thrombi, and do not bleed when cut. Taking into consideration that the AVM was only partially thrombosed, we applied the same principles as in AVM surgery, occlusion of feeding arteries first, followed by circumferential dissection and occlusion of draining veins, in the end. Surgery is similar with AVM resection after embolization with onyx. Circumdissection was facilitated by surrounding gliosis and pencephalic area. All, together with hemosiderin deposits are signs of previous bleeding. AVMs have a conic shape, and tip of the lesions reaches the ventricular wall. If the ventricle is opened, all blood should be washed to prevent hydrocephalus occurrence. Placement of an external ventricular shunt, for

a few days, is a useful tool in preventing hydrocephalus occurrence.

In most cases angiography is the gold-standard imaging for brain AVMs. The only exception is thrombosed lesions. The AVM is partial thrombosed, the contrast is enhanced only in the patent compartment. The patent nidus is three times smaller than in reality. Angio-CT and angio-MR showed the real size of the lesion. On the angiography the nidus did not enhance at all in the arterial phases, appearing only in the late, venous phase. The thrombosed flow related aneurysm is not seen on angiography. In thrombosed AVMs angiography is not reliable, and angio-CT and/or angio-MR are mandatory.

ApSimon et al. believe that most AVMs become symptomatic during the patient's life, in most cases with brutal rupture and intracranial hemorrhage. (4) ARUBA phenomenon radically changed the way of thinking in unruptured brain AVMs.(25;26) ARUBA was a prospective, controlled, randomized, multicentre, international trial, which counted the risk of developing cerebral symptomatic stroke or death in patients with unruptured AVMs, who underwent either surgery or conservative treatment. ARUBA phenomenon completely changes the vision regarding this pathology, the interventionist therapeutical attitude from the pre-ARUBA era, being replaced by a conservative one. Relevant literature study reveals that similar results can be found, such as reports of old, asymptomatic patients, with incidental AVM. This study had sparked various reactions to the medical world(13;18;24;31;32;39;41;43), and so far there is no consensus regarding an optimal therapy algorithm in unruptured AVMs. Choosing between surgical and conservative attitude depends on a variety of factors related to the characteristics of the lesion, medical status of the patient, patient and family desire and preference of neurosurgeon. Other authors proved the

superiority of surgery for certain patients with unruptured AVMs. (6)

Conclusions

Brain AVMs are evolutive lesions. Regression, through progressive thrombosis of the nidus is a rare possible outcome in brain AVMs. In thrombosed AVMs angiography is not reliable, and angio-CT and/or angio-MR are mandatory, in order to correctly evaluate nidus size and associated lesions. Symptomatic AVM require surgery. Partial thrombosed AVMs can be safely resected.

Correspondence

Aurelia Mihaela Sandu

Address: Emergency Clinical Hospital Bagdasar-Arseni, No. 10-12, Berceni Street, Sector 4, Bucharest; e-mail: aurasandu@gmail.com; tel. 0724.263.023

Abbreviations

*ACA – anterior cerebral artery
AVM - arteriovenous malformation
SSS – superior sagittal sinus*

Acknowledgement

This paper was co-financed from the European Social Fund, through the Sectorial Operational Programme Human Resources Development 2007-2013, project number POSDRU/159/1.5/S/138907 "Excellence in scientific interdisciplinary research, doctoral and postdoctoral, in the economic, social and medical fields - EXCELIS", coordinator The Bucharest University of Economic Studies.

References

1. Abdulrauf SI, Malik GM, & Awad IA. (1999). Spontaneous angiographic obliteration of cerebral arteriovenous malformations. *Neurosurgery* 44, 280-287.
2. Al-Shahi R, Bhattacharya JJ, Currie DG, Papanastassiou V, Ritchie V, Roberts RC, Sellar RJ, & Warlow CP. (2003). Prospective, population-based detection of intracranial vascular malformations in adults: the Scottish Intracranial Vascular Malformation Study (SIVMS). *Stroke* 34, 1163-1169.
3. Al-Shahi R & Warlow C. (2001). A systematic review of the frequency and prognosis of arteriovenous

- malformations of the brain in adults. *Brain* 124, 1900-1926.
4. ApSimon HT, Reef H, Phadke RV, & Popovic EA. (2002). A population-based study of brain arteriovenous malformation: long-term treatment outcomes. *Stroke* 33, 2794-2800.
 5. Berman MF, Sciacca RR, Pile-Spellman J, Stapf C, Connolly ES Jr, Mohr JP, & Young WL. (2000). The epidemiology of brain arteriovenous malformations. *Neurosurgery* 47, 389-396.
 6. Bervini D, Morgan MK, Ritson EA, & Heller G. (2014). Surgery for unruptured arteriovenous malformations of the brain is better than conservative management for selected cases: a prospective cohort study. *J Neurosurg* 121, 878-890.
 7. Bruis DR, van den Berg R, Lycklama G, van der Worp HB, Driven CM, & Vanterhop WP. (2004). Spontaneous regression of brain arteriovenous malformations--a clinical study and a systematic review of the literature. *J Neurosurg* 251, 1375-1382.
 8. Cunha MJ, Stein BM, Solomon RA, & McCormick PC. (1992). The treatment of associated intracranial aneurysms and arteriovenous malformations. *J Neurosurg* 77, 853-859, 1992.
 9. Flores BC, Klinger DR, Rickert KL, Barnett SL, Welch BG, White JA, Batjer HH, & Samson DS. (2014). Management of intracranial aneurysms associated with arteriovenous malformations. *Neurosurg Focus* 37, E11.
 10. Giovani A, Sandu A, Neacșu A, and Gorgan RM: Surgical treatment and outcome of cerebral cavernomas – a 10 years' experience. *Rom Neurosurg* 21:394-404, 2014.
 11. Gorgan MR, Bucur N, Neacșu A, Sandu AM, Brehar FM, Prună VM, & Giovani A. (2014). Aspecte clinice și microchirurgicale în cavernoamele cerebrale (Clinical aspects and microsurgery in brain cavernomas. A XVII-a Conferință Națională de Stroke (AVC) cu participare internațională, 15-17 octombrie 2014, Brașov, România; abstractul lucrării a fost publicat în Revista Română de Stroke (AVC) 17, 62-64.
 12. Gorgan MR, Ciubotaru VG, Tătăranu LG, Tașcu A, Iliescu A, Bucur N, Neacșu A, Brehar FM, & Sandu AM. (2014). Our experience in a series of 277 brain AVMs, microsurgical treatment and outcome. The 40th Congress of the Romanian Society of Neurosurgery with International Participation, 25-27 septembrie 2014, București, România; abstractul lucrării a fost publicat în *Rom Neurosurg* 21, 525-526.
 13. Grasso G. (2014). The ARUBA study: what is the evidence? *World Neurosurg* 82, e576.
 14. Greenberg MS. (2010). Vascular malformations, in Greenberg MS (ed): *Handbook of neurosurgery*. New York, Thieme Medical Publisher, pp 1098-1142.
 15. Gross BA & Du R. (2013). Natural history of cerebral arteriovenous malformations: a meta-analysis. *J Neurosurg* 118, 437-443.
 16. Halim AX, Singh V, Johnston SC, Higashida RT, Down CF, Halbach W, Lawton MT, Gress DR, McCulloch CE, Young WL, & UCSF BAVM Study Project Brain Arteriovenous Malformation. (2002). Characteristics of brain arteriovenous malformations with coexisting aneurysms: a comparison of two referral centers. *Stroke* 33, 675-679.
 17. Kale SS & Agarwal D. (2013). CNS arteriovenous malformations: classifications and diagnosis. www.docstoc.com/docs/81960364/CNS-Arteriovenous-Malformations-Classifications-and-Diagnosis[11.05.2013].
 18. Knopman J & Stieg PE. (2014). Management of unruptured brain arteriovenous malformations. *Lancet* 383, 581-583.
 19. Laakso A & Hernesniemi J. (2012). Arteriovenous malformations: epidemiology and clinical presentation. *Neurosurg Clin N Am* 23, 1-6.
 20. Lee SK, Vilela P, Willinsky R, & ter Brugge KG. (2002). Spontaneous regression of cerebral arteriovenous malformations: clinical and angiographic analysis with review of the literature. *Neuroradiology* 44, 11-16.
 21. Marciano FF, Vishteh AG, Apostolides PJ, & Spetzler RF. (2000). Arteriovenous malformations - supratentorial, in Kaye AH, Black P (eds): *Operative neurosurgery*. London, Harcourt Publishers Limited, pp 1079-1091.
 22. McCormick WF. (1966). The pathology of vascular ("arteriovenous") malformations. *J Neurosurg* 24, 807-816.
 23. McCormick WF. (1978). Classification, pathology and natural history of angiomas of the central nervous system. *Wkly Update Neurol Neurosurg* 1, 2-7.
 24. Meling TR, Proust F, Gruber A, Niemela M, Regli L, Roche PH, & Vajkoczy P. (2014). On apples, oranges, and ARUBA. *Acta Neurochir (Wien)* 156, 1775-1779, 2014.
 25. Mohr JP, Moskowitz AF, Stapf C, Hartmann A, Lord A, Marshall SM, Mast H, Moquete E, Moy CS, Parides M, Pile-Spellman J, Al-Shahi Salman R, Young WL, Gobin YP, Kureshi I, & Brisman JL. (2010). The ARUBA trial: current status, future hopes. *Stroke* 41, e537-540.
 26. Mohr JP, Parides MK, Stapf C, Moquete E, Moy CS, Overbey JR, Al-Shahi Salman R, Vicaut E, Young WL, Houdart E, Cordonnier C, Stefani MA, Hartmann A, von Kummer R, Brondi A, Berkefeld J, Klijn C, Harkness K, Libman R, Barreau X, Moskowitz AJ, & international ARUBA investigators. (2014). Medical management with or without interventional therapy for unruptured brain arteriovenous malformations (ARUBA): a multicentre, non-blinded, randomised trial. *Lancet* 383, 614-621.
 27. Omojola MF, Fox AJ, Vinuela F, & Debrun G. (1985). Stenosis of afferent vessels of intracranial arteriovenous malformations. *ANJR Am J Neuroradiol* 6, 791-793.

28. Ondra SL, Troupp H, George ED. (1990). Scawab K. The natural history of symptomatic arteriovenous malformations of the brain: a 24-year follow-up assessment. *J Neurosurg* 73, 387-391.
29. Panciani PP, Fontanella M, Carlino C, Bergiu M, & Ducati A. (2008). Progressive spontaneous occlusion of a cerebellar AVM: pathogenetic hypothesis and review of literature. *Clin Neurol Neurosurg* 110, 502-510.
30. Patel MC, Hodgson TJ, Kemeny AA, & Forster DM. (2001). Spontaneous obliteration of pial arteriovenous malformations: a review of 27 cases. *AJNR Am J Neuroradiol* 22, 531-536.
31. Proust F, Roche PH, & Meling TR. (2014). Does ARUBA study improve our knowledge as regards the management of unruptured brain arteriovenous malformations? *Neurochirurgie* 60, 2-4.
32. Russin J & Spetzler R. (2014). Commentary: the ARUBA trial. *Neurosurgery* 75, E96-E97.
33. Sandu A & Gorgan M. (2015). Microsurgery and outcome in 277 brain AVMs, a common cause of hemorrhagic stroke in young people. The 9th World Congress on Controversies in Neurology (CONy), 26-28 March 2015, Budapest, Hungary.
34. Sandu AM. (2015). Electronic national registry of brain arteriovenous malformations - a useful tool in monitoring patients with cerebral vascular pathology. *Congresul Universității de Medicină și Farmacie Carol Davila* 28-30 mai 2015, București, România.
35. Sandu AM, Ciubotaru VG, Tătăranu LG, Tașcu A, Bucur N, Neacșu A, & Gorgan MR. (2014). Clinical aspects, management and outcome of brain arteriovenous malformations - result with microsurgery first policy. *Rom Neurosurg* 21, 369-383.
36. Sandu AM & Gorgan MR. (2013). Total resection in a giant left frontal arteriovenous malformation, grade V Spetzler-Martin - case report. *Rom Neurosurg* 20, 46-56.
37. Soderman M, Andersson T, Karlsson B, Wallace MC, & Edner G. (2003). Management of patients with brain arteriovenous malformations. *Eur J Radiol* 46, 195-205.
38. Spagnolo E. (2012). Surgical management of cerebral arteriovenous malformations, in Quinones-Hinojosa A (ed): *Schmidek & Sweet operative neurosurgical techniques: indications, methods, and results*. Philadelphia, Elsevier-Saunders, pp 1003-1018.
39. Starke RM, Sheehan JP, Ding D, Liu KC, Kondziolka D, Crowley RW, Lunsford LD, & Kassell NF. (2014). Conservative management or intervention for unruptured brain arteriovenous malformations. *World Neurosurg* 82, e668-e669.
40. Thompson RC, Steinberg GK, Levy RP, & Marks MP. (1998). The management of patients with arteriovenous malformations and associated intracranial aneurysms. *Neurosurgery* 43, 202-211.
41. Warlow C, Al-Shahi Salman R, Lawton MT, Abla AA, Gross BA, Scott RM, Smith ER, Solomon RA, & Connolly ES Jr. (2014). Management of brain arteriovenous malformations - Comments on Medical management with or without interventional therapy for unruptured brain arteriovenous malformations (ARUBA): a multicentre, non-blinded, randomised trial. *Lancet* 383, 1632-1635.
42. Weber F & Knopf H. (2006). Incidental findings in magnetic resonance imaging of the brains of healthy young men. *J Neurol Sci* 240, 81-84.
43. Weber MA. (2014). Cerebral arteriovenous malformations: Results of the ARUBA study. *Radiologe* 54, 422-424.
44. Yasargil MG. (1987). *Microneurosurgery*. IIIA. AVM of the brain, history, embryology, pathological considerations, hemodynamics, diagnostic studies, microsurgical anatomy. Georg Thieme Verlag, Stuttgart; Thieme Medical Publishers, Inc., New York.