

## Combined treatment for complex intracranial aneurysm

A. Chiriac<sup>1,\*</sup>, Georgiana Ion<sup>\*</sup>, N. Dobrin<sup>\*</sup>, St.M. Iencean<sup>1</sup>, I. Poata<sup>1,\*</sup>

<sup>1</sup>“Gr. T. Popa” University of Medicine and Pharmacy, Iasi

<sup>\*</sup>“Prof. Dr. N. Oblu” Clinic Emergency Hospital, Iasi

**Abstract:** Complex aneurysms often cannot be completely excluded by a single approaches. Today successful treatment of these lesions requires a combination between microsurgical and endovascular techniques. Planning of combined treatment require a very good understanding of aneurysm anatomy and a close collaboration between neurosurgeon and neuroendovascular interventionist. Endovascular coiling can usually be used as early treatment for a partially aneurysm occlusion including the ruptured area and followed by definitive clipping. On the other hand microsurgical clipping also can be used as first treatment for complex aneurysm neck reconstruction, allowing successful secondary placement of coils inside the remnant aneurysm sac.

**Key words:** complex intracranial aneurysms, combined treatment.

### Introduction

The aim of treatment in patient with cerebral aneurysms is the permanently exclusion of the entire vascular lesion from the arterial circulation by a complete obliteration of their lumen. Both surgical and endovascular treatments may offer a stable and totally occlusion of the cerebral aneurysm with long-term outcome. However, aneurysm remnants after microsurgical clipping were documented in 4% to 8% of the patients who undergo angiographycal evaluation postoperatively. These remnants are usually associated with a persistent risk of rebleeding with potentially sever or even fatal consequences. The rebleeding events were reported even short or long time after surgery.

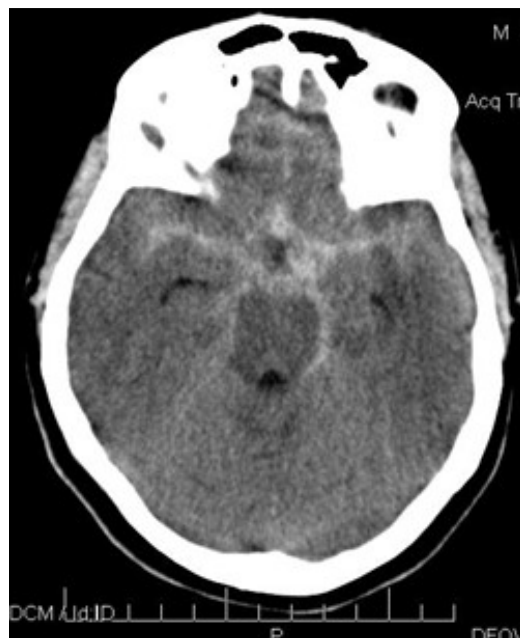Microsurgical reintervention is usually advocated in patients with incomplete aneurysm clipping. However, these procedures are often technically difficult due to a difficult brain scar microdissection around the clip or an instable medical condition after a second rebleeding. Endovascular embolisation has been reported as successfully alternative for these postoperative aneurysm remnants and sometime may represents a good alternative for these special situations. We report a case with a rapid remnant aneurysm rebleeding after incomplete clipping who was successfully obliterated by endovascular coil occlusion.

### Case report

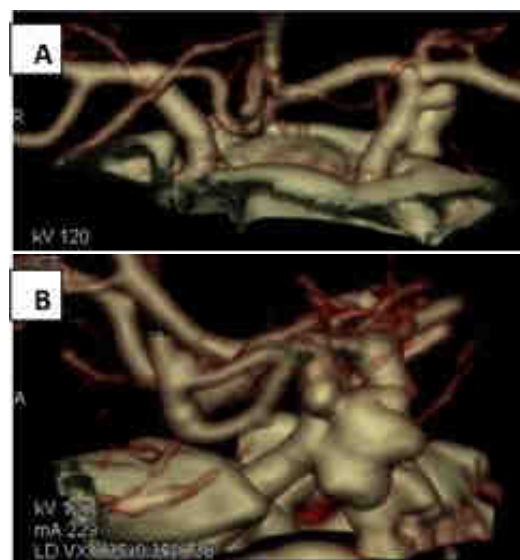
The female patient aged 54 years, was admitted to our emergency room in coma grade III and blood pressure values of 80 mmHg under administration of dopamine. The family declares beginning of the symptoms in the morning with strong headache followed by vomiting and loss of consciousness. The emergency brain CT scan revealed a subarachnoid hemorrhage into both sylvian fissure, the basal cisterns and forth ventricle (figure 1). CT-Angiography showed a complex left side posterior communicating artery aneurysm with large neck as source of bleeding. Also, a small associated left anterior choroidal artery (AChA) aneurysm was revealed (figure 2).

The first decision was to stabilize the general conditions of the patient. During 48 hours hospitalization in to ICU patient's condition improves at GCS = 14. The blood pressure values become stable at 120 mmHg without supportive treatment. In this condition a surgical closure of the aneurysms was decided. A left pterional approach was performed with micro dissection of carotid cistern and proximal part of sylvian fissure and aneurysms exposure. A total clip occlusion of the small left anterior choroidal artery aneurysm was obtained.

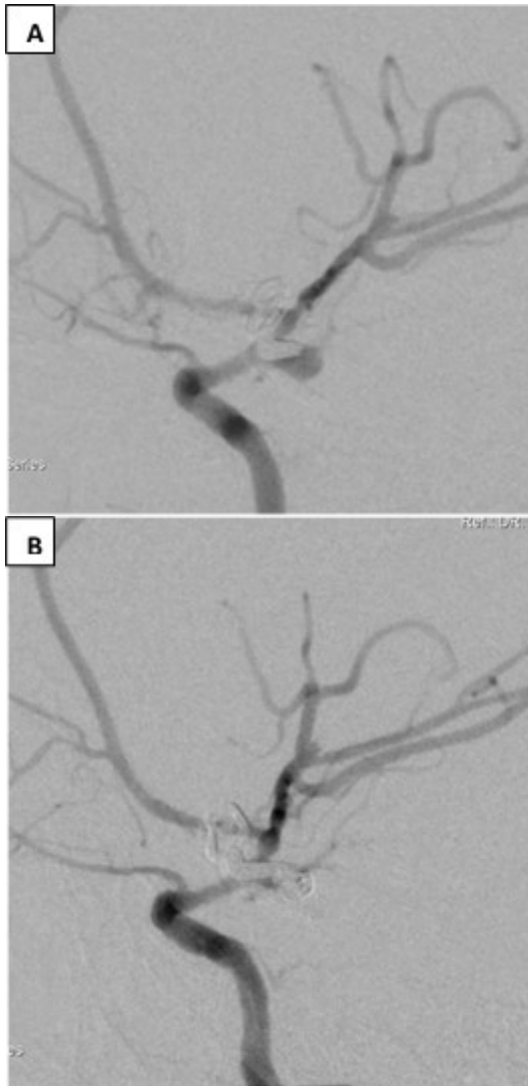The complex anatomical configuration of the ruptured PcomA aneurysm due to large aneurysmal neck with extension under anterior clinoid process and presence at the neck level of some perforating arteries led to the adoption of a strategy of neck reconstruction by partial clipping followed by coil endovascular occlusion.



**Figure 1** - Brain CT scan showing a subarachnoid hemorrhage



**Figure 2** - Angio CT scan A- antero-posterior and B – profile showing a complex PcomA aneurysm and a small AchA aneurysm



**Figure 3** - DSA - A showing the aneurysm neck clip reconstruction and remnant aneurysm; B - showing the complete coil occlusion of the aneurysm

Coil embolization was performed under general anesthesia five days later after clipping. Using Seldinger technique, 6F arterial sheaths were placed in the right femoral arteries. A 6F guiding catheter was placed in the internal carotid artery or dominant vertebral artery

providing arterial supply to the aneurysm remnant. Multiple biplane DSA series were performed in different degrees of obliquity for a clearly exposure of aneurysmal neck after reconstruction by clipping. Once an appropriate angle was obtained that optimally demonstrated the reconstructed neck of the aneurysm and its relationship to the parent vessel, a road-mapping acquisition was performed. An Excelsior SL-10 microcatheter was then advanced over a Transend 0.014 microguidewire under road-mapping guidance into the aneurysm remnant. Successive GDCs were then advanced and detached in the aneurysm remnant until it was totally angiographic occluded. A 1000 U of heparin was administered after first coil detachment. Once the aneurysm remnant was considered satisfactorily occluded, all catheters were removed through the femoral sheaths. The femoral sheaths were then removed from the femoral arteries and hemostasis was obtained by manual compression. Anticoagulation was continued 5 days with 0.6 ml daily. Control brain CT scan was achieved CT the day after the procedure.

### Discussions

Endovascular embolization with coils for treatment of cerebral aneurysm remnant after incomplete surgical clipping is generally followed by a favorable clinical outcome. A poor outcome is usually associated with a significant subarachnoid hemorrhage rebleeding and a short interval between clipping and endovascular coil occlusion. One explanation of this unfavorable outcome could be a severe medical condition of these patients

who require an urgent secondary treatment.

The aneurysm remnant after microsurgical clipping could have a technical or “anatomical” origin. The technical problems consisted in anatomical difficulties of complete neck clipping at the time of surgery or in slippage of a correct placed clip due to its manufacturing or sterilization problems. The “anatomical” origin could be explained by the regrowth of a new aneurysm lobe or initial aneurysm sac from a dysplastic or incomplete excluded neck.

Clearly highlighting these residues aneurysm can be achieved by postoperative angiographic exploration. This type of follow-up imaging is not the most common in specialized clinics. Thus, most often, aneurysm remnants are angiographic highlighted immediately postoperative

following a suspicion during surgery or a new rupture shortly after clipping. Also, in other cases, highlighting an aneurysmal remnant is an unexpected thing in a current angiographic exploration after an initial clipping considered successful. Given the above, we believe that postoperative angiographic imaging is indicated from time to time in case of suspected residual aneurysm, incomplete clipping of aneurysmal neck or in multiple aneurysms.

The aneurysm remnants after incompletely clipped aneurysm was a subject discussed extensively in the literature due to their catastrophic potential on patient quality of life. Table I summarized some literature reports concerning the recurrent hemorrhage after initial aneurysm surgery failure.

**TABLE I**

**Literature reports concerning the recurrent hemorrhage after initial aneurysm surgery failure**

Author, Year	Total number of treated aneurysm	Number of aneurysm with recurrent hemorrhage	Time Interval
Drake et al, 1984	115	24	2 wks – 10yrs
Feuerberg et al, 1987	715	2	4yrs – 13 yrs
Yamakawa et al, 1997	1436	27	4wks – 20yrs
Tsutsumi et al, 1998	220	6	3yrs – 17yrs
Wermer et al, 2005	752	18	10wks – 17yrs
<i>Chung et al, 2014</i>	312	4	2wks – 17 yrs

The endovascular coil occlusion is considered today in many neurosurgical centers as the first intended technique in the management of cerebral aneurysm. Some recent articles presented this technique as secondary treatment for complete occlusion of complex cerebral aneurysm. The main factors

mentioned in the literature as favoring the incomplete aneurysm occlusion are represented by a large neck, a large-giant sac, suboptimal aneurysm exposure (due to thrombosis or other anatomical particularities), a large infundibular collateral artery originating from aneurysm neck or sac.

Concerning the most frequently location of aneurysm with difficult occlusion the literature reports the deep midline aneurysm of the posterior circulation, anterior communicating artery and juxtaclinoid aneurysms (8.2% vs 0.6% other location). [2].

Both, microsurgical clipping and endovascular coil occlusion can be viewed within a single therapeutic strategy of combined approach. Their order of application will depend on a number of specific features of each case. Thus, microsurgical clipping can be also applied in case of an incomplete endovascular aneurysm occlusion with coils.

### Conclusions

Failure of aneurysm treatment failure represented by this remnant aneurysm can occur immediately postprocedural or after longer period of time especially for so-called complex aneurysms. Assuming a therapeutic strategy that integrates both interventional methods of microsurgical clipping and endovascular coils occlusion represent the optimal solution to prevent further complications and successful resolution of these cases.

### Correspondence

Stefan M. Iencean

“Gr. T. Popa” University of Medicine and Pharmacy, Iasi  
mirceasteffan@yahoo.com

### References

1. Forsting M1, Albert FK, Jansen O, von Kummer R, Aschoff A, Kunze S, Sartor K. (1996) Coil placement after clipping: endovascular treatment of incompletely clipped cerebral aneurysms. Report of two cases. *J Neurosurg*. Nov;85(5):966-9;
2. Mangiafico S., Cellerini M., Villa G., Ammannati F., Paoli L., Mennonna P. (2005) Endovascular Coiling of Aneurysm Remnants after Clipping in Patients with Follow-up A Single Center Experience, *Interventional Neuroradiology* 11: 41-48;
3. Choudhri, O., Mukerji, N., & Steinberg, G. K. (2013). Combined endovascular and microsurgical management of complex cerebral aneurysms. *Frontiers in neurology*, 4:1-11;
4. Michael T Lawton, Alfredo Quinones-Hinojosa, Nader Sanai, Junaid Y Malek, Christopher F Dowd (2003) Combined microsurgical and endovascular management of complex intracranial aneurysms. *Neurosurgery* 52(2):263-275;
5. Sung-Chul Jin, Do Hoon Kwon, Young Song, Hyun Jung Kim, Jae Seung Ahn, Byung-Duk Kwun (2008) Multimodal Treatment for Complex Intracranial Aneurysms : Clinical Research, *J Korean Neurosurg Soc* 44 : 314-319.