

Acute intracerebral haemorrhage complication after carotid artery stenting

A. Chiriac, Georgiana Ion*, N. Dobrin*, I. Poata

“Gr. T. Popa” University of Medicine and Pharmacy, Iasi

*“Prof. Dr. N. Oblu” Clinic Emergency Hospital, Iasi

Abstract: Intracranial hemorrhage following carotid artery stenting is a recognized rare complication but with potentially devastating evolution. Reports of acute cerebral hemorrhage injury following internal carotid artery (ICA) angioplasty are few, and usually were discussed in correlation with hyperperfusion syndrome. In this article we present a patient who experienced a fatal ipsilateral basal ganglia hemorrhage within 10 minutes after carotid angioplasty and stent placement.

Key words: carotid artery stent, cerebral hyperperfusion syndrome, acute intracranial hemorrhage.

Introduction

Improvements in endovascular techniques, especially in the emboli-prevention devices have significantly reduced the incidence of ischemic stroke following carotid artery stenting (CAS). In this condition intracerebral haemorrhage become the major complication following endovascular carotid artery revascularization. This complication was attributed to so called cerebral hyperperfusion syndrome.

The reported incidence of this phenomenon after endovascular carotid revascularization procedures remains questionable. However, first studies reported an incidence of 0.3–1.2% of cerebral hyperperfusion syndrome associated with

intracerebral haemorrhage after carotid angioplasty and stent placement, while more recent studies showed a relatively higher rate of up to 5% [1, 2, 3].

In this article we report two case of fatal intracerebral haemorrhage subsequent to carotid artery stenting after a time of 10 minutes and 30 minutes respectively.

Cases description

A 63-year-old man was referred for endovascular treatment after several transient ischemic attacks with left-side hemiparesis. The last episode occurred while the patient was undergoing medical treatment with 100mg acetylsalicylic acid and 75mg clopidogrel from 4 months. He had a long history of heavily smoke (3 packs / day) and

alcohol abuse. The patient presented vascular risk factors including peripheral arterial occlusive disease, chronic heart failure class II, obesity, hypertension and high blood cholesterol.

When assessed in our hospital 2 months later, his blood pressure was 150/90 mm Hg and he had mild left-side hemiparesis and vestibular syndrome. All haematological and biochemical tests were normal, with a normal platelet count and coagulation screen.

A native cranial CT performed at admission demonstrated old ischemic microvascular lesions on right hemisphere, cortical and subcortical general atrophy and moderate leukoaraiosis (Figure 1).

The patient underwent bilateral carotid color Doppler ultrasound that showed a severe stenosis of the right internal carotid artery (ICA) (Figure 2).

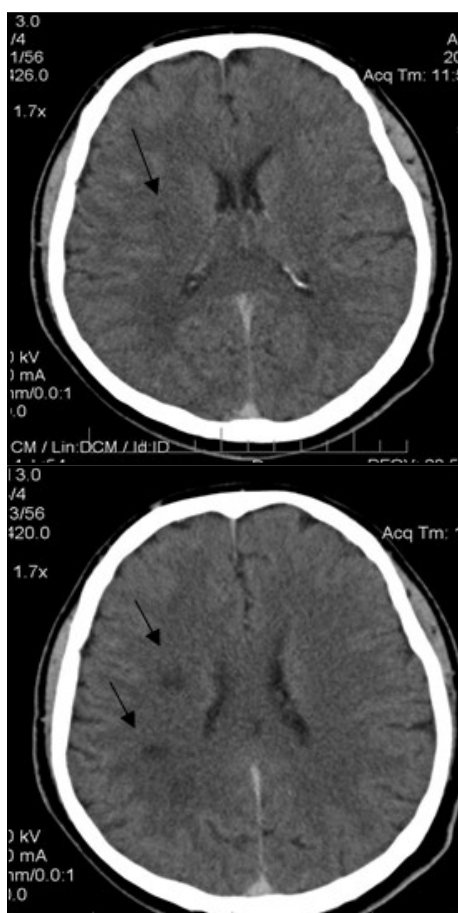


Figure 1 - Native cerebral CT scan showing old ischemic lesions

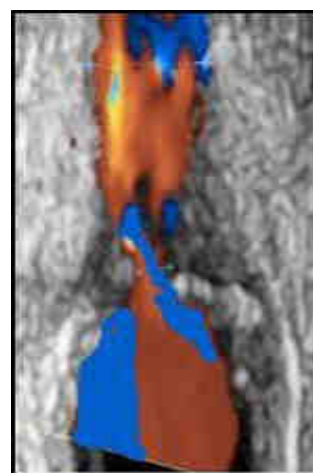


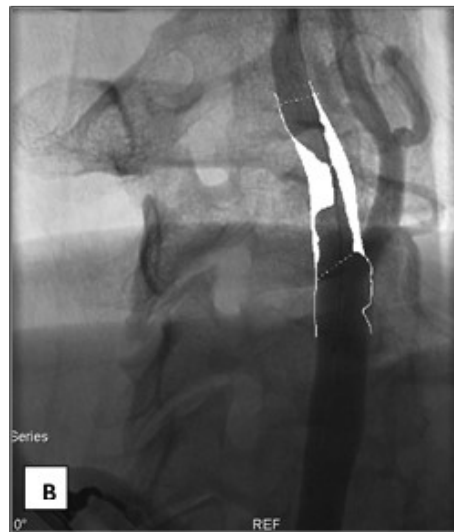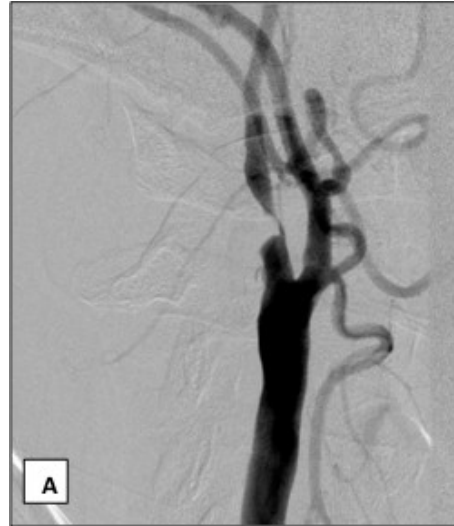Figure 2 - Color Doppler ultrasound showing a severe stenosis of the right ICA

The digital subtraction angiography performed next day via a femoral approach under local anesthesia confirmed 96% stenosis of right internal carotid artery (Figure 3). The patient has received a right carotid stenting procedure three days later. The procedure was performed with the patient under local anesthesia via an 8 F introducer sheath on right femoral artery. The patient was given 5000IU heparin and 0.5 mg atropine IV. An 8F Mach 1 Guide catheter (Boston Scientific) was positioned into the right common carotid

artery and the stenosis was crossed with a 0.010 Transend guidewire (Boston Scientific).

The stenosis was predilated with a Quantum Maverick 2x20 mm balloon (Boston Scientific) and stented with a 7/9/40 mm XACT Abbott stent. After placement of the stent, the residual stenosis was dilated with the use of a Maverick 5.5/20 mm balloon catheter (Boston Scientific). There were no procedural complications and blood pressure varied between 160/90 mm Hg and 180/105 mm Hg during the intervention.

Approximately 10 minutes after the intervention patient suddenly become very anxious and unexpressive. Then he developed a left-sided hemiplegia and become comatose. Blood pressure recorded was 200/110mmHg. Emergency unenhanced cranial CT showed a large right-sided intracranial hematoma affecting the basal ganglia and the thalamus (Figure 4). The patient was intubated and transferred to intensive care unit. Neurologic examination performed at 24 hours showed an unresponsive patient with dilated pupils and no reaction to painful stimuli. The patient died 3 days later.



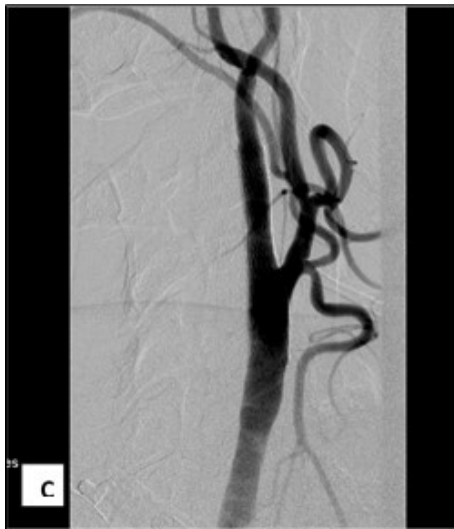

Figure 3 - A, B, C: DSA – Right ICA angioplasty

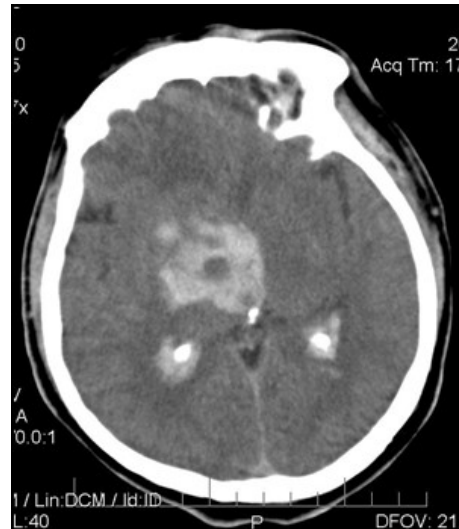
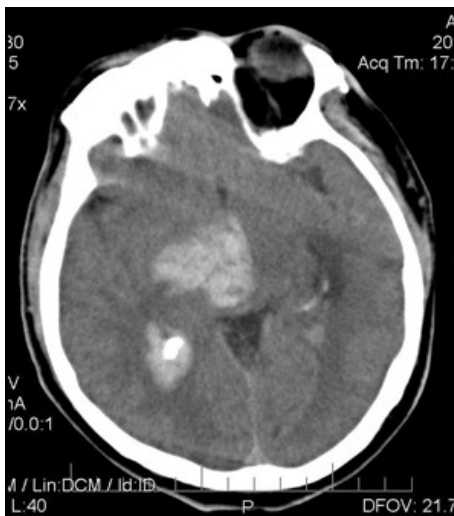

Figure 4 - A, B: Native CT showing a large right-sided intracranial hematoma



Discussions

Despite the increasing use of extracranial carotid artery stenting there are only few reports of “hyperperfusion injury” following this treatment in the literature to date.

Over time three different entities of hyperperfusion syndrome were differentiated in the literature. Thus, there were identified 2 early types and the so called “classic” delayed type. The “classic” hyperperfusion syndrome first described by Sundt and collaborators typically developed 5 to 7 days after carotid artery revascularization, in which the typically clinical presentation consist in frontotemporal or retro-orbital headache, nausea, vomiting, seizures and other neurologic signs of elevated brain pressure. Intracerebral hemorrhage is not an obligate component of this complication but can also occur [3].

The early types of hyperperfusion syndrome after carotid artery stenting were

first described by Coutts et al. The 2 early entities consist in acute focal edema usually characterized by a favorable outcome and acute intracerebral hemorrhage with often fatal outcome.

McCabe et al and Chamorro et al showed that the presence of cerebral microvascular changes like cerebral microangiopathy and insufficient intracranial collateralization signs represents possible risk factors for hyperacute intracerebral hemorrhage in patients with carotid artery stenting.

If in carotid endarterectomy occurrence of cerebral hyperperfusion injury were noted both in the presence of normal or elevated blood pressure, after carotid angioplasty these hemorrhagic complications has been usually associated with severe hypertension.

Most of the authors have reported increased velocity measurements on color doppler ultrasound in patent with stented internal carotid artery immediately after the procedure. One explanation of this phenomenon is that carotid sinus baroreceptors respond to the carotid blood flow by a corresponding decrease in systemic blood pressure. Thus, the increased cerebral perfusion pressure exceeds capacity arteriolar vasoconstriction and can lead to intracerebral hemorrhage [4].

Buhk and co-authors suggested that preinterventional highlighting of an acute infarct area is not necessarily a risk of hyperacute intracerebral hemorrhage after carotid angioplasty with stent. They have suggested that is a different cerebral hypoperfusion syndrome entity than described by Sundt et al, with different

pathophysiological mechanism that leads to hyperacute intracerebral hemorrhage [3].

Nearly all literature reports on acute intracerebral haemorrhage after carotid angioplasty with stent have in common patients who had high-grade stenoses in the treated vessel or contralateral occlusion or subocclusion statements.

Buhk et al have proposed a more differentiated view on the term hyperperfusion syndrome. Thus, the mechanism of parenchymal injury in patients with hyperacute intracerebral haemorrhage seems to be not hyperperfusion but rather blood pressure normalization [3].

Conclusions

Acute intracerebral hemorrhage is a serious complication of carotid revascularization by stent angioplasty. Even the pathological mechanism of this complication was usually attributed to impaired cerebral autoregulation or postoperatively elevated systemic blood pressure, the subject remain open to discussions. Clinical studies have identified potential risk factors of hemorrhagic complication for subgroups of patients with carotid stent angioplasty indication. Treatment strategies in these high-risk patients with severe vessel disease and high-grade stenosis must be directed towards regulation of blood pressure and limitation of rises in cerebral perfusion.

References

1. Yasuhiko Kaku, Shin-ichi Yoshimura, and Jouji Kokuzawa (2004) Factors Predictive of Cerebral

- Hyperperfusion after Carotid Angioplasty and Stent Placement, *Am J Neuroradiol* 25:1403–1408;
2. Solomon RA, Loftus CM, Quest DO, Correll JW. (1986) Incidence and etiology of intracerebral hemorrhage following carotid endarterectomy. *J Neurosurg*, 64:29–34;
 3. J.-H. Buhk, L. Cepek, M. Knauth (2006) Hyperacute Intracerebral Hemorrhage Complicating Carotid Stenting Should Be Distinguished from Hyperperfusion Syndrome. *Am J Neuroradiol* 27:1508 –13;
 4. DJH. McCabe, M. Brown, A. Clifton (1999) Fatal Cerebral Reperfusion Hemorrhage After Carotid Stenting, *Stroke*. 30:2483-2486;
 5. Choi BS, Park JW, Shin JE, Lu PH, Kim JK, Lee DH, et al. (2010) Outcome Evaluation of Carotid Stenting in High Risk Patients with Symptomatic Carotid Near Occlusion. *Interv Neuroradiol*, 16:309-16;
 6. Moulakakis KG, Mylonas SN, Sfyroeras GS, Andrikopoulos V. (2009) Hyperperfusion syndrome after carotid revascularization. *J Vasc Surg*. 49:1060-8;
 7. Goldberg JB, Goodney PP, Kumbhani SR, Roth RM, Powell RJ, Likosky DS. (2011) Brain Injury After Carotid Revascularisation: Outcomes, Mechanisms, and Opportunities for Improvement. *Ann Vasc Surg*. 25:270-86;
 8. Shindo A, Kawai N, Kawakita K, Kawanishi M, Tamiya T, Nagao S. (2007) Intracerebral Hemorrhage after Carotid Artery Stenting Without Evidence of Hyperperfusion in Positron Emission Tomography. *Interv Neurorad*. 13:191-9.