

Delayed deterioration following the evacuation of posterior fossa extradural hematoma

Amit Agrawal¹, S. Satish Kumar², Umamaheswara Reddy V.³

¹Professor of Neurosurgery, Department of Neurosurgery, Narayana Medical College Hospital, Chinthareddypalem, Nellore, Andhra Pradesh (India)

²Associate Professor of Emergency Medicine, Department of Emergency Medicine, Narayana Medical College Hospital, Chinthareddypalem, Nellore, Andhra Pradesh (India)

³Assistant Professor of Radiology, Department of Radiology, Narayana Medical College Hospital, Chinthareddypalem, Nellore, Andhra Pradesh (India)

Abstract: A missed or delayed detection of intracranial injuries can lead to progressive neuronal damage and secondary brain damage. We present a case of 45 year female presented 8 after the road traffic accident and had a large posterior extradural hematoma on left side with mass effect. In addition there was a small speck of right frontal contusion with localized cerebral edema. The patient initially improved after evacuation of the hematoma. However on 3rd post-operative day she was complaining of headache and became progressively drowsy. A follow up CT scan showed increase in peri-lesional edema around the right frontal contusion with squashing of the lateral ventricles suggestive of diffuse cerebral edema. The patient was shifted back to intensive care unit and responded well to further conservative management. In our patient the events could be collaborated well with existing evidence (presence of contrecoup contusion and on clinical deterioration at day 3).

Key words: Delayed deterioration, intracranial hematoma, clinical deterioration, epidural hematoma, posterior fossa.

Introduction

Posttraumatic posterior fossa extradural hematoma is complicates about 0.3% of all traumatic brain injuries and represents 4% to 12.9% of all extradural hematomas. (1-6) It is well known that a missed or delayed detection of intracranial injuries can lead to progressive neuronal damage and secondary brain damage

that can have a negative impact on the clinical outcome. (7) We describe a case of delayed deterioration following evacuation a large posterior fossa extradural hematoma and discuss the possible underlying for this delayed deterioration.

Case report

A 45 year female presented 8 after the road traffic accident. She was in altered sensorium since the time of injury. She had multiple episodes of vomiting. There was no history of ENT bleed or seizures. Her general and systemic examination was unremarkable. She was in altered sensorium (GCS-E2, V2, and M5). Pupils were bilateral equal and reacting to light. She was moving all four limbs equally. Computed tomography (CT) scan brain plain showed a large posterior extradural hematoma on left side with mass effect and distortion of the 4th ventricle (Figure 1).

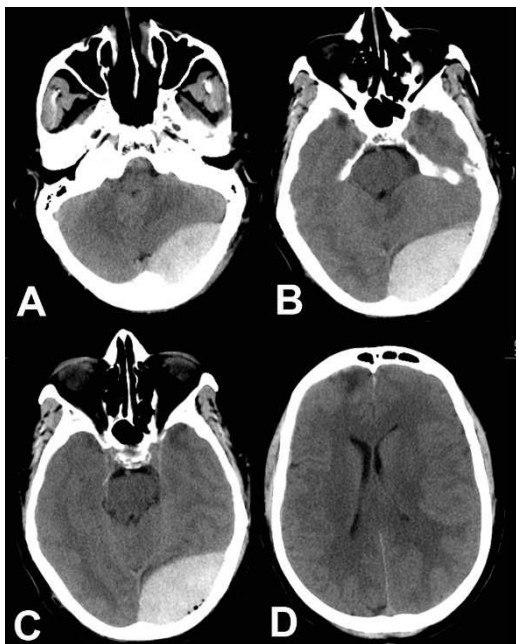

Figure 1 - Pre-operative CT scan brain plain showing a large posterior fossa extradural hematoma with mass effect and small speck of right frontal contusion (please note the small size and distortion of the fourth ventricle)

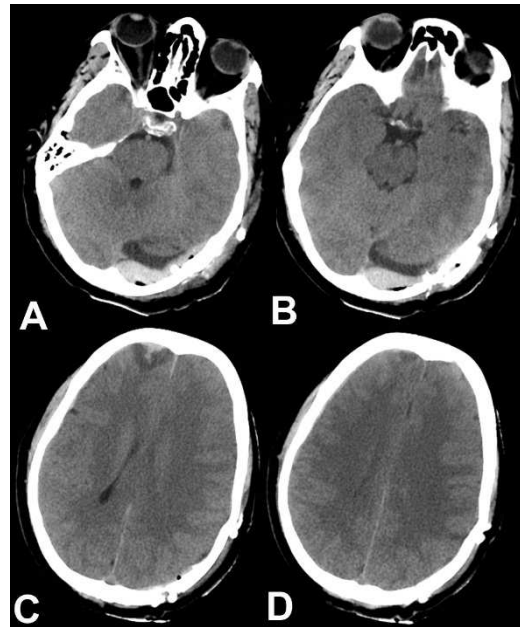


Figure 2 - Follow up CT scan performed day 3 after surgery showing good evacuation of extradural hematoma, 4th ventricle is opened, however there is increase in peri-lesional edema around frontal contusion and squashing of the lateral ventricles suggesting increase in cerebral edema

It also showed a small speck of right frontal contusion with localized cerebral edema. The patient was taken for emergency evacuation of the extradural hematoma. Following surgery she became conscious by next day morning. Her GCS was E4V5 and M6. There were no focal neurological deficits. In view of small speck of cerebral contusion she was started on anti-convulsants, however no anti-edema medications were given. She was apparently alright for two days after surgery and on day 3 she was complaining of headache and became progressively drowsy. There was no vomiting or fever. Her GCS was E1, V1 and M3. Pupils were bilateral equal and reacting. A follow CT

scan performed day 3 after surgery showing good evacuation of extradural hematoma, 4th ventricle is opened, however there was increase in peri-lesional edema around the right frontal contusion with squashing of the lateral ventricles suggestive of diffuse cerebral edema (Figure 2). The patient was shifted back to intensive care unit, in view of low GCS and respiratory distress endotracheal intubation was performed and she was kept on elective ventilation. She was started on anti-edema measures (injection Mannitol 100 ml intravenous 8 hourly). She responded well to this conservative management, could be weaned off from ventilator and recovered without any neurological deficits.

Discussion

It has been suggested that concurrent intracranial traumatic lesions which lead to increase in intracranial pressure provide a "protective mechanism" and as soon as this mechanism is withdrawn (either by the use of anti-edema measures or by evacuation of supratentorial mass lesions) it can result in delayed onset of EDH. (8-10) In contrast to this in present case the patient developed increase in the size of supratentorial lesions and there was increase in cerebral edema which resulted in clinical deterioration. Those patients who have associated intracranial injuries (i.e. a contrecoup injuries including subdural hemorrhage or traumatic subarachnoid hemorrhage) had a poor outcome. (11) Formation of cerebral edema is recognized as one of the major factors which can lead to high mortality following traumatic brain injury. (12) It has been shown that

delayed deterioration after EDH can result from progressive cerebral edema and ischemia. (13) There is considerable evidence that brain water content is maximal at 2-3 days after traumatic brain injury and it is also the point at which intracranial pressure is also usually at peak. (12, 14) In our patient the events can collaborated well with existing evidence (presence of contrecoup contusion and on clinical deterioration at day 3). It can be recommended patients showing multiple lesions should be carefully observed until their condition is stabilized. (15)

Correspondence

Dr. Amit Agrawal
Professor of Neurosurgery
Department of Neurosurgery
Narayana Medical College Hospital
Chinthareddypalem
Nellore-524003
Andhra Pradesh (India)
Email- dramitagrawal@gmail.com
dramit_in@yahoo.com
Mobile- +91-8096410032

References

1. Garza-Mercado R. Extradural hematoma of the posterior cranial fossa. Report of seven cases with survival. *Journal of neurosurgery* 1983;59:664-672.
2. Campbell E, Whitfield RD, Greenwood R. Extradural hematomas of the posterior fossa. *Annals of surgery* 1953;138:509-520.
3. Ammirati M, Tomita T. Posterior fossa epidural hematoma during childhood. *Neurosurgery* 1984;14:541-544.
4. Bozbuğa M, Izgi N, Polat G, Gürel I. Posterior fossa epidural hematomas: observations on a series of 73 cases. *Neurosurgical review* 1999;22:34-40.
5. Malik NK, Makhdoomi R, Indira B, Shankar S, Sastry K. Posterior fossa extradural hematoma: our experience and review of the literature. *Surgical neurology* 2007;68:155-

158; discussion 158.

6. Neubauer UJ. Extradural haematoma of the posterior fossa. Twelve years experiences with CT-scan. *Acta neurochirurgica* 1987;87:105-111.

7. Becker DP, Miller JD, Ward JD, Greenberg RP, Young HF, Sakalas R. The outcome from severe head injury with early diagnosis and intensive management. *Journal of neurosurgery* 1977;47:491-502.

8. Riesgo P, Piquer J, Botella C, Orozco M, Navarro J, Cabanes J. Delayed extradural hematoma after mild head injury: report of three cases. *Surgical neurology* 1997;48:226-231.

9. Su T-M, Lee T-H, Chen W-F, Lee T-C, Cheng C-H. Contralateral acute epidural hematoma after decompressive surgery of acute subdural hematoma: clinical features and outcome. *The Journal of trauma* 2008;65:1298-1302.

10. Thibodeau M, Melanson D, Ethier R. Acute epidural hematoma following decompressive surgery of a subdural

hematoma. *Canadian Association of Radiologists journal = Journal l'Association canadienne des radiologistes* 1987;38:52-53.

11. Jang JW, Lee JK, Seo BR, Kim SH. Traumatic epidural haematoma of the posterior cranial fossa. *British journal of neurosurgery* 2011;25:55-61.

12. Marmarou A. Pathophysiology of traumatic brain edema: current concepts. *Acta neurochirurgica Supplement* 2003;86:7-10.

13. Langfitt TW, Gennarelli TA. Can the outcome from head injury be improved? *Journal of neurosurgery* 1982;56:19-25.

14. Stocchetti N, Colombo A, Ortolano F, et al. Time course of intracranial hypertension after traumatic brain injury. *Journal of neurotrauma* 2007;24:1339-1346.

15. Takeuchi S, Wada K, Takasato Y, et al. Traumatic hematoma of the posterior fossa. *Acta neurochirurgica Supplement* 2013;118:135-138.