

## Temporal gliosarcoma: case report and review of literature

Amit Agrawal<sup>1</sup>, Vissa Shanthi<sup>2</sup>, Baddukonda Appala Ramakrishna<sup>3</sup>,  
Kuppili Venkata Murali Mohan<sup>3</sup>

<sup>1</sup>Professor of Neurosurgery, Department of Neurosurgery, Narayana Medical College Hospital, Chinthareddypalem, Nellore, Andhra Pradesh (India)

<sup>2</sup>Associate Professor of Pathology, Department of Pathology, Narayana Medical College Hospital, Chinthareddypalem, Nellore, Andhra Pradesh (India)

<sup>3</sup>Professor of Pathology, Department of Pathology, Narayana Medical College Hospital, Chinthareddypalem, Nellore, Andhra Pradesh (India)

**Abstract:** First characterized by Stroebe, the gliosarcomas are highly malignant and rare primary tumor of the brain composed of neoplastic glial cells in association with spindle cell sarcomatous elements (biphasic tissue patterns). In spite of being recognized as two different pathologies studies have not shown any significant differences between gliosarcoma and glioblastoma with regard to age, sex, size, clinical presentation, and median survival. In summary, gliosarcoma is an aggressive tumor with a propensity to recur and re-grow with poor outcome. Future studies are needed to understand the true pathology of these biphasic tumors.

**Key words:** Gliosarcoma, radiotherapy, survival, temporal gliosarcoma

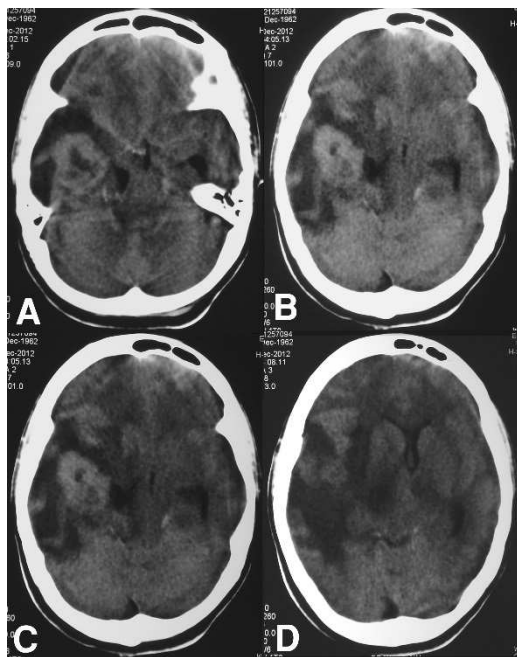
### Introduction

First characterized by Stroebe, (1) the gliosarcomas are highly malignant and rare primary tumor of the brain composed of neoplastic glial cells in association with spindle cell sarcomatous elements (biphasic tissue patterns). (1-9) World Health Organization characterizes primary gliosarcoma as a grade 4 neoplasm and a variant of glioblastoma multiforme (10, 11) and gliosarcomas have an incidence of 1.8%-2.8% of that of glioblastomas. (5, 12, 13)

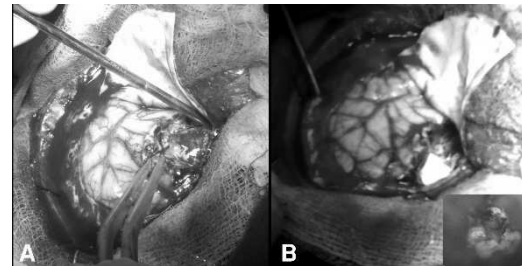
### Case report

A 50-year female presented with fever of 20 days duration, right sided headache and right hypochondrial pain of similar duration. She lapsed into altered sensorium three hours before presenting to emergency room and had two episodes of vomiting. She lapsed into altered sensorium after vomiting. Her general and systemic examination was unremarkable. Neurologically Glasgow coma scale (GCS) was E1V1M4, pupils were bilateral equal and reacting. She was moving all four limbs equally to deep painful stimuli. Pulse rate was

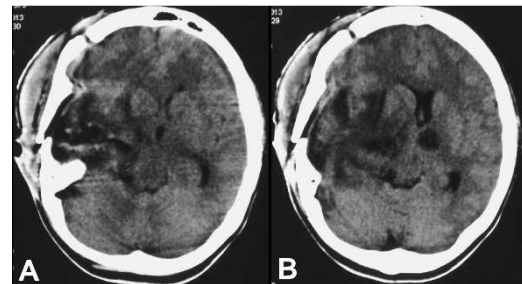
56 per minute regular. The patient was intubated in emergency and ventilated. Computerized scan (CT) of brain revealed a well-circumscribed heterogeneous iso- to hyperdense lesion in the right temporal lobe with significant peri-lesional edema, mass effect and midline shift (Figure 1). Total leucocytes count was 26,500 per mm<sup>3</sup> (N-86, L-09, E-01, 04. ESR was 36 mm in 1st hour. She was started on anti-edema measures. She underwent emergency right temporal craniotomy and total excision of the mass. The mass was avascular and firm to hard in consistency (Figure 2). Based on clinical features and intra-operative findings a diagnosis of tuberculoma was suspected.



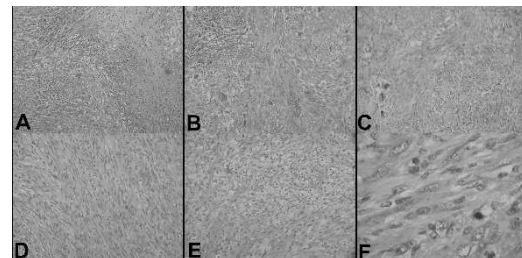
**Figure 1** - CT scan brain plain showing a heterogeneously lesion in the right temporal lobe with significant peri-lesional edema, mass effect and midline shift



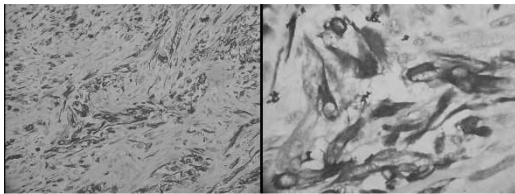
**Figure 2** - Intra-operative image showing (A) well defined mass lesion in right temporal lobe, (B) total excision of the mass (see inset)



**Figure 3** - Following up CT showing complete removal of the mass lesion



**Figure 4** - (A) Spindle shaped tumor cells with one foci showing necrosis and pseudopalisading pattern (H&E,X100), (B) Tumor with spindle shaped tumor cells, multinucleated tumor giant cells and congested blood vessels (H&E, X100), (C) Tumor with spindle shaped tumor cells and multinucleated tumor giant cells (H&E, X100), (D) Spindle shaped tumor cells (H&E,X100), (E) Tumor cells with vacuolated cytoplasm (H&E, X100) and (F) Spindle shaped tumor cells with vesicular nuclei, prominent nucleoli and an atypical mitotic figure (H&E, X400)



**Figure 5** - (A) Spindle shaped tumor cells positive for GFAP (GFAP, X100) and (B) Spindle shaped tumor cells positive for GFAP (GFAP, X400)

In addition to broad spectrum antibiotics she was stated on ATT. Postoperative CT showed total excision of the tumor and reduction in cerebral edema, mass effect and midline shift (Figure 3). Multiple section studies showed lesion composed of spindle shaped cells arranged in fascicles. In some foci they are arranged irregularly. The tumor cells are having oval elongated vesicular nuclei with prominent nucleoli and eosinophilic cytoplasm. In some foci tumor cells show vacuolated cytoplasm. Few foci show tumor cells having eccentrically placed nuclei with abundant eosinophilic cytoplasm. Mononucleated and multinucleated tumor giant cells are seen. Numerous atypical mitotic figures are noted. Occasional foci show necrosis and pseudo-palisading pattern of arrangement of tumor cells. Glial component was seen in some foci (Figures 4 and 5). The patient received radiotherapy and chemotherapy. She is doing well at follow up.

### Discussion

Gliosarcomas are usually located in the cerebral cortex (the temporal, frontal, parietal, and occipital lobes in decreasing frequency), most common in adults males in the fourth to sixth decades of life. (3, 5, 8, 12-16) Clinically

these patients present with features of raised intracranial pressure due to an expanding space occupying lesion (i.e. headache, hemiparesis, seizures, and cognitive decline). (15, 17) The pathogenesis of gliosarcoma has been a topic of controversy and various theories have been proposed (1) the sarcomatous component originates from neoplastic transformation of hyperplastic blood vessels found in high-grade glioma, and (2) the recent theory suggests monoclonal origin of sarcomatous component originating via aberrant mesenchymal differentiation of the malignant glioma. (15, 18-20) Histologically, the gliosarcoma is composed of 2 distinct malignant cell populations (biphasic tissue pattern), one component being gliomatous (heterogeneous infiltrative areas with hemorrhage and necrosis and stains for GFAP compatible with glioblastoma) and the other with malignant mesenchymal differentiation (a firm discrete mass compatible with sarcoma). Wrinkler, 2000 #179} (3, 19-23) The presence of identical genetic alterations in both gliomatous and sarcomatous components strongly supports monoclonal origin of gliosarcomas, however the absence of amplification/over expression of the EGFR gene, a genetic hallmark of primary glioblastomas. 24 Appearance of gliosarcoma on CT is extremely variable and these lesions generally appear as a well-defined hyperdense mass with heterogeneous or ring enhancement due to a fibrous component with intense peritumoral edema and necrotic areas. (13, 15, 25-28) On magnetic resonance imaging (MRI) gliosarcoma appear as a heterogeneous mass both in T1- and T2-

weighted images with irregular contrast enhancement with marked peritumoral edema (15, 25, 26) Management of gliosarcoma includes maximum surgical decompression with post-operative radiotherapy. (7, 9, 15, 29) The possible role of chemotherapy in GS is still undefined and could be explored in future studies. (7, 8, 13, 15, 20, 30) Metastases has been reported in up to one third of cases, mainly to the lungs, pleura, lymph nodes, bone marrow, liver, spinal cord, kidney and peripancreatic areas. (15, 17, 25) In spite of being recognized as two different pathologies studies have not shown any significant differences between gliosarcoma and glioblastoma with regard to age, sex, size, clinical presentation, and median survival. (3, 7, 8, 14-16, 19, 20, 31) The predominance of the sarcomatous component has been shown to be associated with a better prognosis and a greater recurrence-free interval. (19)

In summary, gliosarcoma is an aggressive tumor with a propensity to recur and re-grow with poor outcome. Future studies are needed to understand the true pathology of these biphasic tumors.

#### **Correspondence**

*Dr. Amit Agrawal*  
*Professor of Neurosurgery*  
*Department of Neurosurgery*  
*Narayana Medical College Hospital*  
*Chinthareddypalem*  
*Nellore-524003*  
*Andhra Pradesh (India)*  
*Email- dramitagrawal@gmail.com*  
*dramit\_in@yahoo.com*  
*Mobile- +91-8096410032*

#### **References**

1. Stroebe H, Stupp R, Mason WP, Bent MJ. Uber Entstehung und Bau der Gehirngliome. Beitr Pathol Anat Allg Pathol Van den Radioth 1895;18 SRC - GoogleScholar:405-485.
2. Feigin I, Gross SW, J, Fischer S, Lee W, Aulisi E. Sarcoma arising in glioblastoma of the brain. Am PMCID PMC557 PubMed 14388124 1942;31 SRC - GoogleScholar:633-653.
3. Morantz RA, Feigin I, Ransohoff J. Clinical and pathological study of 24 cases of gliosarcoma. Journal of neurosurgery 1976;45:398-408.
4. Goldstein SJ, Young B, Markesberry WR. Congenital malignant gliosarcoma. AJNR American journal of neuroradiology 1981;2:475-476.
5. Parekh HC, O'Donovan DG, Sharma RR, Keogh AJ. Primary cerebral gliosarcoma: report of 17 cases. British journal of neurosurgery 1995;9:171-178.
6. Güney Y, Hiçsönmez A, Yılmaz S, Adas YG, Andrieu MN. Gliosarcoma: a study of four cases. Rare tumors 2010;2.
7. Kumar P, Singh S, Kumar P, Krishnani N, Datta NR. Gliosarcoma: an audit from a single institution in India of 24 post-irradiated cases over 15 years. Journal of cancer research and therapeutics 2008;4:164-168.
8. Meis JM, Martz KL, Nelson JS. Mixed glioblastoma multiforme and sarcoma. A clinicopathologic study of 26 radiation therapy oncology group cases. Cancer 1991;67:2342-2349.
9. BASMACI M, HASTURK AE, AYATA T, CANBAY S, COBANOGLU M. Primary Gliosarcoma: Clinical and Pathological Evaluation of Four Cases. Journal of Neurological Sciences (Turkish) 2011;28:402-409.
10. Louis DN, Ohgaki H, Wiestler OD, et al. The 2007 WHO classification of tumours of the central nervous system. Acta neuropathologica 2007;114:97-109.
11. Kleihues P, Cavenee WK. Pathology and genetics of tumours of the nervous system: International Agency for Research on Cancer, 2000.
12. Lutterbach J, Guttenberger R, Pagenstecher A. Gliosarcoma: a clinical study. Radiotherapy and oncology : journal of the European Society for Therapeutic Radiology and Oncology 2001;61:57-64.
13. Okami N, Kawamata T, Kubo O, Yamane F, Kawamura H, Hori T. Infantile gliosarcoma: a case and a review of the literature. Child's nervous system : ChNS :

official journal of the International Society for Pediatric Neurosurgery 2002;18:351-355.

14.Galanis E, Buckner JC, Dinapoli RP, et al. Clinical outcome of gliosarcoma compared with glioblastoma multiforme: North Central Cancer Treatment Group results. *Journal of neurosurgery* 1998;89:425-430.

15.Han SJ, Yang I, Tihan T, Prados MD, Parsa AT. Primary gliosarcoma: key clinical and pathologic distinctions from glioblastoma with implications as a unique oncologic entity. *Journal of neuro-oncology* 2010;96:313-320.

16.Kozak KR, Mahadevan A, Moody JS. Adult gliosarcoma: epidemiology, natural history, and factors associated with outcome. *Neuro-oncology* 2009;11:183-191.

17.Witwer BP, Salamat MS, Resnick DK. Gliosarcoma metastatic to the cervical spinal cord: case report and review of the literature. *Surgical neurology* 2000;54:373-378; discussion 378.

18.Boerman RH, Anderl K, Herath J, et al. The glial and mesenchymal elements of gliosarcomas share similar genetic alterations. *Journal of neuropathology and experimental neurology* 1996;55:973-981.

19.Salvati M, Caroli E, Raco A, Giangaspero F, Delfini R, Ferrante L. Gliosarcomas: analysis of 11 cases do two subtypes exist? *Journal of neuro-oncology* 2005;74:59-63.

20.Winkler PA, Büttner A, Tomezzoli A, Weis S. Histologically repeatedly confirmed gliosarcoma with long survival: review of the literature and report of a case. *Acta neurochirurgica* 2000;142:91-95.

21.Koul R, Tai P, Dubey A. Five Patients with Gliosarcoma. *J HK Coll Radiol* 2008;11:116-121.

22.Borota OC, Scheie D, Bjerkhagen B, Jacobsen EA, Skullerud K. Gliosarcoma with liposarcomatous component, bone infiltration and extracranial growth. *Clinical neuropathology* 2006;25:200-203.

23.Sarkar C, Sharma MC, Sudha K, Gaikwad S, Varma A.

A clinico-pathological study of 29 cases of gliosarcoma with special reference to two unique variants. *The Indian journal of medical research* 1997;106:229-235.

24.Reis RM, Könü-Lebleblicioglu D, Lopes JM, Kleihues P, Ohgaki H. Genetic profile of gliosarcomas. *The American journal of pathology* 2000;156:425-432.

25.Moreira JN, Gaspar R. Antagonist G-mediated targeting and cytotoxicity of liposomal doxorubicin in NCI-H82 variant small cell lung cancer. *Brazilian journal of medical and biological research = Revista brasileira de pesquisas medicas e biologicas / Sociedade Brasileira de Biofisica [et al]* 2004;37:1185-1192.

26.Alataakis S, Stuckey S, Siu K, McLean C. Gliosarcoma with osteosarcomatous differentiation: review of radiological and pathological features. *Journal of clinical neuroscience : official journal of the Neurosurgical Society of Australasia* 2004;11:650-656.

27.Nitta H, Hayase H, Moriyama Y, Yamashita T, Yamashita J. Gliosarcoma of the posterior cranial fossa: MRI findings. *Neuroradiology* 1993;35:279-280.

28.Rees JH, Smirniotopoulos JG, Jones RV, Wong K. Glioblastoma multiforme: radiologic-pathologic correlation. *Radiographics : a review publication of the Radiological Society of North America, Inc* 1996;16:1413-1438; quiz 1462.

29.Maeda D, Miyazawa T, Toyooka T, Shima K. Temporal gliosarcoma with extraneural metastasis: case report. *Neurologia medico-chirurgica* 2010;50:343-345.

30.Balasubramaniam S, Tyagi DK, Sawant HV, Epari S. Posterior fossa involvement in a recurrent gliosarcoma. *Journal of neurosciences in rural practice* 2012;3:60-64.

31.Hasegawa T, Yamamoto S, Yokoyama R, Umeda T, Matsuno Y, Hirohashi S. Prognostic significance of grading and staging systems using MIB-1 score in adult patients with soft tissue sarcoma of the extremities and trunk. *Cancer* 2002;95:843-851.