

## Surgery of petroclival meningiomas. Recent surgical results and outcomes

Mugurel Radoi<sup>1</sup>, Florin Stefanescu<sup>1</sup>, Ram Vakilnejad<sup>2</sup>,  
Lidia Gheorghitescu<sup>2</sup>, Daniela Rosu<sup>2</sup>

<sup>1</sup>UMF "Carol Davila" Bucharest; Neurosurgical Department of the National Institute of Neurology and Neurovascular Diseases – Bucharest

<sup>2</sup>Neurosurgical Department of the National Institute of Neurology and Neurovascular Diseases - Bucharest

**Abstract:** Petroclival meningiomas represent only 10% of all meningiomas located in the posterior fossa, but are some of the most formidable challenges in skull base surgery. We described our recent experience (2005-September2014) regarding the surgery of these tumors. We retrospectively analyzed surgical results and outcome in 11 cases of petroclival meningiomas. Most common symptoms in our series were headache and gait disturbance, while cranial nerves palsies represented the most common presenting signs. There were 8 females and 3 males, and the mean age was 52 years. Surgical approaches chosen for petroclival meningiomas in our series were retrosigmoid (9 patients) and subtemporal transtentorial (2 patients). We achieved total tumor resection in 5 cases (45%) and subtotal resection in 6 cases (55%). Overall outcome (total/subtotal resection) was good in 6 cases, fair in 3 cases and poor in one case. One postoperative death occurred due to hemorrhagic midbrain infarction (9%). Complications were usually related to cranial nerve deficits: loss of hearing (2 patients), paresis of trochlear nerve (1 patient), trigeminal nerve (3 patients) and facial nerve (1 patient). In 4 patients these cranial nerves deficits were transient. In one case, a patient developed postoperative hydrocephalus and needed shunt placement. Despite the fact that complications can be disastrous, we considered that an appropriate approach, combined with microsurgical techniques and a better understanding of the anatomy, greatly decrease the incidence and severity of complications and make feasible a total tumor resection.

**Key words:** petroclival meningiomas, surgery, retrosigmoid approach, subtemporal approach, outcome

### Introduction

Of the meningioma of the basal posterior cranial fossa, petroclival meningiomas offer

the greatest technical challenge to the neurosurgeon, because of their proximity to the brain stem, cranial nerves III to XII, and

arteries of the posterior circulation. On autopsy, based on the site of their dural attachment, Castellano and Ruggiero classified meningiomas of the posterior fossa into five groups: cerebellar convexity, tentorium, posterior surface of the petrous bone, clivus and foramen magnum (4). Based on intraoperative observations, Yasargil et al. differentiated the posterior fossa meningiomas in clival (medial origin), petroclival (origin at the petrous tip, medial to the V nerve), sphenopetroclival (origin at Meckel's cave), foramen magnum and cerebellopontine angle (22). Currently, the differentiation between clival, petroclival and sphenopetroclival meningiomas is based on natural history and surgical anatomy (1, 5, 6, 12). Al-Mefty and Smith (2) emphasized that only those meningiomas arising medial to the trigeminal nerve should be included in the petroclival group to differentiate them from those arising more laterally; the latter may be included in the broad family of cerebellopontine angle meningiomas, which are easily removed. A more recent petroclival meningiomas classification was proposed by Kawase in 1996 (10), according to the main attachment and trigeminal nerve deviation: upper clivus, cavernous sinus, tentorium and petrous apex meningiomas. In this study, we described our recent experience (2005-September 2014) regarding the surgery of these tumors.

### **Material and methods**

We reported our experience referring on eleven consecutive cases of petroclival meningiomas operated in our department in the last ten years. We performed a

retrospective review analyzing clinical and imaging data, surgical records, postoperative results and follow-up records. There were 8 females and 3 males in this series and the mean age was 52 years. Preoperative clinical signs were as follows: headache (82%), cerebellar signs (63.6%), pyramidal signs (45.45%), facial pain (27.3%), facial numbness (45.45%), facial paresis (27.3%), hearing disturbances (54.54%), diplopia (27.3%) and lower cranial nerve dysfunction (18.2%). As preoperative evaluation, patients performed contrast cerebral tomography (CT), magnetic resonance imaging (MRI) with or without gadolinium enhancement, and, in selected cases, cerebral angiography. Imaging studies showed exact location and extent of the tumor, relationship to the surrounding neural structures (brain stem and cranial nerves) and possible encasement of cerebral vessels.

There were 4 sphenopetroclival meningiomas and 7 petroclival meningiomas. All patients were treated surgically in one single operation. Main aspects when choosing the surgical approach were goals of resection and extent of basal attachment (supra and/or infratentorial). In this series, most suitable and familiar approaches were chosen for surgical resection of meningiomas. A retrosigmoid approach was performed in 9 patients, while subtemporal transtentorial approach was suitable for 2 patients.

Degree of tumor extension was assessed by Simpson grading scale for meningiomas. Functional status was determined using Karnofsky Performance Scale (KPS). Mean follow-up was 38 months (range 10 to 64 mo).

**Results**

There were 4 (36.37%) sphenopetroclival meningiomas and 7 (63.67%) petroclival meningiomas. We achieved total resection of the meningioma in 5 cases (45%) and subtotal resection in 6 cases (55%). Macroscopically complete removal of the petroclival meningioma, Simpson grade I to III, was achieved in 5 out of 11 cases, as follows: grade I – 1 patient, grade II – 3 patients and grade III – 1 patient (Table 1). In the rest of 6 patients, a partial removal of the meningioma was performed (Simpson grade IV).

Most frequently encountered early surgical complication were related to cranial nerve paresis (ophthalmic paresis, facial paresis, hearing loss and IX, X cranial nerve deficits). Most of them were transitory (Table 2).

**TABLE 1**

**Grade of tumoral resection in our series**

Meningioma extension	Surgical removal		Total
	Total	Subtotal	
<i>Sphenopetroclival</i>	2 (50%)	2 (50%)	4 (36.37%)
<i>Petroclival</i>	3 (43%)	4 (57%)	7 (63.67%)
<i>Clival</i>	0	0	0
<b>Total</b>	5 (45%)	6 (55%)	11 (100%)

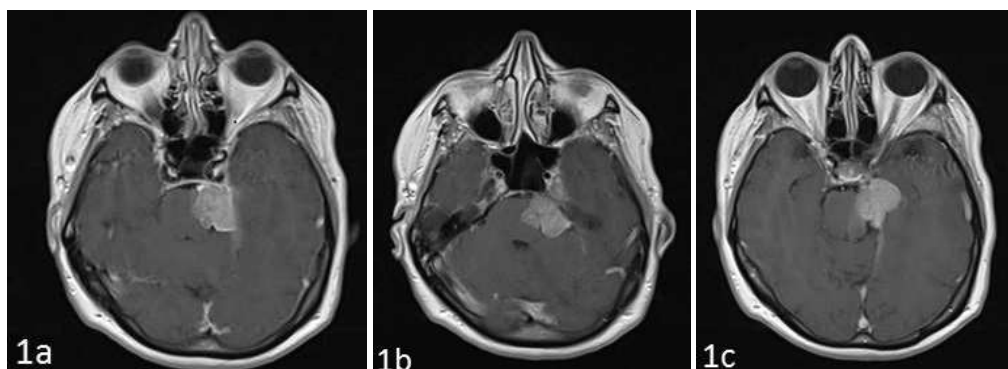
**TABLE 2**

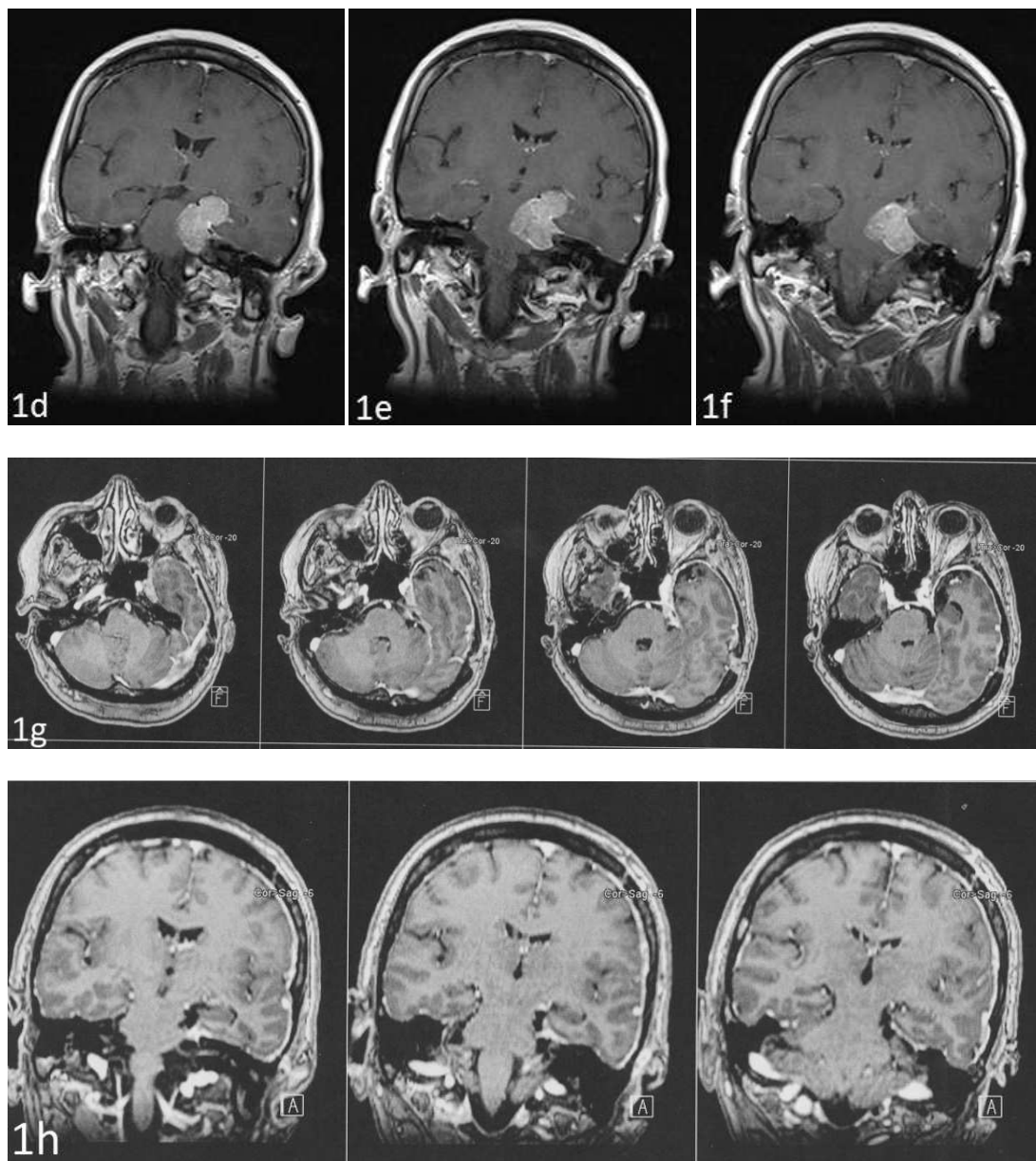
**Surgical related complications in our series**

Surgical related complication	Early	Late
<i>Ophthalmic paresis</i>	4	1 (n. IV)
<i>Facial paresis</i>	4	1
<i>Hearing loss</i>	2	2
<i>Lower cranial nerve deficits</i>	3	1
<i>Worsening of motor deficits</i>	2	1
<i>Newly motor deficits</i>	2	1
<i>Ataxia</i>	1	0
<i>Hydrocephalus (VP shunt)</i>	1	1
<i>Local CSF leak</i>	1	0
<i>Meningitis</i>	0	0
<b>Total</b>	21	9

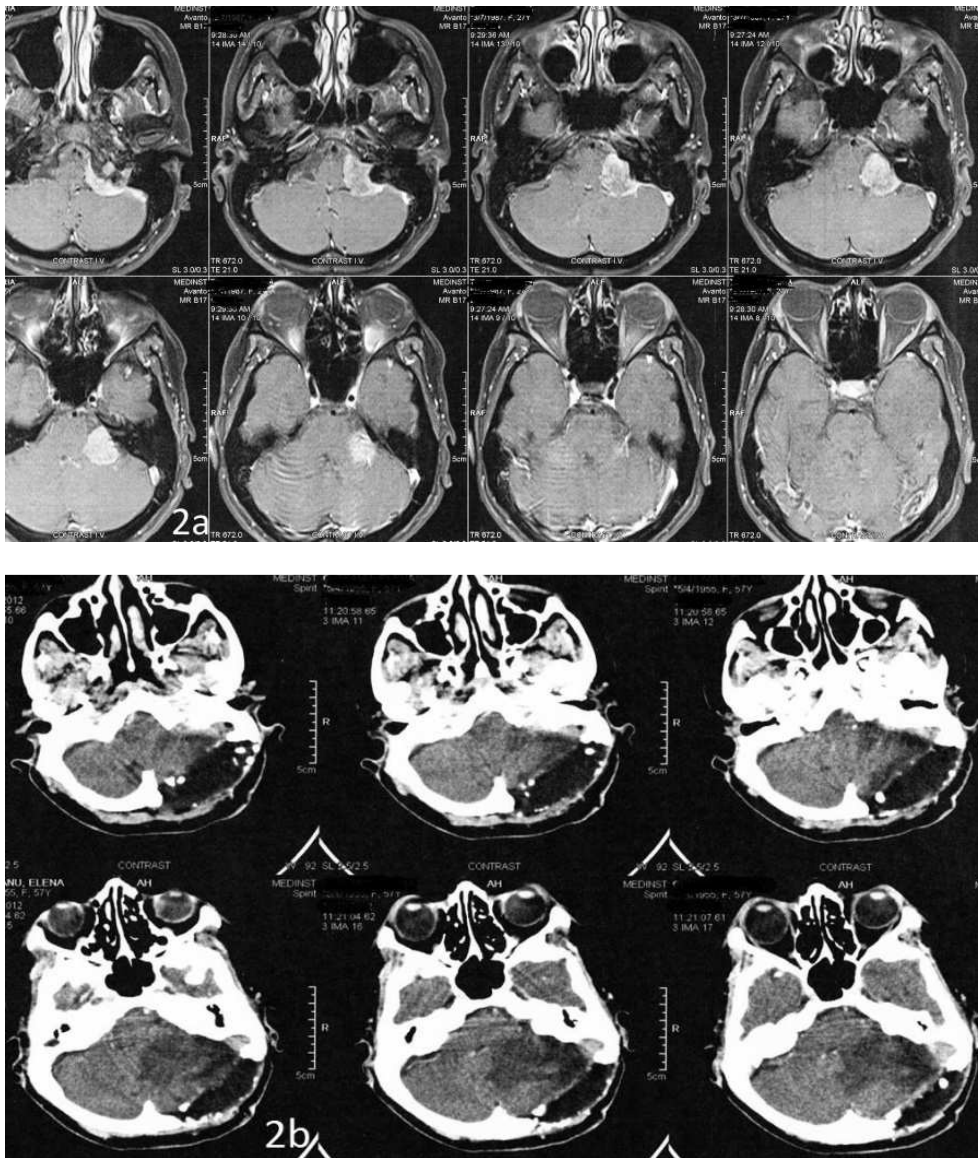
Postoperative hydrocephalus needing ventriculo-peritoneal shunt was encountered in one patient.

There was one death recorded, in the 5th postoperative day, due to an important hemorrhagic midbrain infarction. According to Karnofsky Performance Scale (KPS), in our series, postoperative results were good in 7 (63.64%) patients (KPS 80-100; patient is independent), poor in 2 (18.2%) patients (KPS 50-70; patient requires assistance) and very poor in 1 (9%) patient (KPS 30-40; patient severely disabled).

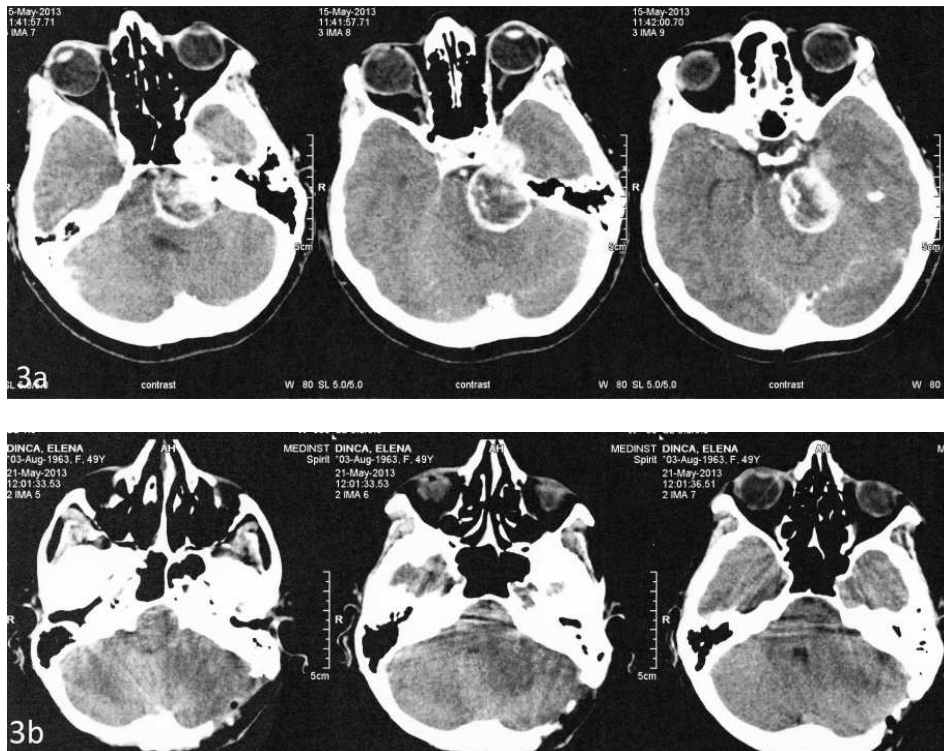




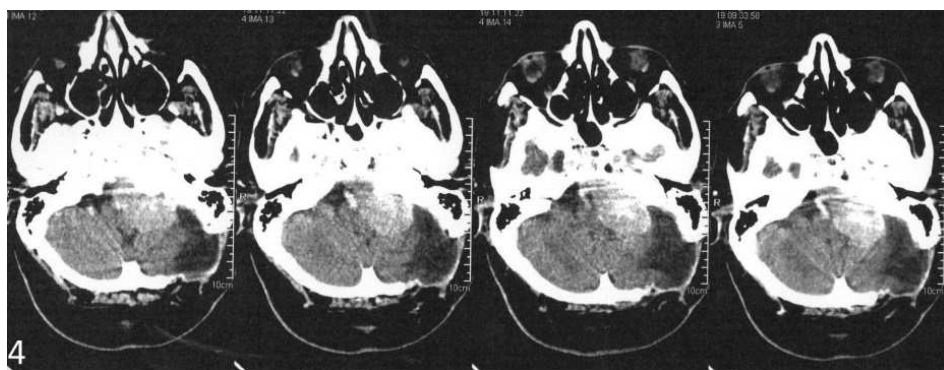
**Figure 1** - (a, b, c, d, e, f) Preoperative axial and coronal gadolinium enhanced MRI images of a 52 years old female with a sphenopetroclival meningioma, admitted with 6th cranial nerve palsy and left trigeminal neuralgia; (g, h) postoperative axial and coronal gadolinium enhanced MRI images after total resection of the meningioma through a subtemporal approach with minimal incision of the tentorium



**Figure 2** - (a) Preoperative axial gadolinium enhanced MRI images of a 43 years old female with petroclival meningioma, admitted with headache, facial numbness and hearing disturbances; (b) postoperative contrast cerebral CT scan showing complete microsurgical resection of the meningioma



**Figure 3** – (a) Preoperative contrast cerebral CT scan showed a petroclival tumor, in a 60 years old female admitted with headache, ataxia, left facial numbness and hearing disturbances; (b) – postoperative contrast cerebral CT scan showed complete microsurgical resection of the tumor (histological result – trigeminal schwannoma)



**Figure 4** – Incomplete resection of a left petroclival meningioma in a 69 years old male. He was admitted with facial paresis, mild lower cranial nerves dysfunction, right hemiparesis and ataxia. We performed a subtotal resection through a left retrosigmoid approach; at 40 months follow-up control, he presented with hydrocephalus, but refused surgical treatment

## Discussion

Clival meningiomas arise from the superior two-thirds of the clivus and displaced the brainstem and basilar artery posteriorly. Petroclival meningiomas are located along the superior two-thirds of the clivus and medial to the fifth cranial nerve; they displaced the brain stem and the basilar artery to the contralateral side (22). The sphenopetroclival meningiomas also arise along the spheno-occipital synchondrosis and displace the brain stem to the contralateral side; these tumors extend into the supratentorial compartment typically invading the lateral wall of the cavernous sinus (13).

Detailed preoperative radiologic work-up of a patient with petroclival meningioma is essential. Magnetic resonance imaging (MRI) with contrast enhancement provide information about exact location and extent of the meningioma, relationship to the surrounding neural structures (brain stem and cranial nerves), the possible encasement of cerebral vessels and any involvement of the cavernous sinus and temporal bone. Cerebral angiography with visualization of the both carotid and vertebral circulation is a very important component of the preoperative plan. It demonstrates the blood supply of the meningioma and its angiographic relation with the basilar artery (frequently the basilar artery is pushed posteriorly and to one side), and the posterior cerebral and superior cerebellar arteries, which are usually elevated on the same side of the tumor (8).

Such tumors, often wedge in the brain stem, may encase cranial nerves and basilar and carotid arteries and their roots, perforate

the dura, and invade the underlying bone (Table 3 and Table 4) (3). Advances in microsurgery and approaches to the skull base have made their removal easier and less conducive to iatrogenic damage. Surgical morbidity remains consistent in all contemporary published series (17, 21, 23), and in clinical reality there are still a number of patients, operated for this type of meningiomas, that are not satisfied with the "outcome and surgeon's performance". For the neurosurgeon there are two main aspects to consider: (a) – the tumor is benign and cause relative mild neurological symptoms with which the patient can learn to live and (b) – for their removal major surgery is required, with risk that the patient will be neurologically worse after surgery. (3).

In surgery of petroclival meningiomas, bone removal may be necessary to facilitate medial exposure and minimize retraction of neural structures. More medial meningioma's attachment, more lateral the bone removal is necessary for exposure. The best surgical approach is that which expose and enable immediate interruption of the tumor blood supply at the base of the skull (6). Extension beyond the tentorial hiatus needs supratentorial exposure.

We sustain that the best treatment for petroclival meningioma is trying to perform a radical surgical removal during the first operation. When subtotal removal of the meningioma must be accepted, a good outcome may still result, because these are slow-growing tumors, allowing the patient to have a functional survival.

**TABLE 3**  
**Position of the cranial nerves in posterior skull base meningiomas**

Meningiomas	Cranial nerves					
	III	IV	V	VI	VII,VIII	IX,X,XI
<i>Petroclival</i>	Superior Medial	Superior Lateral	Posterior Superior	Medial Anterior	Posterior	Inferior Posterior
<i>Anterior petrous</i>	Medial Superior	Superior Medial	Anterior Medial	Medial Anterior	Posterior Inferior	Inferior
<i>Posterior petrous</i>	-	-	Anterior	Anterior	Anterior	Anterior Inferior
<i>Jugular foramen</i>	-	-	-	Medial	Superior	Posterior Lateral
<i>Foramen magnum</i>	-	-	-	Posterior	Superior Posterior	Posterior Superior

(Bricolo A, Turazzi S. Petroclival meningiomas. In Schmidek and Sweet (ed): Operative Neurosurgical Techniques. New York: W.B. Saunders Company, 2000, pp. 932-955) (3)

**TABLE 4**  
**Position of the arteries in posterior skull base meningiomas**

Meningioma	Posterior cerebral artery	Superior cerebellar artery	Basilar artery	AICA	PICA	Vertebral artery
<i>Petroclival</i>	Superior Medial	Superior Medial	Posterior Medial	Posterior Medial	Posterior Inferior	Posterior Inferior
<i>Anterior petrous</i>	Superior Medial	Medial	Medial	Anterior Medial	Inferior Medial	Medial
<i>Posterior petrous</i>	-	-	Anterior Medial	Anterior	Anterior	Anterior Medial
<i>Jugular foramen</i>	-	-	Medial	Superior	Inferior	Medial Inferior
<i>Foramen magnum</i>	-	-	-	Superior	Posterior	Posterior Lateral

AICA – anterior inferior cerebellar artery; PICA – posterior inferior cerebellar artery (Bricolo A, Turazzi S. Petroclival meningiomas. In Schmidek and Sweet (ed): Operative Neurosurgical Techniques. New York: W.B. Saunders Company, 2000, pp. 932-955) (3)

In elderly patients, small and asymptomatic meningiomas can be observed and followed with neurologic exams and MRIs. Various approaches have been used to resect these meningiomas. Most common of them are frontotemporal transsylvian (pterional) or subtemporal, posterior transcaavernous (with removal of the petrous



apex), transtemporal approaches (presigmoid or transsigmoid retrolabyrinthine, translabyrinthine and transcochlear), retrosigmoid and petrosal approach (7, 14, 18). When choosing a surgical approach the following must be taken into consideration: (a) location of skull base attachment (upper/mid/lower clivus and medial/lateral), (b) extent of basal attachment (eg. supra/infratentorial), (c) preoperative cranial neuropathies (especially status of hearing) and (d) goals of resection. (6). For the most of our cases, we chose retrosigmoid craniotomy which is simple and rapid to perform offers access primarily to the midclival region and is well suited for tumors that are more laterally situated with a limited area of dural attachment. In two cases, with supratentorial extension of the tumor involving the internal carotid artery, we performed a frontotemporal craniotomy with wide splitting of the Sylvian fissure, which offered access to the dorsum sellae and posterior clinoid region.

In 1977, Hakuba et al. (7), reviewing the neurosurgical literature found 44 cases of petroclival meningiomas, of which 31 had been treated surgically: total removal was achieved in only 3 patients, and 17 died within the first month of the postoperative period. In his personal series, Hakuba had six cases of total removal and only one death. Their results represented a turning-point in the use of surgery for these formidable lesions (7). In 1980, on a series of 20 cases of clival meningiomas, Yasargil et al.(22) reported better results. There were 7 patients with total resection, and the outcome were good (self-supporting and working) in five and fair in

two. Of the 13 subtotal resection, the outcome were good (fully employable) in six cases, fair in three cases, poor in two cases, with two mortalities (22). In 1991, Kawase et al. reported on a series of ten patients with sphenopetroclival meningiomas on whom they used the anterior transpetrosal-transtentorial approach; total resection was achieved in 7 patients with no postoperative mortality (11). Based on a series of 52 patients with petroclival meningiomas, Sekhar and Javid (9) reported in 1991 their results using a variety of skull base approaches. They achieved total tumor resection in 38 cases (73%), subtotal resection in 11 (21%), and partial resection in 3 (6%) with 2 postoperative mortalities. In 1992, Samii and Tatagiba reported successful total removal in 27 (75%) of the 36 patients with petroclival meningiomas on whom they operated between 1978 and 1990; they had no postoperative death, and in 83%, no severe morbidity (16). More recent series have also reported zero mortality (1, 19, 20, 23). The reported rate of total tumor resection has increased from a low 25% up to 86% (1, 14, 20, 22). In our series, of 11 cases of petroclival meningioma, total resection was achieved in 5 patients (45%). Good results were obtained in 7 (63.64%) patients (self-supporting), fair in 2 (18.2%) patients (require assistance), and very poor in 1 (9%) patient (severely disabled).

Complication related to surgical management of petroclival meningiomas remains as high as 50% and usually are related to cranial nerve deficits that are transient in the majority of cases (1, 15, 19, 20, 22). The most serious complications are related to brain

stem injury, which is very severe and is usually due to compromise of the blood supply to the brain stem (1, 15, 22). In the most recent series, these complications have decreased due to the use of microsurgical techniques and a better understanding of the anatomic behavior of these tumors (20). Depending on the size of the petroclival meningioma, any of the cranial nerves can be injured during surgery in a retrosigmoid approach (17). The trochlear nerve can be injured because of its softness, especially in its subarachnoid course in the ambient cistern (18). Complete injury to the trigeminal nerve is less frequent due to its large size, but a trigeminal nerve paresis is a frequent occurrence. Because the facial nerve is usually displaced posteriorly by the tumor, it is injured especially in large size petroclival meningioma (17, 18, 20). Loss of hearing is common with patients with petroclival meningiomas. If the hearing is normal, it is very important to use the appropriate approaches to preserve this function. Injury to the vagus or glossopharyngeal nerves leads to significant compromise in the cough and gag reflex, and, as a result, serious pulmonary complications (13, 20). In our series, the mortality rate was 9% (1 patient) due to hemorrhagic midbrain infarction. Paresis of the ophthalmic and facial nerve were the most frequent encountered (36,4%), but only 9% of patients presented permanent deficits.

### Conclusions

Many surgical approaches have been advocated for complete resection of petroclival meningiomas. For each case, planning the safest approach should be sustained on: goals

of resection, location and extent of basal attachment, preoperative cranial neuropathies. Despite the fact that complications can be disastrous, we considered that an appropriate approach, combined with microsurgical techniques and a better understanding of the anatomy, greatly decrease the incidence and severity of complications and make feasible a total tumor resection. The conventional and easy suboccipital retrosigmoid approach is suitable for total removal of petroclival meningiomas, and, in selected cases, a combined, supra-/infratentorial approach can be chose.

### Correspondence

*Mugurel Radoi*

*UMF "Carol Davila" Bucharest; Neurosurgical Department of the National Institute of Neurology and Neurovascular Diseases - Bucharest  
Email: muguradoi@yahoo.com*

### References

1. Al-Mefty O, Fox JL, Smith RR. Petrosal approach for petroclival meningiomas. *Neurosurgery* 1988;22:510-517.
2. Al-Mefty O, Smith RR. Clival and petroclival meningiomas. In Al-Mefty O (ed): *Meningiomas*. New York: Raven Press, 1991, pp 517-537.
3. Bricolo A, Turazzi S. Petroclival meningiomas. In Schmidek and Sweet (ed): *Operative Neurosurgical Techniques*. New York: W.B. Saunders Company, 2000, pp. 932-955.
4. Castellano F, Ruggiero G. Meningiomas of the posterior fossa. *Acta Radoil (Suppl)* 1953;104:1-157.
5. Cherington M, Schneck SA. Clivus meningiomas. *Neurology* 1966;16:86-92.
6. Couldwell WT, Weiss MH. Surgical approaches to petroclival meningiomas. Part I: upper and midclival approaches. *Contemp Neurosurg* 1994;16:1-6.
7. Hakuba A, Nishimura S, Tanaka K, Kishi H, Nakamura T. Clivus meningioma: Six cases of total removal. *Neurol Med Chir (Tokyo)* 17:63, 1977

8. Iacob G, Craciun M, Tene S. Microsurgical removal of posterior petrosal and petroclival meningiomas: a report of 8 cases. *Romanian Neurosurgery* 2011, vol. XVIII, no. 2
9. Javid, T., Sekhar, L. N. Surgical management of clival meningiomas. *Acta Neurochir. (Wien.)*, 53: 171-182, 1991.
10. Kawase T, Shiobara R, Ohira T, Toya S. Developmental patterns and characteristic symptoms of petroclival meningiomas. *Neurol Med Chir (Tokyo)* 1996 Jan; 36(1):1-6.
11. Kawase T, Shiobara R, Toya S. Anterior transpetrosal-trans tentorial approach for sphenopetroclival meningiomas: Surgical method and results in 10 patients. *Neurosurgery* 28:869, 1991.
12. Mayberg MR, Symon L. Meningiomas of the clivus and apical petrous bone: report of 35 cases. *J Neurosurg* 1986;65:160-167.
13. Pieper DR, Al-Mefty O. The surgical management of petroclival meningiomas. In Kaye AH and Black PMcL (ed): *Operative Neurosurgery*. New York: Churchill Livingstone Press, 2000, pp 559-574.
14. Sakaki S, Takeda S, Fujita H, Otha S. An extended middle fossa approach combined with a suboccipital craniectomy to the base of the skull in the posterior fossa. *Surg Neurol* 28:245, 1987.
15. Samii M, Ammirati M, Mahran A, Bini W, Sefhernia A. Surgery of petroclival meningiomas: report of 24 cases. *Neurosurgery* 24:12, 1989
16. Samii M, Tatagiba M. Experience with 36 surgical cases of petroclival meningiomas. *Acta Neurochir* 118:27, 1992.
17. Samii M, Tatagiba M, Carvalho GA. Resection of large petroclival meningiomas by the simple retrosigmoid route. *J Clin Neurosci* 1999;6:27-30
18. Sekhar LN, Estonillo R. Transtemporal approach to the skull base: an anatomical study. *Neurosurgery* 19:799, 1986.
19. Symon L. Surgical approaches to the tentorial hiatus. In Krayenbuhl H, ed. *Advances and technical standards in neurosurgery*. Vol 9. Vienna: Springer-Verlag. 1982, pp. 69.
20. Tahara A, de Santana PA Jr, Calfat maldaun MV, Panagopoulos AT, da Silva AN, Zicarelli CA, Pires de Aguiar PH. Petroclival meningiomas: surgical management and common complications. *J Clin Neurosci* 2009, 16:655-65.
21. Tatagiba M, Acioly MA. Retrosigmoid approach to the posterior and middle fossae. In Ramina R, Aguiar P, Tatagiba M – *Samii's Essentials in Neurosurgery*, 2008;14, 146.
22. Yasargil MG, Mortara RW, Curcic M. Meningiomas of basal posterior fossa. In Krayenbuhl H, ed. *Advances and technical standards in neurosurgery*, vol. 7 Vienna; Springer-Verlag, 1980;1-115.
23. Wu ZB, Yu CJ, Guan SS. Posterior petrous meningiomas: 82 cases. *J Neurosurg* 2005;102: 284-9.