

***Letter to the editor:*****Extensive dilatation of third ventricle masking the diagnosis of aqueductal stenosis****Amit Agrawal**

Professor of Neurosurgery, Department of Neurosurgery, MM Institute of Medical Sciences &amp; Research, Mullana (Ambala), India

**Dear Sir,**

In 10% of adult patients with hydrocephalus, the cause is because of aqueductal stenosis (AS), causing enlargement of the lateral and third ventricles. (1) 40 year gentleman presented with progressively increasing headache of three weeks duration with off and vomiting and mild relief in headache after vomiting. He had 3-4 episodes of loss of consciousness and it was associated with decerebrate posturing. There were no tonic clonic movements. At the time of presentation to emergency his general and systemic examination was normal. On examination, he was conscious and oriented. His higher mental functions were normal. Fundus examination revealed bilateral papilloedema. There were no motor, sensory, or cerebellar signs, and no signs of meningitis. His plain CT scan showed dilated third and lateral ventricles and a hypodense lesion in the posterior third ventricular region (Figure 1). A diagnosis of third ventricular tumor with obstructive hydrocephalus was suspected. In view of multiple hydrocephalic episodes he underwent right ventriculo-peritoneal shunt

in emergency. He improved in his headache and doing well. He was planned for MRI and it showed reduction in the size of the ventricles (Figure 2 A-D). Mass in the posterior third was disappeared and aqueductal stenosis was apparent. The fourth ventricle was disproportionately small. All these features were suggestive of adult onset aqueductal stenosis.

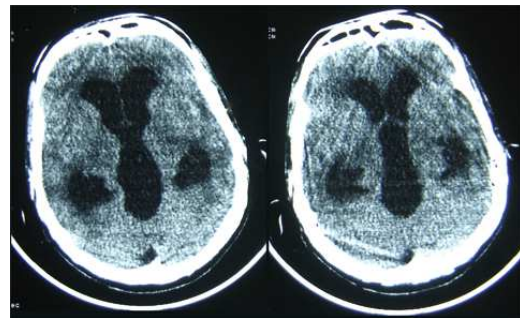


Figure 1: CT scan plain axial view showing extensive dilation of lateral and third ventricles and a lesion in the posterior part of third ventricle compressing the upper brain stem

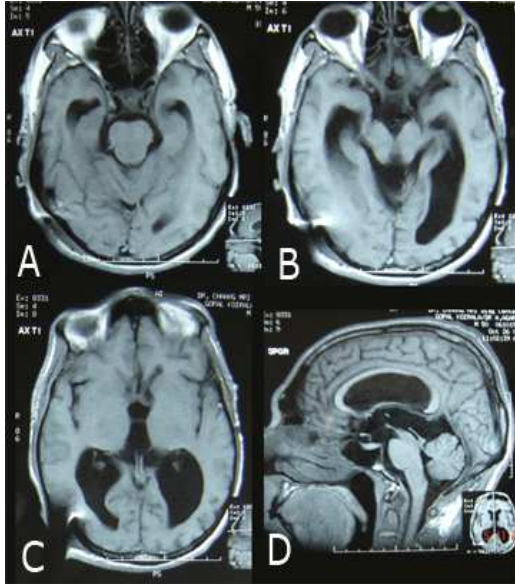


Figure 2 A-D - Post-operative MRI of the same patient showing reduction in the size of the ventricles and aqueductal stenosis (A and D)

Aqueductal stenosis usually manifests in infancy or early adulthood with features suggestive of raised intracranial pressure syndrome. Aqueductal stenosis in infancy usually manifests as failure to thrive and/or bulging fontanelle. (2) Late onset idiopathic aqueductal stenosis (IAS) may become manifest clinically either by headaches or by hydrocephalic symptoms such as gait disturbance, urinary urge, and cognitive impairment. (2) There are currently two

alternate forms of surgical treatment for AS; shunt surgery and ventriculostomy. Shunt surgery is associated with high complication rates and many patients need revisions, but the effectiveness is high. (1, 3) Endoscopic surgery is straightforward and effective in appropriately selected cases with obstructive hydrocephalus. (3) Endoscopic third ventriculostomy (ETV), re-establishing a physiological route of CSF dynamics, has become the treatment of choice for AS in most neurosurgical centers. ETV has fewer complications and revisions are rare, but some patients need shunt surgery to improve despite a patent ventriculostomy. (1, 3) This case illustrates that if the facilities are available investigating these patients with MRI would have helped in diagnosing aqueductal stenosis and ETV is an effective option in these patients.

## References

1. Tisell M. How should primary aqueductal stenosis in adults be treated? A review. *Acta Neurol Scand.* 2005; 111(3):145-53.
2. Fukuhara T, Luciano MG. Clinical features of late-onset idiopathic aqueductal stenosis. *Surg Neurol* 2001; 55:132-6.
3. Choi JU, Kim DS, Kim SH. Endoscopic surgery for obstructive hydrocephalus. *Yonsei Med J.* 1999; 40(6):600-7.