

Onyx treatment of dural arteriovenous fistulae. Our first experience

A. Chiriac, B. Iliescu¹, N. Dobrin¹, I. Poata

“Grigore T. Popa” University of Medicine and Pharmacy, Iasi

¹“Prof. Dr. N. Oblu” Clinic Emergency Hospital, Iasi

Abstract

Intracranial dural arteriovenous fistulae (DAVF) with retrograde cortical venous drainage are uncommon lesions frequently associated with a poor prognosis if left untreated. The treatment of DAVFs with cortical venous drainage by endovascular occlusion of the entire arterial supply or the venous drainage is considered curative. We present our first endovascular experience with use of Onyx via the arterial route in these aggressive fistulas.

Key words: dural arteriovenous fistulae; Onyx embolization

Introduction

Cerebral vascular malformations like intracranial dural arteriovenous fistulas (DAVFs) are considered today dangerous lesions if left untreated, especially those with retrograde cortical venous drainage. Because the natural history of untreated lesions is frequently associated with a poor prognosis, prompt treatment is indicated.

Dural arteriovenous fistulas are considered abnormal direct connection (fistula) between multiple meningeal arteries (arterial feeders) and a meningeal vein or dural venous sinus.

The treatment of DAVFs with cortical venous drainage consist in occlusion of the all arterial supply or the venous drainage

and can be done surgically, endovascularly, or by a combination of both approaches. Endovascular treatment of total occlusion of a DAVF using a transarterial embolization it's difficult as a result of this extreme rich anastomotic network of the dural/falcine plethora of feeding arteries, blood supply to cranial nerves, and extra-intracranial anastomoses [1]. Transvenous occlusion of the affected venous sinus could be effective in selected cases, especially when the venous sinus did not drain into cortical or deep veins.

The endovascular occlusion of DAVFs via an arterial or venous route has usually included embolization with acrylic glue, particles, coils, or a combination. Today, the use of Onyx (ev3, Irvine, California) via the arterial route has been reported as the optimal treatment choice. Due to its longer precipitation time enabling prolonged injection time, the Onyx offer a better penetration into a fistulous network. We report our initial experience with arterial injection of Onyx in the endovascular treatment of a DAVF with retrograde cortical.

Technical procedure

For a complete cure, the endovascular treatment is considered the primary modality of treatment of all DAVFs at most neurosurgical center. The liquid embolic agent, ONYX 18 (ethylene vinyl alcohol

copolymer, ev3), is usually used for treatment of the patients with these lesions.

The procedure is performed with the patient under general anesthesia on a biplane angiographic unit (Axion Artis; Siemens Medical Solutions, Erlangen, Germany).

Unilateral or bilateral transfemoral approach involving the use of 5F–6F introducing sheaths permits arterial catheterization. Standard coaxial techniques ensure a secure guiding and control catheters positioning in the external, internal carotid or vertebral arteries. The guiding catheter is continuously flushed with saline solution for prevention of thromboembolic events.

At the beginning a six-vessel complete selective angiography is performed to precisely determine the anatomic characteristics of the shunt, to obtain an optimal projection and to plan the treatment. After the diagnostic angiography was concluded, a 5F guiding catheter was used for the external carotid artery (ECA) and 6F MPC Envoy guide catheter (Cordis Endovascular, Miami Lakes, Fla) for the internal carotid artery (ICA) and vertebral artery (VA) 6F) catheterization. An intravenous bolus of 5000 IU loading dose of heparin is administered to patient after guiding catheter placement and 1000 units per hour thereafter.

Superselective catheterization of the predominant feeding artery using a dimethyl-sulfoxide (DMSO) compatible microcatheter (Marathon, EV3, Irvine, CA) (UltraFlow, Marathon, or Echelon, ev3) coaxially advanced on a 0.008 inch microguidewire (Mirage or X-Pedion, ev3) is performed to reach the distal aspect of the pedicle supplying the DAVF as close as

possible to the fistula. Microcatheter angiography is then performed to confirm optimal position and to see the drainage of the fistula. Special attention is taken to ensure that the distal tip of the catheter is in a straight segment of the feeding artery to facilitate catheter retrieval. The microcatheter is less likely to stick when placed in a straight rather than a tortuous segment of the vessel.

The microcatheter is then flushed with 10 mL of normal saline and its “dead space” is subsequently filled with 0.25 mL of DMSO, and the microcatheter hub is bathed with DMSO forming a meniscus. Onyx and dimethyl-sulfoxide (DMSO) are drawn into 2 separate 1-mL syringes. DMSO is injected slowly over 40 sec.

The Onyx vial is shaken on the Onyx mixer for at least 20 min prior to its use. Then, Onyx 18 is slowly injected, initially 0.2 mL/s, without guidance, over approximately 40 seconds to avoid a rapid bolus of DMSO in the cerebral circulation. Subsequently under subtraction fluoroscopy or biplane roadmap guidance Onyx injection is then slowly carried out using a “thumb-tapping” technique. In case of high flow fistulas a higher viscosity Onyx 34 is better to be chosen because the higher viscosity agent is felt to be less likely to pass through the fistulous connection. Later in the course of the injection, once flow through the fistula is reduced, lower viscosity Onyx 18 is used to facilitate greater penetration of the nidus of the fistula (figure 1 A, B).

Special attention is paid to maintain a gradual and progressive injection rate, while looking for any reflux of the embolizing agent, which would signal the surgeon to interrupt the injection.

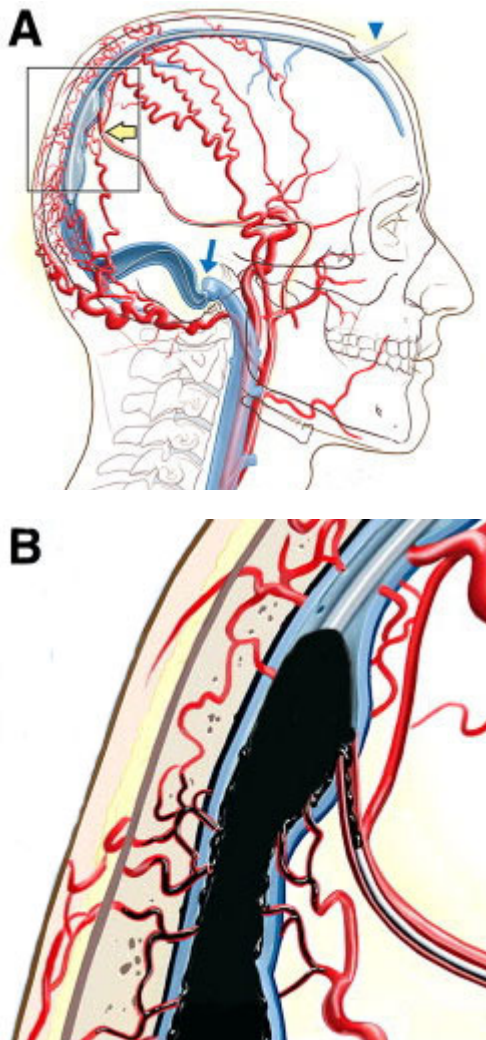


Figure 1: A - microcatheterization of the DAVF; B - Onyx occlusion of DAVF [12]

If Onyx penetrated the network of arterial feeders, the injection is continued until we suspected any of the three danger signs: 1) penetration of Onyx into a cortical vein 2) when there is any reflux around the catheter tip or 3) if there is retrograde filling into pial feeder. In these situations we abort the injection for 30s to 120s to allow solidification of Onyx in an attempt to change the direction of penetration in the network of interconnecting feeders. Usually, reflux occurred several times

before Onyx would advance into the fistula site. A small amount of initial reflux is allowed, as it typically leads to the formation of a “plug,” which may subsequently facilitate antegrade flow of the embolic agent. Excessive reflux, however, is avoided, since it may lead to the occlusion of normal vessels or make the microcatheter removal more difficult. The normal length of tolerated reflux is between 1.5 and 3 cm, depending on the vascular territory. In some cases with middle meningeal artery injection, more than a 5-cm reflux was accepted. In other particular cases a feeding artery could be blocked with a microballoon (HyperForm, ev3) to prevent reflux and promote advancement of Onyx into the target sinus. Protective balloons should be used in cases with high-flow DAVFs with large supplies from the vertebral or the internal carotid arteries. Flow control can be achieved with manual compression of the carotids or both the jugular vein and the carotid, or by balloon occlusion of the venous sinus.

Using this “waiting technique” to change the direction of filling of the fistula when a dangerous sign is identified is crucial to achieve complete obliteration of the fistula. Whenever reflux appears, injection is stopped for sometime. When restarting the injection, it was helpful to employ roadmap techniques to rapidly identify the new site of Onyx delivery to ensure a safe embolization.

The procedure is considered terminated when reflux recurred and persisted and no Onyx is entering the fistula feeding network or when angiography shows a complete fistula occlusion. The microcatheter is then pulled gently until it detached from their Onyx cast. Ultraflow microcatheters (ev3) could be stretched

until rupture in their distal flexible end, if they did not move. Marathon microcatheters (ev3) are braided and stiffer, allowing much more force for retrieval before rupture could occur.

Patients are heparinized over 24–48 h and eventually kept on low molecular weight heparins for 1–2 weeks when we observed slowing down of territorial venous outflow or contrast stasis in various cortical veins.

Case report

A 57 year-old woman presented in December 2012 for an episode of speech disturbances and right temporal hemianopsia. The patient declares a history of ten years of a sincron noise in the left ear associated with retroauricular throbbing pain. She was diagnosed in March 2012 with breast carcinoma and operated by total left mastectomy followed by chemotherapy and radiotherapy.

Neurological examination was normal except for pulsatile tinnitus. The patient initially underwent cerebral CT scan with enhancement that revealed low-density areas in left hemisphere regions, with several punctiform or vermicular enhancements (figure 2).

Digital Subtraction Angiography showed a dural fistula with supply from the tentorial artery, posterior auricular artery, middle meningeal artery, and occipital artery and draining into a left sigmoid sinus with multiple venous ectasies in the left cerebral hemisphere (figure 3).

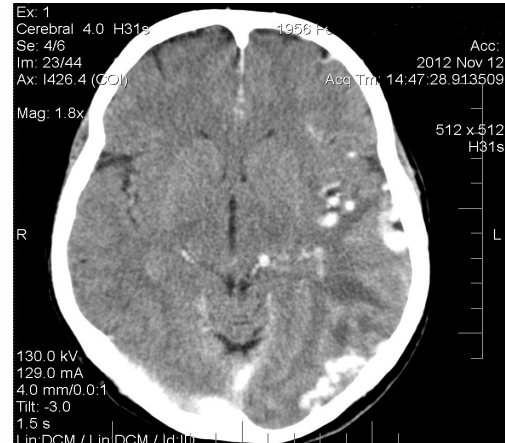


Figure 2 CT scan with several punctiform or vermicular enhancements

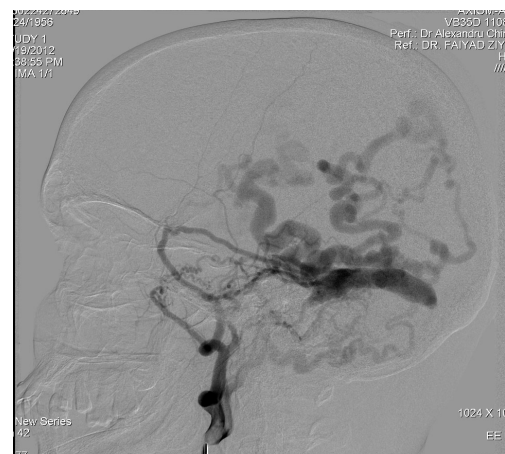


Figure 3 DSA showing a DAVF with cortical vein drainage

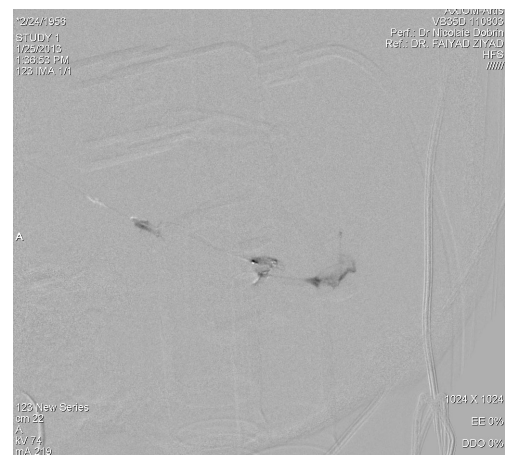

Figure 4 DSA image with Onyx migration showing the perforation of microcatheter

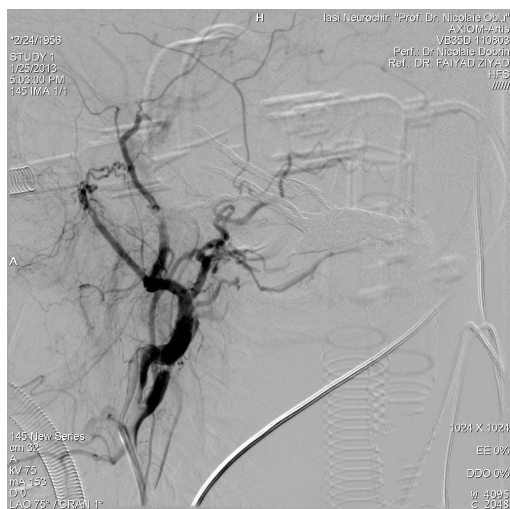

Figure 5 Postprocedural angiography showing DAVF complete occlusion

The patient initially underwent a left middle meningeal artery branch approach. When the DMSO injection was performed a perforation of the microcatheter occurs due to a high pressure injection. The perforation of microcatheter was visualized when the injection of Onyx was started and the glue migrated into the artery at the perforations sites. The injection was stopped with the retrieve of the microcatheter (figure 4). The posterior auricular branch was microcatheterized and the DAVF (fistula segment of left sigmoid sinus) was completely occluded with Onyx. Complete occlusion of the DAVF is confirmed by postprocedural angiography (figure 5). The patient was discharged seven day later with no neurological deficit.

Discussion

The relationships between intracranial dural arteriovenous fistula, venous drainage patterns and clinical presentation were already presented in several studies. Many researchers have attempted to identify the factors that predispose to the risk of aggressive DAVF symptoms. On the basis of their findings, it is now generally

accepted that the venous drainage pattern of DAVFs is the most predictive factor.[5] Intracranial DAVFs with retrograde cortical venous drainage are more aggressive lesions that have shown a much higher incidence of hemorrhage or venous infarction. Usually, these lesions can present with intracranial hemorrhage, seizures, progressive neurologic deficit, intracranial hypertension, or dementia. Although several classification systems have been developed to grade the risks of DAVFs, those devised by Cognard et al and Borden et al are the most widely used.[5]

General approaches for the treatment of DAVFs include conservative treatment, radiation therapy, endovascular intervention, and surgery. Treatment option is dependent on the grade of fistula and the clinical picture. In selected cases as DAVF without angiographic evidence of retrograde sinus or cortical venous drainage and presenting with a well-tolerated or non-disabling tinnitus conservative treatment can be effective. The simple carotid artery or occipital artery manual compression has been reported to occasionally lead to DAVFs obliteration. Also, this may correspond to the natural history of the disease.

The most frequently treatment of such fistulas primarily involves an endovascular approach, and if this fails, surgical or radiosurgical approaches are used. Also, the combination of them is sometime an option.

Transarterial embolization of DAVF with embolic materials such as NBCA, ethanol, coils, and particles didn't bring satisfactory results especially for extensive lesions because only large feeding artery can be occluded. Incomplete occlusion of the fistulas will result in recanalization of the DAVF from the multiple collateral arteries constituting the dural blood supply[1].

Onyx™ (ev3, Irvine, CA, USA) is a liquid embolic material that is increasingly used via the arterial route in embolization of arteriovenous malformations. Its properties of longer precipitation time enabling prolonged injection time, with potential of better penetration into a fistulous network make Onyx the best option for complete DAVFs occlusion.

Onyx treatment for DAVFs with cortical venous drainage is encouraging and our case presentation confirms the good results reported recently by other authors [6].

The complications reported in the literature were the bleeding after incomplete occlusion, cerebral ischemia due to venous thrombosis and ischemic damage to the trigeminal and facial nerves. Damage to these nerves may occur if Onyx reflux extends proximally to the foramen spinosum level and occludes the cavernous and petrosal branches.[6]

The annual mortality rate for cortical venous reflux may be as high as 10.4%, whereas the annual risk for hemorrhage or nonhemorrhagic neurologic deficits during follow-up are 8.1% and 6.9%, respectively, resulting in an annual event rate of 15%.[3]

Conclusions

A better understanding of factors as drainage patterns, risk of aggressive symptoms and feasibility of recent technical advances is essential for the treatment of DAVFs. Onyx embolization has revolutionised the endovascular treatment of DAVFs and become the primary treatment option for most cases. Despite achieving a higher cure rates in single session with minimal complication, larger number of cases and longer follow up are required to determine the efficacy and safety of this technique.

References

1. Katsunari Namba, Yasunari Niimi, Joon K. Song, Alejandro Berenstein (2009) Onyx transarterial embolization of dural arteriovenous fistula for failed N-butyl cyanoacrylate treatment: case report, JNET 3:174-180;
2. Alexandros L. Georgiadis, Giuseppe Lanzino, Nazli Janjua, Jawad F. Kirmani, Adnan I. Qureshi (2008) A case of dural arteriovenous fistula with retrograde intracranial venous flow, J Vasc Interv Neurol; 1(1):9-13;
3. C. Cognard, A.C. Januel. N.A. Silva, Jr. P. Tall (2008) Endovascular Treatment of Intracranial Dural Arteriovenous Fistulas with Cortical Venous Drainage: New Management Using Onyx, AJNR Am J Neuroradiol 29:235– 41;
4. W.J. van Rooij, M. Sluzewski (2010) Curative Embolization with Onyx of Dural Arteriovenous Fistulas with Cortical Venous Drainage, AJNR Am J Neuroradiol 31:1516 –20;
5. Hiro Kiyosue, Yuzo Hori, Mika Okahara, Shuichi Tanoue, Yoshiko Sagara, Shunro Matsumoto, Hirofumi Nagatomi, Hiromu Mori (2004) Treatment of Intracranial Dural Arteriovenous Fistulas: Current Strategies Based on Location and Hemodynamics, and Alternative Techniques of Transcatheter Embolization1, RadioGraphics 24:1637–1653;
6. José E. Cohen, John M. Gomori, Samuel Moscovici, Eyal Itshayek (2011) Dural Arteriovenous Fistula with Cortical Venous Drainage: Complete Occlusion with Onyx Embolization, IMAJ 13:705-6;
7. E. William.Adams (2007) Intracranial Dural Arteriovenous Fistulae, vol. 7, 3:10-12;
8. Rashmi Saraf, Manish Shrivastava, Nishant Kumar, Uday Limaye () Intracranial Dural Arteriovenous Fistulae, Indian J Radiol Imaging, vol 20, 1:26-33;
9. Chai Eq, Wang J. (2011) Transarterial Onyx embolization of sagittal sinus dural arteriovenous fistulae. Neurol India 59:262-5.
10. Chong BW, Demaerschalk BM. (2008) Unusual Presentation of a Dural Arteriovenous Fistula of the Superior Sagittal Sinus and Single Modality Therapy with Onyx. Radiology Case Reports 3:158;
11. Ross C. Puffer, David J. Daniels, David F. Kallmes, Harr yJ. Cloft, Giusepp e Lanzino (2012) Curative Onyx Embolization of Tentorial Dural Arteriovenous Fistulas, Neurosurg Focus 32(5):1-7.
12. Alejandro M. Spiotta, Thinesh Sivapatham, Muhammad Shazam Hussain, Ferdinand K. Hui, Shaye I. Moskowitz, Rishi Gupta (2012) Combined Surgical and Endovascular Approach to a Complex Dural Arteriovenous Fistula Involving the Superior Sagittal Sinus and Torcula, Vol 21, 4:283–288.