

## **International Neuroscience Institute (INI) Center Hanovra. A new step in neurosurgery**

**D.A. Nica<sup>1</sup>, R. Copaciu<sup>1</sup>, A.V. Ciurea<sup>2</sup>**


<sup>1</sup>Neurosurgery Clinic, “Sf. Pantelimon” Clinical Emergency Hospital, Bucharest, Romania

<sup>2</sup>First Neurosurgery Clinic, “Bagdasar-Arseni” Emergency Hospital, Bucharest, Romania

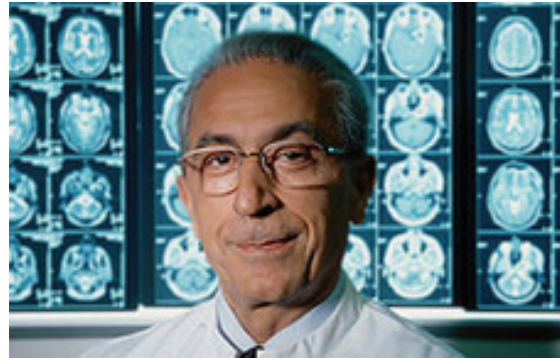When you get in front of the building of the International Neuroscience Institute (INI) Center in Hannover you become instantly impressed with the way it was designed. The exterior aspect is that of a giant human brain and inside, the main pillar, represented by the elevators, resembles the brain stem (1) (Figure 1).

The INI Center project was initiated by the distinguished Professor Madjid Samii and it was designed and accomplished mainly by the Siemens Company. The first symbolic foundation brick was laid in December 1998 and after only 18 months, in July 2000, at the occasion of the World Exposition in Hannover, it was inaugurated in the presence of 1800 guests (2).

The exterior and the interior space design (extremely functional) along with the department constitution was also suggested and coordinated by Professor Madjid Samii.



**Figure 1** Exterior and interior design of INI Center



**Figure 2** Prof. Madjid Samii

Prof. Dr. med. Dr. h. c. mult. Madjid Samii (Figure 2) is the founder and President of the INI Center. He was President of World Federation of Neurosurgical Societies (WFNS), Doctor Honoris Causa of many universities and honorary member of Romanian Society Neurosurgery (RSN). He headed the Neurosurgical Department of the Nordstadt Hospital Hannover and the Neurosurgical Department of the medical School Hannover until 2003. Since then he is working exclusively at the INI Clinic and Research Institute (2).

Throughout his entire career, Prof. Dr. Madjid Samii, has perfected and continues to perfect neurosurgical techniques, bringing an essential contribution in the approach of ponto cerebral angle and brain base tumors, leading as well the

Department of “Skull base surgery” of INI. Through his imposing personality and his charisma, he succeeded to gather along his side a group of world renowned professors, each specialized on certain neurosurgical fields.



**Figure 3** Prof. Amir Samii



**Figure 4** Prof. Helmut Bertalanffy



**Figure 5** Prof. Rudolf Fahlbusch

Prof. Dr. Med. Amir Samii is the Vice-Director of the Neurosurgical Center (Figure 3).

Prof. Dr. Med. Helmut Bertalanffy is the Director of Neurovascular Surgery Department from 2010 (Figure 4). He received his neurosurgical training from the Albert-Ludwigs University of Freiburg im Breisgau, Germany, where he completed with honors a Medical Doctorate in 1986 and obtained the qualification as board certified neurosurgeon in 1990. In 1997 Dr. Bertalanffy was appointed to Professor on a permanent basis by the State of Hessen, Germany, and served as Professor and Chairman of the Department of Neurosurgery of the Philipps University of Marburg for 10 years. In July 2007 he was appointed to Chairman of the Department of Neurosurgery of the University of Zurich, Switzerland, where he served three and a half years in that position. In November 2010 he accepted the new position of Director of the Center for Vascular Neurosurgery at the prestigious International Neuroscience Institute in Hannover, Germany (3).

Prof. Dr. med. Rudolf Fahlbusch is the Director of Neuroendocrine Surgery Department (Figure 5). His major neurosurgical contribution to the sellar region tumors is internationally renowned (3).

Prof. Dr. Med. Dieter Hellwig is the Director of Stereotactic and Functional Neurosurgery Department.

Prof. Dr. Med. Wolfgang R. Lanksch is the Director of General Neurosurgery Department.

Prof. Dr. Med. Shizno Oi is the Director of Pediatric Neurosurgery.

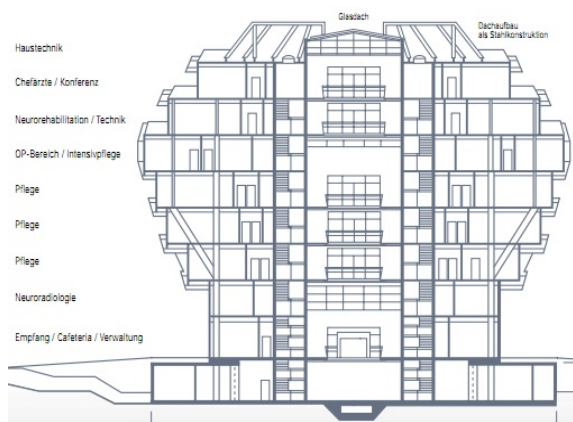
Prof. Dr. Med. Anton Valavanis is the Director of Interventional Neurosurgery Department.

Prof. Dr. Med. Volker Sturm is the Director of Stereotactic Neurosurgery Department.

Prof. Dr. Med. Wolfgang Draf, from the ENT department of the Medical University of Hannover, is a close collaborator with the INI Center, especially in border-line lesions.

Alongside these professors there are other well trained doctors, from different specialties (anesthetists, radiologists, psychiatrists, neurologists, neurophysiologists, anatomopathologists, psychologists, kinetic physiotherapists) who, through their contribution, assure the patients medical investigation and preparation for surgery, as well as postoperative recovery, at the highest level.

The operating rooms are at the fifth floor, a total of six operating rooms, each fitted (beside the basic utilities) according to top standards: operative microscope, complete microsurgery instruments, CUSA, neuronavigation (NAVI) and at least 3 screens for intraoperative viewing (for academic purposes) (3).



**Figure 6** The structure of INI Center

The first operating room is fitted with MRI theatre (1,5 Tesla) for preoperative functional MRI evaluation, intraoperative and postoperative NAVI controlled evaluation, being used especially in intracerebral lesions. For vascular lesions, one of the operating rooms is fitted with angiograph (DSA) for intraoperative evaluation and interventional neuroradiology.

There are also 3 Echo-Doppler devices, 2 neurosurgical endoscopes, 2 more MRI machines (1,5 and 3 Tesla), computed tomography, 4 NAVI, 2 intraoperative electrophysiological evaluation devices, different stereotactic systems, one anesthetic endoscope and other utilities.

Also on the fifth floor is the Intensive Care Unit.

It's worthy to note that the patients are from all around the world, with an impressive addressability.

Having the approval of Prof. Dr. Madjid Samii, I had the honor (among other trainees) to be under the direct guidance of Prof. Dr. Helmut Bertalanffy from 19th of July to 31st of July, as a "Visiting Doctor".

After the clinical and paraclinical preoperative evaluation, the data regarding each patient is subject for discussion with the whole clinic staff so that the surgical interventions are performed in the most accurate and efficient way. Intraoperative, at the same time with the screen presentation of the microsurgical step, the surgery is being recorded in order to be analyzed afterwards and also for possible academic presentation in courses, national and international conferences and congresses.

Intraoperative the key moments of the surgery are pointed and explained by the professors to the group of viewing doctors.

There are no surgical maneuvers, approach, investigation or surgical step that remains unexplained to the smallest detail. In case there are questions or even inadequate answers from trainees, you are being presented with the right solution, thoroughly explained so that there are no uncertainties, without making the trainee look bad. After each surgical intervention, the operation is debated with the entire staff and with the doctors who came for upgrading their practice.

The academic part is impressive, proof of that is the large number of doctors, all around the world, who come for training courses with the INI.

I had the possibility to attend, as well as the other resident or specialist colleagues, the surgical interventions from each of the six operating rooms.

In medium there are 5 daily surgical interventions, most having a high degree of difficulty. It's impressive to realize how fast the 4-5 hours of surgery passes during, for example, an intervention for an acoustic neurinoma "from skin to skin".

This is the operative schedule of an "ordinary" day:

**Operating Room 1.** Diagnosis: right occipital glioma. Approach and goal: posterior temporal-occipital craniotomy; total removal of the tumor. Positioning: supine position. First operator: Prof. Lanksch. Utilities needed: functional MRI into OR, operating microscope, NAVI, CUSA

**Operating Room 5.** Diagnosis: right intracanalicular acoustic neurinoma. Approach and goal: right lateral suboccipital; decompression, ablation. Positioning: semi-seating position. First operator: Prof. M. Samii. Utilities needed: operating

microscope, cardiac Echo-Doppler, SEP, AEP, f-EMG, CUSA

**Operating Room 2.** Diagnosis: infradiaphragmatic pituitary tumor. First operator: Prof. Fahlbusch. Approach: transnasal-transsphenoidal. Utilities needed: operating microscope. Moderate bleeding. Time 2-3 h

**Operating Room 6.** Diagnosis: lumbar disc recurrent herniation. Operation: re-intervention + discectomy. Approach: lateral foraminotomy. First operator: Prof. M. Samii. Utilities needed: operating microscope

**Operating Room 3.** Diagnosis: left anterior-lateral peduncular giant cavernoma. Approach and goal: left medio-lateral suboccipital infratentorial supra-cerebellar; total removal of cavernoma. Positioning: semi-seating position. First operator: Prof. H Bertalanffy. Utilities needed: operating microscope, cardiac Echo-Doppler, SEP, AEP, EMG (Nn. III, IV, VI, VII)

Losing only 100 ml of blood "from skin to skin", short neurophysiologist intervention (only 2-3 times) and the real good follow-up (no neurological deficit) proves that in order to deal with such a lesion and with this kind of topography, one must have solid knowledge of regional topographic anatomy, experience, practice, dexterity and self-confidence characteristic to the education of a samurai, which Professor Hemult Bertalanffy fully possesses.

Thanks to the clinic's international professional, didactic and academic recognition, this project was followed in other countries, so that in 2010, when INI Hannover celebrated a decade of activity, a new INI center was opened in Pekin and

this year in October another INI Center will be opened, in Teheran.

I consider that the activity in this center represents, for every specialist, a mandatory step in professional training and I believe that INI Center Hannover leads where neurosurgery is concerned.

### **References**

1. Prof. Dr. Ciurea, "Hipocrate" magazine. May 2011. Pg 80-81.
2. INI Center 10 Jahre, Jubiliary Edition.
3. [www.ini-hannover.de](http://www.ini-hannover.de).