

## **Intracranial pressure monitoring in neurosurgery department in Iasi – latest developments**

**Alin Iordache<sup>1</sup>, Raluca Munteanu<sup>2</sup>, Mihaela Cosman<sup>2</sup>, Dana-Mihaela Turliuc<sup>1</sup>**

<sup>1</sup>“Gr.T. Popa” University of Medicine and Pharmacy, Iasi

<sup>2</sup>“Prof. Dr. N. Oblu” Clinical Hospital, Iasi

### **Abstract**

Severe head trauma remains an important public health issue and the intracranial pressure monitoring is useful in indicating the patients prognosis, variation especially elevated intracranial pressure were associated with a poor prognosis. We illustrate some cases where we insert the monitoring system (intraparenchymal or intraventricular) and the neurological evolution.

**Keywords:** intracranial pressure monitoring, severe head trauma, Camino monitor.

### **Introduction**

The brain functions and survival depends on cerebral blood flow (CBF). This is a parameter difficult to estimate. In turn CBF depends on cerebral perfusion pressure (CPP) which is associated with intracranial pressure (ICP-easier to quantify). In severe head trauma patients recent study suggested that elevated ICP is more dangerous than changes in CPP. The normal range of ICP varies with age (in adults < 10 -15 mmHg). In 2010 our department of Neurosurgery made an important step in the management of head trauma patients when we introduced the intracranial pressure monitoring. (1, 7)

ICP monitoring was made according with guidelines:

1. neurologic criteria: severe head injury (GCS ≤ 8);

2. an abnormal admitting head CT (contusion, cerebral edema, hematoma with or without midline shift >5mm / cisterns compressed or absent );

3. a normal CT but with more than 2 risk factors: age >40 yrs, decerebrate or decorticate posturing on motor exam (unilateral or bilateral ), systolic blood pressure <90mmHg (3, 11).

There are different types of system for ICP monitoring (6):

1. intraventricular catheter (ICV) - golden standard: advantages: good accuracy in measuring the pressure, allows therapeutic CSF drainage; disadvantages: may be difficult to insert into displaced or compressed ventricles, obstruction of the fluid column (blood clot);

2. subarachnoid catheter: advantages: infectious and hemorrhagic complication are decreased (1 %); disadvantage: surface of brain may occlude lumen resulting in false readings;

3. intraparenchymal catheter: advantage: good accuracy in measuring the pressure; disadvantage: does not allow therapeutic CSF drainage.

### Material and methods

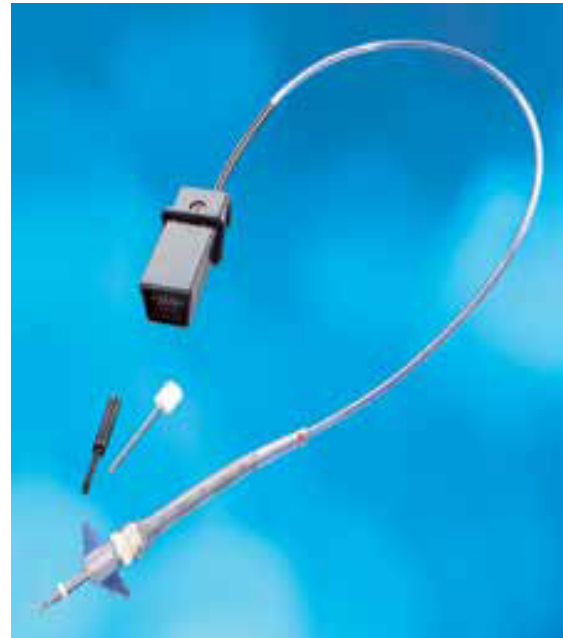In our study the major criteria for ICP monitoring was GCS <8 were excluded those patients with intracranial surgical lesions who were operated. The intervention was important because most of the patients with severe head injury were forensic cases and from ethical point of view we had to evacuate any diagnosed lesions even though the ICP was not increased.

The system used for ICP monitoring was Camino SPM-1 (Figure 1A) made by Integra. This type of monitor uses a transducer with optic fiber to record information, the reference point is the atmospheric pressure.

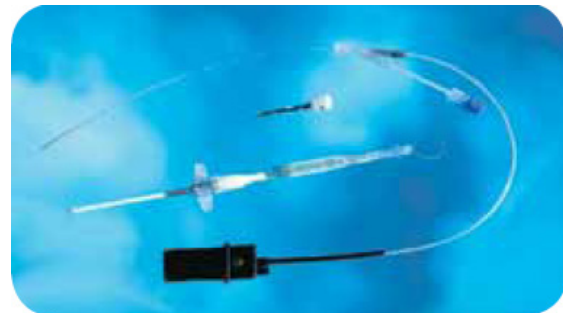We used intraventricular catheter - 1104HM type (Figure 1C) with optic fiber transducer and intraparenchymal catheter - 1104B type (Figure 1B) when the ventricles size were reduced. The ventricular catheter was placed in the frontal horn in the Kocher's point.



A



B



C

**Figure 1** A Camino SPM-1 system;  
B intraparenchymal catheter;  
C intraventricular catheter.

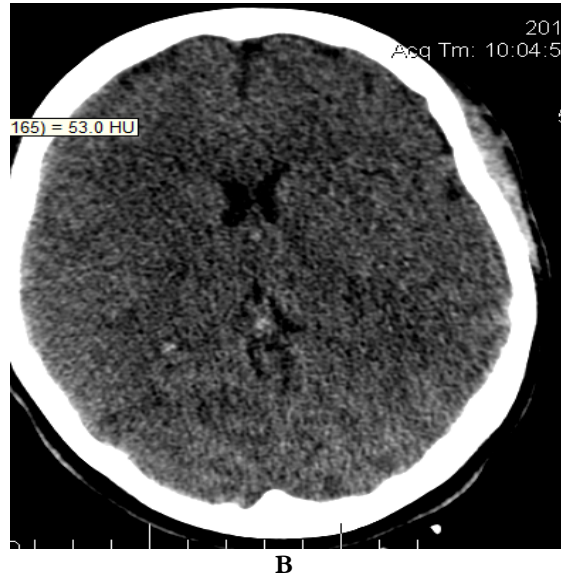
The drainage system 1104HB and 1104B are sterile and disposable. The specialty literature shows that the incidence of infectious complication increases after 5-7 days of use.

Our monitoring study was a retrospective one, the author was directly involved in monitor placing and tracking patient progress. The study lot was formed by 10 patients.

**Illustrive cases**

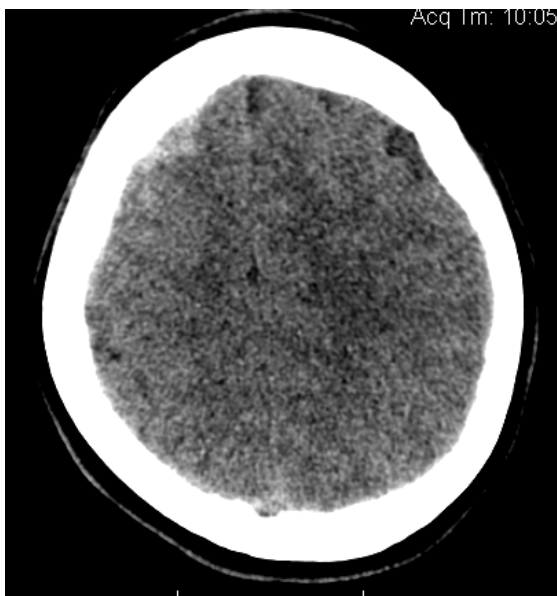
1. Female age 30 presents with a severe head trauma from a car accident. Other organic lesions are excluded by thoraco-abdominal-pelvis CT scan. Her neurologic status was GCS=4 with hyperextension of upper and lower left limbs and Babinski sign positive bilateral. Craniocerebral CT scan shows diffuse cerebral edema in the right hemisphere with mild subfalcine herniation, frontal subarachnoid hemorrhage (Figure 2A) on the right side, multiple hemorrhagic petechiae lesions 2-3mm diameter located predominantly frontal bilatera (Figure 2B) and left temporal bone fracture.

Transcranial Doppler examination by temporal bone window reveals the presence of flow in both sylvian arteries and the flow speed beeing 60 cm / s bilaterally. The patient presents indirect radiological signs of diffuse axonal injury, but also presents the clinical features of intracranial pressure monitoring.

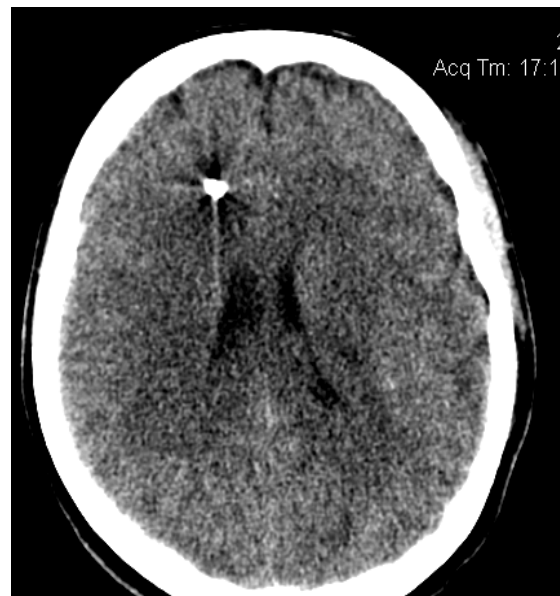

**Figure 2 A** subarachnoid hemorrhage  
**B** petechiae lesions

Regarding the small size of ventricles and cerebral edema predominantly on the right hemisphere we decided to place an intraparenchymatos catheter on the right side (Figure 3).

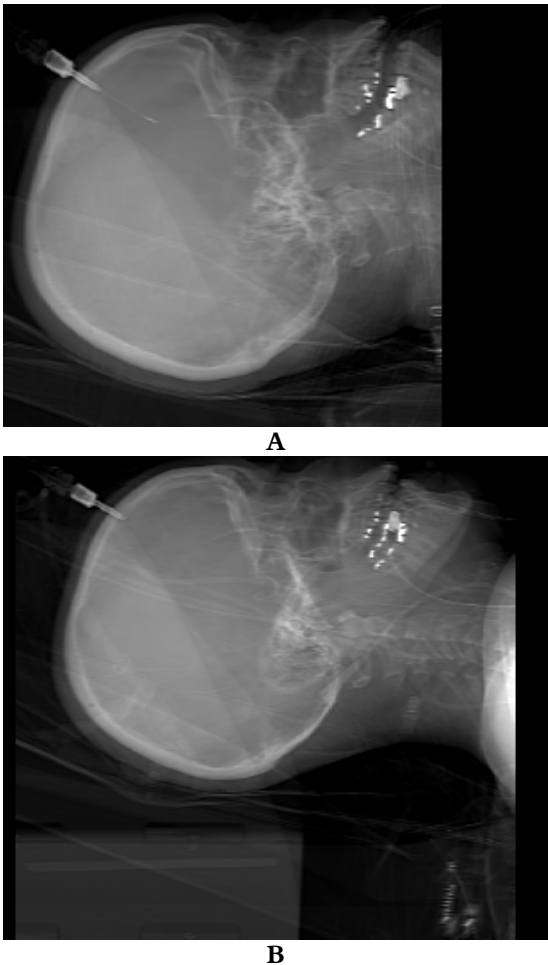


**A**

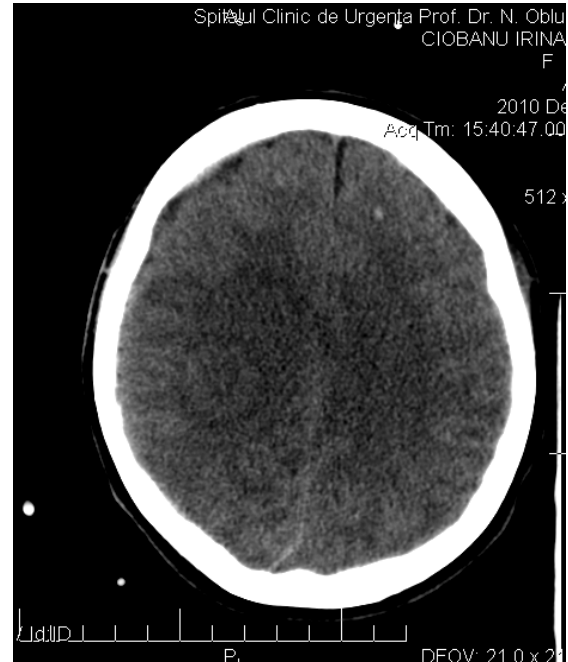


**Figure 3** the pressure transducer

The initial value of ICP was 25 mmHg and after administration of mannitol decrease, reaching at 18 mmHg. Immediately postoperative neurological evolution shows some improvement. The patient has subsequently intracranial pressure values of 3 to 6 mmHg. CT examination was performed for radiological control. There is improvement of cerebral edema. During the second day neurological status deteriorates. Another CT scan is performed which confirms the transducer drift (Figure 4) and shows the emphasize of the petechiae lesions (Figure 5).



**Figure 4** A transducer present  
B transducer absent

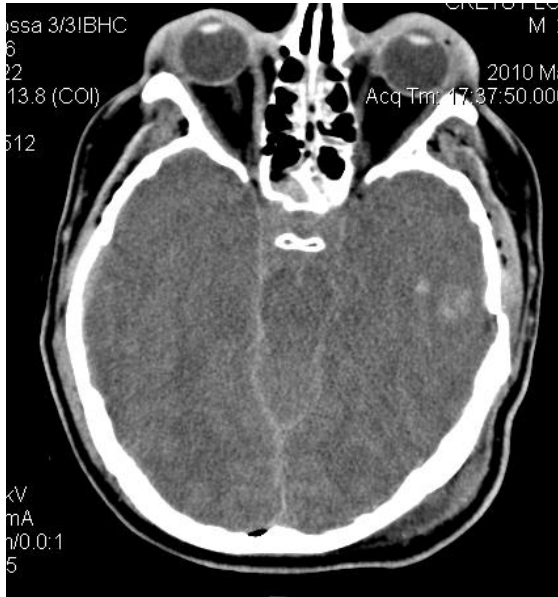

**Figure 5** Hemorrhagic petechiae lesions

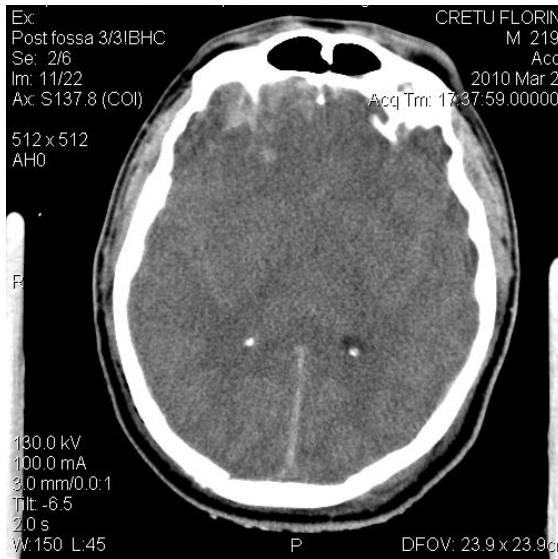
He was intubated for 10 days, the neurological evolution was slightly favorable with discrete movement on her left extremities. At 6 month she recovered quite well with slight hemiparesis on the left side and the MRI control showed no residual sequelae.

2. A 29 years old patient presents with a severe head trauma, thoracic contusion from a car accident. The neurological exam reveals areactive pupils, left ear otorrhea and GCS=5. Cranio-cerebral CT scan shows subarachnoid hemorrhage, left temporal and right frontal hemorrhagic contusion, temporal bone fracture, diffuse cerebral edema (Figure 6), subdural hematoma on the right hemisphere and anterior interhemispheric hematoma (Figure 7A). The ventricular system appears slightly asymmetric with left side subfalcine herniation phenomena (Figure 7B).

The neurological status worsens and he become coma grade IV. We put a parenchymal catheter on the left side and a ventricular catheter in the right ventricle (Figure 8).

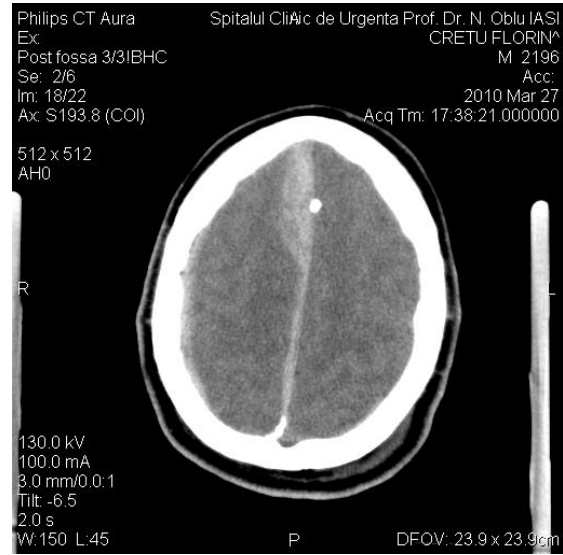


**A**

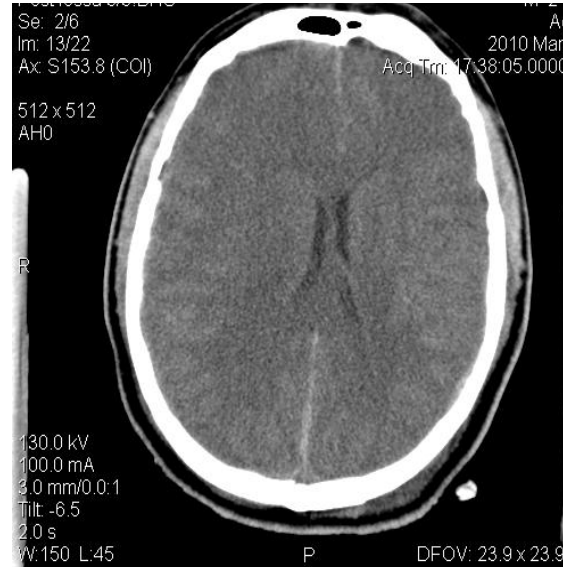


**B**

**Figure 6 A** Subarachnoid hemorrhage, temporal hemorrhagic contusion, left temporal bone fracture;  
**B** frontal hemorrhagic contusion with diffuse cerebral edema

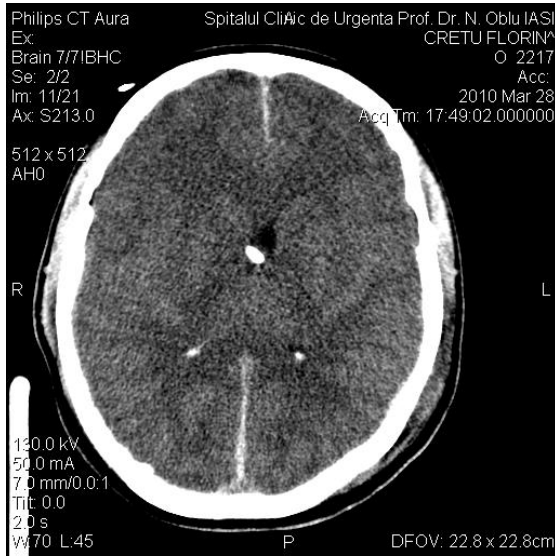


**A**

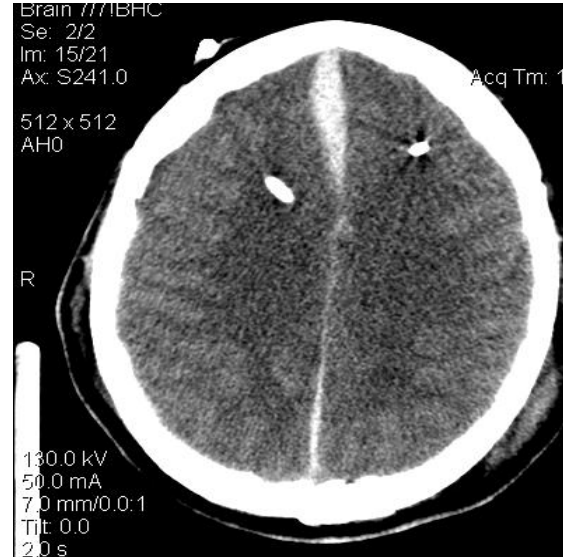

**B**

**Figure 7 A** subdural hematoma on the right hemisphere and anterior interhemispheric hematoma;  
**B** mild ventricles asymmetry with left side subfalcine herniation.



A



B

Figure 8 A right intraventricular catheter; B left intraparenchymal catheter

Postoperative neurological status was stationary and he became a candidate for organs transplantation.

**Discussions**

We study a number of 10 patients all of them had GCS<8. The craniocerebral CT scan made on admission showed different types of lesions (Figure 9).

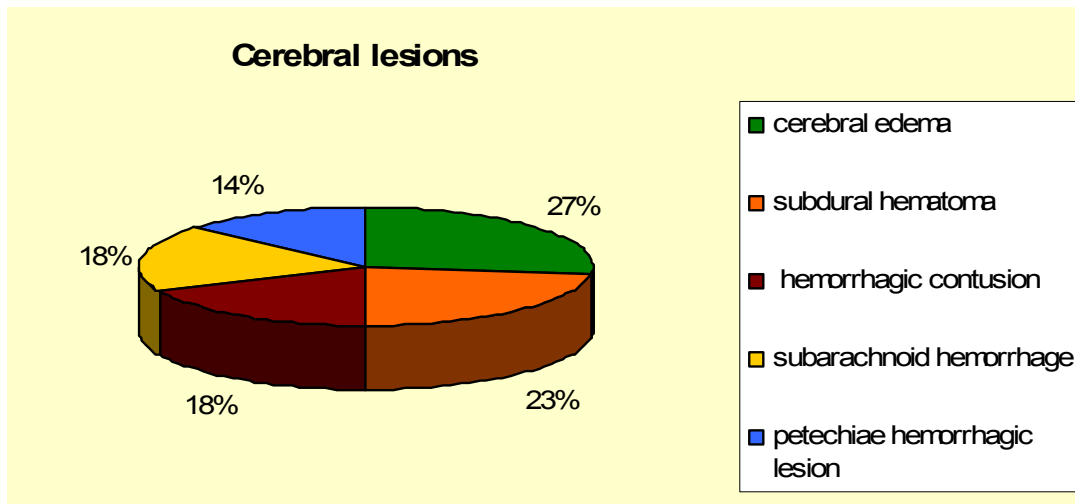


Figure 9 Cerebral lesion found at CT scan

All the patients had another associated lesions (Figure 10).

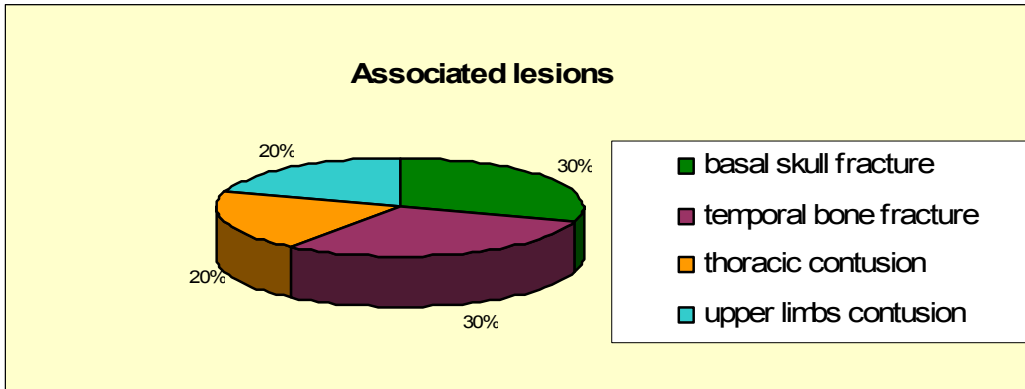


Figure 10 Associated lesions

The neurological status on admission was GCS 6 – 3 (Figure 11).

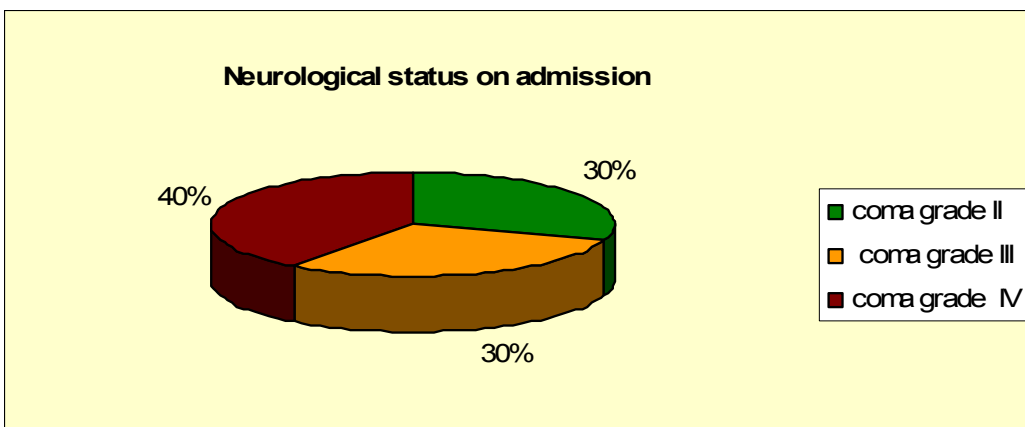


Figure 11 Neurological status on admission

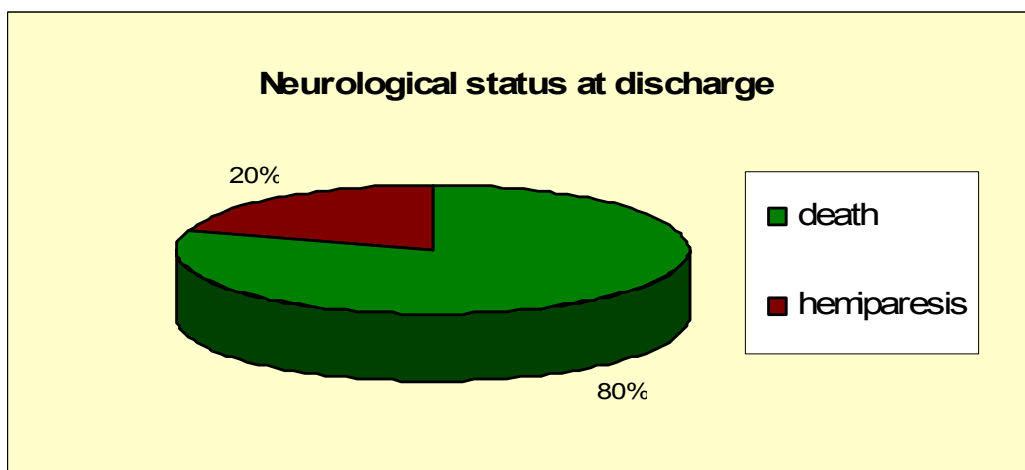


Figure 12 Neurological status at discharge

The number of patients is not extensive. This has an objective reason. The major impediment in achieving a more extensive study is the material one. Intracranial pressure monitor system cost is still prohibitive for our health system - which is between 500 and 700 €.

Another reason is the ethical and the same time – legal reason. Patients with neurosurgical lesions (acute subdural hematoma, epidural hematoma, contusions with important mass effect) requires quick intervention and follow-up of intracranial pressure for such injuries would mean loss of valuable time.

Even that placing an intracranial pressure transducer is a minimally invasive surgical procedure it involves intraoperative risks that should be explained and detailed to patient attendants. In some cases attendants do not accept the surgical risks and the fact that the benefits would not be immediately remarked.

Most patients studied had as expected a poor outcome (Figure 12). Most studies conducted so far on patients with severe head trauma at presentation, after removing the effects of any sedation, continues to

present a state of coma grade III or grade IV and has a mortality reaching 90%. As mentioned above the statistical value data is questionable due to a relatively small number of cases (2, 4).

After insertion of the pressure transducer patient should be monitored for early detection of intracranial complications especially for hemorrhage. For this it is necessary to perform cranio-cerebral computer tomography at short interval after catheter insertion (5). This may be because the neurological worsening in a patient that is already in coma, intubated and artificially ventilated is difficult to detect. All the patient from our study performed an CT scan within 12 hours of monitoring onset. Intracranial pressure monitoring was done by direct reading of pressure values on the monitor display every 2 hours. In general the neurological evaluation is difficult in patients with severe head trauma. They may be evaluated at about 2-3 hours after sedation removal. This assessment was made daily.

Beside the ICP we monitored the temperature (10), arterial blood pressure and heart rate. The ICP variation is shown below.

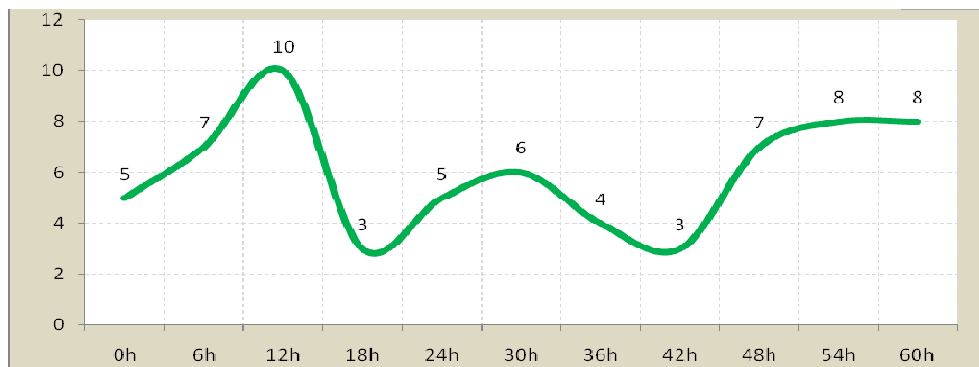


Figure 13 ICP variation – patient no. 1



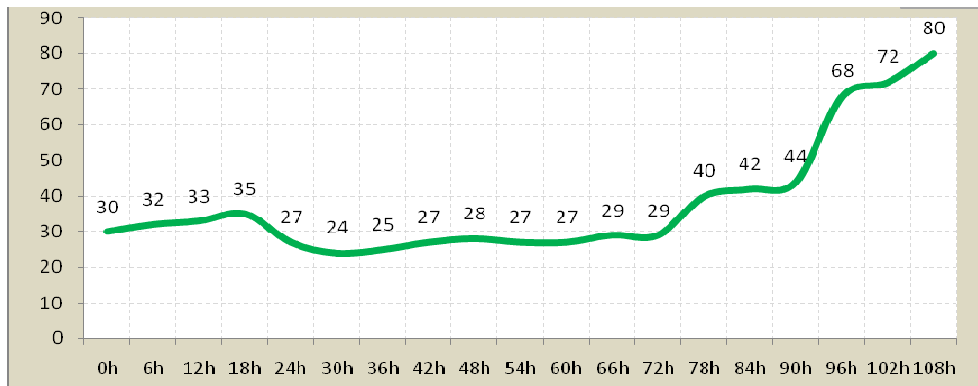


Figure 14 ICP variation – patient no. 2

## Conclusion

ICP monitoring is usually a safe technique complication rate remains low even in the context of the catheter placement by people with less experience. It is useful in indicating the patients prognosis - ICP variation especially elevated intracranial pressure were associated with a poor prognosis (8, 9). It supports the diagnosis of brain death, especially in cases where the series EEG is not conclusive.

The indication for ICP monitoring should be extended to patients who were operated for surgical removal of a traumatic brain lesion and who have other injuries that may lead to increased intracranial pressure. A favorable outcome can be achieved only in the context of good collaboration with intensive care services because variations (upward or downward) of the intracranial pressure must be declared and treated with medication or surgical intervention (14).

Those patients should be more intense monitored and in special carefully manipulated because exist the risk of removing the catheter. Lack of continuous monitoring makes difficult to change the conservative treatment into an aggressive

surgical conduct in time. The evolution of patients who underwent intracranial pressure monitoring as well as other with severe head trauma was aggravated by respiratory infections (13).

A bad outcome in patients with severe head injury who underwent ICP monitoring was associated with significant variations in blood pressure. A factor with poor prognostic was the association with elevated blood glucose repeatedly (12).

In the group of patients who did not have ICP monitoring we observed an increased mortality and also an increased rate of complications associated with prolonged stay in intensive care department.

The vital prognosis of patients with severe head trauma was only one element of the study and it was not neglected the functional aspect and the social impact associated with patient who survived.

The role of this study is to create conditions for a better approach of those patients and this can be achieved only under the conditions of investigation and treatment protocols which must be mandatory but also feasible, adapted to current conditions of our hospital.

One of the conclusions of the study is the fact that it is imperative to be reduced

the duration between the event (craniocerebral trauma) and therapeutic intervention – ICP monitor placement. Another aspect with importance on vital prognosis for polytraumatized patients with craniocerebral components it is the necessity of specialized units, qualified, currently non-existent.

Severe head trauma remains an important public health issue and leaves space for fundamental research, imaging and epidemiological studies.

### References

1. A. I. R. Maas, M. Dearden, G. M. Teasdale, R. Braakman, F. Cohadon, F. Iannotti, A. Karimi, F. Lapierre, G. Murray and J. Ohman, et al. - EBIC-Guidelines for management of severe head injury in adults, *Acta Neurochir (Wien)* (1997) 139: 286–294.
2. Alkhoury F, Courtney J. - Outcomes after severe head injury: a National Trauma Data Bank-based comparison of Level I and Level II trauma centers, *Am Surg.* 2011 Mar;77(3):277-80.
3. Arbour R. Intracranial hypertension: monitoring and nursing assessment. *Crit Care Nurse* 2004;24(5): 19-32;
4. Cremer OL, van Dijk GW, van Wensen E, Brekelmans GJ, Moons KG, Leenen LP, Kalkman CJ. - Effect of intracranial pressure monitoring and targeted intensive care on functional outcome after severe head injury, *Crit Care Med.* 2005 Oct;33(10):2207-13;
5. Glowacki M, Budohoski K, Marszalek P, Walecki J, Czernicki Z. - A non-invasive assessment of intracranial volume reserve by measuring cerebrospinal fluid volume with the aid of CT imaging, *Acta Neurochir Suppl.* 2010;106:199-202;
6. Kathryn Ko, MD, and Alicia Conforti, RN - Training Protocol for Intracranial Pressure Monitor Placement by Nonneurosurgeons: 5-Year Experience, *The Journal of TRAUMA\_ Injury, Infection, and Critical Care* Volume 55, Number 3 480 -484;
7. Mark S. Greenberg - *Handbook of Neurosurgery*, 5th edition, Ed. Thieme New York 2001
8. Marshall L.F., Gautille T., Klauber M.R. - The outcome of severe closed head injury. Report on the Traumatic Coma Data Bank. *J. Neurosurgery* - 1991;75:S28-S36 ;
9. Schoser BG, Riemenschneider N, Hansen HC. The impact of raised intracranial pressure on cerebral venous hemodynamics: a prospective venous transcranial Doppler ultrasonography study. *J Neurosurg.* 1999;91(5):744-749.
10. Thompson HJ, Kirkness CJ, Mitchell PH - Hypothermia and rapid rewarming is associated with worse outcome following traumatic brain injury, *J Trauma Nurs.* 2010 Oct-Dec;17(4):173-7;
11. Timmons SD. - Current trends in neurotrauma care, *Crit Care Med.* 2010 Sep;38(9 Suppl):S431-44 ;
12. Yang SY, Zhang S, Wang ML: Clinical significance of admission hyperglycemia and factors related to it in patients with acute severe head injury. *Surg Neurol* 44:373–377, 1995
13. Zeng T, Gao L. - Management of patients with severe traumatic brain injury guided by intraventricular intracranial pressure monitoring: a report of 136 cases, *Chin J Traumatol.* 2010 Jun 1;13(3):146-51;
14. Zhang LY, Yao YZ, Jiang DP, Zhou J, Huang XK, Shen Y, Huang J. - Surgical treatment strategy for multiple injury patients in ICU., *Chin J Traumatol.* 2011 Feb 1;14(1):42-5;