

Retrosigmoid approach for a ruptured pontine cavernous malformation, in a 10 years old patient. Case report

A. Giovani¹, A.V. Ciurea², Angela Neacsu, R.M. Gorgan

¹PhD Student in Neurosurgery, "Carol Davila" UMPH, Bucharest
Department of Neurosurgery

First Neurosurgical Clinic, IVth department of neurosurgery and

²first department of neurosurgery ; "Bagdasar Arseni" Emergency Clinical
Hospital, Bucharest

Abstract

Brainstem cavernous malformations have a high risk of hemorrhage, ranging from 4 to 60%, this risk being even higher in children where larger lesions are encountered. Even small hemorrhages can cause severe neurological symptoms because of the high density of cranial nerve nuclei and fiber tracts within the brainstem. The goal of surgical treatment is not only the improvement of neurological symptoms, but also preservation of the patient's quality of life.

We present a case of a 10 years old female patient who presented after a 5 weeks conservative treatment with right sided weakness and loss of coordination, right hemihypoesthesia, She was diagnosed with a large left pontine cavernous malformation on MRI. The cavernoma was resected using a retrosigmoidian approach, but a small remnant was left, when the surgery had to be stopped due to severe bradycardia. The neurological deficit improved at follow up.

The choice of the surgical approach that allows the best exposure of the lesion is mandatory. In this case the lesion was evident on the surface of the brainstem and this facilitated its resection. Traction on the

tumor and coagulation near the cranial nerves nuclei should be avoided, but if bradycardia appears the surgery must be stopped.

Surgery is the best choice for the patients with symptomatic brainstem cavernomas that present with hemorrhage and neurological deficit, and its objectives should be complete removal and improvement of neurological deficit.

Keywords: Brainstem cavernous malformations, Cavernous angioma,, Neural tracts, Retrosigmoidian approach

Introduction

Cavernous malformations (CM) are benign angiographically occult vascular malformations with an estimated prevalence of 0,4-0,8% and 5-12% of all intracranial vascular lesions. Brainstem cavernous malformations represent between 9-35% of all brain cavernous malformations, and most of them are localized in pons. Brainstem cavernomas have a high risk of hemorrhage, ranging from 4 to 60%, this risk being even higher in children where larger lesions are encountered (1, 3, 5, 9). In the familial cases there is a higher incidence of multiple cavernomas

Cavernous malformations are treated conservative if they are asymptomatic and no hemorrhage is present, but if symptomatology appears, microsurgical resection is recommended. Given the anatomic features of the brainstem, microsurgical resection of a brainstem cavernoma is amongst the most difficult neurosurgical procedures.

Macroscopically, they appear as mulberry-like heterogeneous masses. On T2-weighted magnetic resonance imaging (MRI), hyper intense zones and partial contrast enhancement may be seen (5). Cavernous malformations are clusters of dilated sinusoidal channels lined by a single layer of endothelium. In contradistinction to arteriovenous malformations, these lesions do not have smooth muscle or elastin in their lining, and they are angiographically occult

Even small hemorrhages can cause, severe neurological symptoms because of the high density of cranial nerve nuclei and fiber tracts within the brainstem. Although some authors suggest conservative management or radiosurgery microsurgical resection of brainstem cavernomas has increasingly been performed to treat symptomatic patients, especially children given the high life expectancy. The goal of surgical treatment is not only the improvement of neurological symptoms, but also preservation of the patient's quality of life (2, 6, 9).

Case Presentation

A 10 years old female patient presented after a 5 weeks conservative treatment with right sided weakness and loss of coordination, right hemihypoesthesia, IV and VII left cranial nerves deficit, with left blepharoraphy in the external third of the

eyelids. The patient was conscious and hardly cooperative with a Karnofsky score of 40.

The eye exam showed bilateral horizontal nistagmus, with conjugate gaze deviation to the right, inferior corneal edema, and at ophtalmoscopy normal vessels and positive foveolar reflex.

A CT scan showed a hematoma in the pons with discrete mass effect on IV ventricle. The angiography was unremarkable there was no indication for AVM or associated venous anomaly.

The MRI revealed a single irregular tumoral mass of 42/27/27 mm surrounded by a region evocative of hemoglobin products especially hemosiderin extended to the left 2/3 of the pons, the left cerebral peduncle, the left middle cerebellar peduncle and the left cerebellar hemisphere, with mass effect on the IV ventricle.

A lateral park bench position was chosen to resect the lesion. A hockeystick incision was used, for a left suboccipital craniotomy. The lesion was subsequently resected using a retrosigmoid approach. The left Cerebellopontine angle was entered under the operating microscope and the arachnoid cisterns dissected to allow retraction of the left cerebellar hemisphere. After the hematoma is evacuated hemosiderin stain was identified on the pial surface surrounding the VI and VII nerve roots, the cavernous malformation is easily dissected from the surrounding gliotic plane using a blunt dissector. The cavernoma couldn't be completely resected leaving a small remnant attached to the pons after many attempts of complete ablation when the resection had to be interrupted due to severe bradycardia, this representing the particularity of the case.

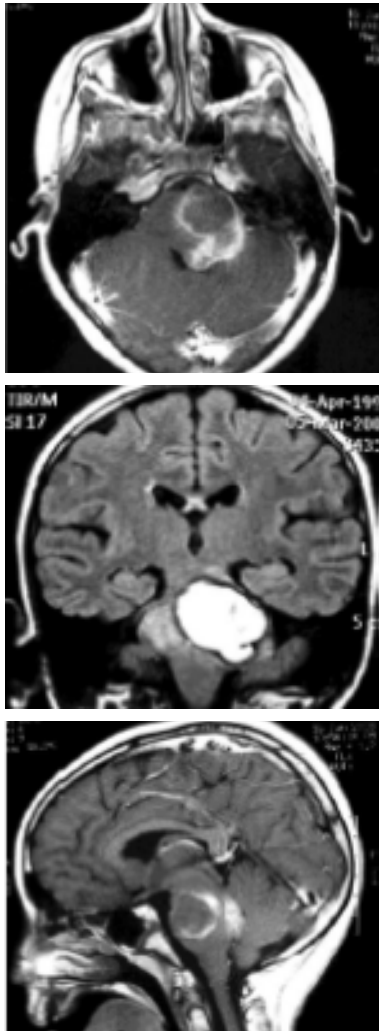


Figure 1 preoperative MRI showing a large pontine cavernoma with hemorrhage and surrounding hemosiderin ring, the IVth ventricle is compressed

The patient was extubated in the ICU, 6h after the surgery and the first exam showed VIII, IX and X left cranial nerves palsy. The motor deficit and the cranial nerves palsy showed partial remission at discharge on the 7th day postoperative.

At 3 weeks follow up, nearly complete remission of the right hemi paresis and partial remission of the VI, VII, VIII, IX and X left cranial nerves deficit were observed and the Karnovsky score increased to 60.

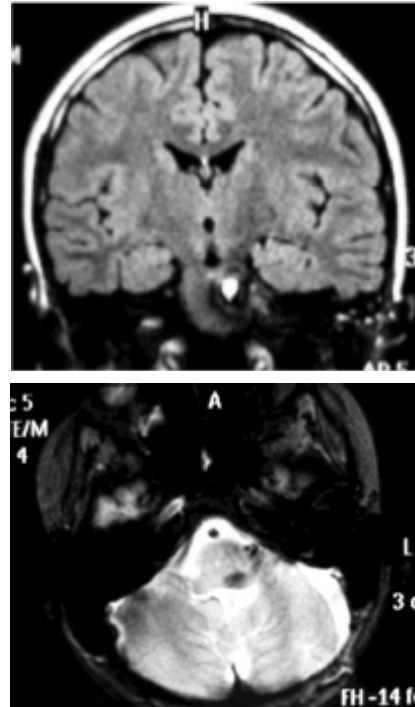

Figure 2 3 weeks postoperative MRI showing residual cavernoma in the left pons

Discussions and conclusion

The main objective of this type of surgery is complete tumor removal without damaging the corticospinal tract, so that the patient should leave the operating room without any new neurological deficits. This objective can be best achieved by a sorrow planning of the surgery in order to pick the the most suitable approach, which avoids lesions of the cerebellar nuclei, too much traction on the cerebellum or on the cranial nerves, and most important, that avoids any lesions to the structures in the floor of the IV-th ventricle or to the corticospinal tracts. Many approaches have been described that allowed a safe resection of brainstem cavernomas so the approach should be targeted on the location of the lesion in order to approach the cavernoma where it approaches the surface or appears on the

surface of the brainstem as was the case here (7, 8, 10, 11).

Spetzler et al (1) published a series of 40 pediatric cases of brainstem cavernomas followed for a median of 30 months, 25% of them left with new neurological deficit and observed that the lesions are bigger in children than in adults, and also the regrowth rate from residual lesion is higher. Also in our case the cavernoma was large but no regrowth was evident at 3 years follow up.

This lesion was bulging in the CP angle and the nervous tracts were displaced antero and posteromedial so the approach to its surface was straightforward. Also the hematoma made enough space in the CP angle to make this retrosigmoid approach the best choice (9). The best surgical approach differs according to the location of the cavernoma, many authors use complicated skull base approaches in order to have the best exposure of the lesion and surrounding neural structures, in this way having a comfortable resection. As much as possible, traction should be avoided with this kind of lesions, and the dissection should be done in a lateral to medial fashion using a blunt or sharp micro instruments as appropriate for the surgeon, avoiding traction on pons that can easily result in a low heart rate, much dangerous in children than in adults. Bradycardia is a major indication for avoiding further resection. Brain stem cavernomas are very difficult lesions to operate. Surgery is indicated when these patients develop neurological deficit consecutive to hemorrhage, with the goal of complete resection and improvement of presenting symptoms on follow up.

References

1. Abla A.A., Lekovic G.P., Garrett M., Wilson D.A., Nakaji P., Bristol R., Spetzler R.F. Cavernous malformations of the brainstem presenting in childhood: surgical experience in 40 patients, *Neurosurgery*. 2010 Dec; 67(6):1589-98; discussion 1598-9.
2. Amin-Hanjani S., Ogilvy C.S., Ojemann R.G., Crowell R.M., Risks of surgical management for cavernous malformations of the nervous system. *Neurosurgery* 42:1220-1227, 1998.
3. Bertalanffy H., Benes L., Miyazawa T., Alberti O., Siegel A.M., Sure U., Cerebral cavernomas in the adult: Review of the literature and analysis of 72 surgically treated patients. *Neurosurg Rev* 25:1-53, 2002.
4. Bertalanffy H., Kühn G., Scheremet R., Seeger W., Indications for surgery and prognosis in patients with cerebral cavernous angiomas. *Neurol Med Chir (Tokyo)* 32:659-666, 1992.
5. Bertalanffy H., Gilsbach J.M., Eggert H.R., Seeger W., Microsurgery of deepseated cavernous angiomas: Report of 26 cases. *Acta Neurochir (Wien)* 108:91-99, 1991.
6. Black P.McL., Moriarty T., Alexander E., Stieg P., Woodard E.J., Gleason P.L., Martin C.H., Kikinis R., Schwartz R.B., Jolesz F.A., Development and implementation of intraoperative magnetic resonance imaging and its neurosurgical applications. *Neurosurgery* 41:831-845, 1997.
7. François P., Ben Ismail M., Hamel O., Bataille B., Jan M., Velut S., Anterior transpetrosal and subtemporal transtentorial approaches for pontine cavernomas, *Acta Neurochir (Wien)*. 2010 Aug; 152(8):1321-9; discussion 1329. Epub 2010 May 4.
8. Garber S.T., Couldwell W.T., Resection of an inferior pontine cavernous malformation using a far-lateral transcondylar approach.
9. Gorgan M., Neacsu Angela, Bucur Narcisa, Pruna V., Giovani A., Dediu A., Update on the natural history of infratentorial cavernous malformations, *Romanian Journal of Neurosurgery*, 2011 XVIII, nr 3.
10. Ohue S., Fukushima T., Friedman A.H., Kumon Y., Ohnishi T., Retrosigmoid supraflaccular transhorizontal fissure approach for resection of brainstem cavernous malformation, *Neurosurgery*. 2010 Jun; 66 (6 Suppl Operative):306-12; discussion 312-3.
11. Ohue S., Fukushima T., Kumon Y., Ohnishi T., Friedman A.H., Surgical management of brainstem cavernomas: selection of approaches and microsurgical techniques, *Neurosurg Rev*. 2010 Jul; 33(3):315-22; discussion 323-4. Epub 2010 Apr 1.