

## Our center experience in carotid artery stenting

A. Chiriac, N. Dobrin, I. Nedelciuc, Z. Faiyad, I. Poată

Clinic of Neurosurgery

“Gr.T. Popa” University of Medicine and Pharmacy Iasi, Romania

“Prof. Dr. N. Oblu” Clinical Emergency Hospital, Iași, Romania

Clinic of Cardiology, “G. Georgescu” Cardiology Institute, Iasi, Romania

### Abstract

Carotid artery stenting becomes first intention treatment in atheromatous carotid artery stenosis. In this article we present our first experience in carotid artery stenting on 27 consecutive patients. Demographic, clinic and angiographic data are retrospectively reviewed and technical success rate and postprocedural complication are statistically compared with literature trial studies.

**Keywords:** carotid stenosis, stroke, stents

### Introduction

Cerebrovascular events due to atherosclerotic carotid artery disease represent 20 percent of all strokes. Percutaneous transluminal carotid angioplasty with stent becomes today the most used therapy for atheromatous causes of stenotic and occlusive disease of the internal carotid artery. Previously study trials have shown that the endovascular stenting treatment of carotid artery stenosis is an optimal therapy for carotid artery stenosis more than 70% in asymptomatic patients or more than 50% in symptomatic patients.

In this study we report the efficiency, clinical and imaging results in the stenting treatment of 27 consecutive patients with internal carotid artery stenosis.

### Methods

All 27 patients included in the study benefit of an endovascular carotid stenting for unilateral or bilateral carotid artery stenosis between May 2010 and October 2011. The first evidence of carotid stenosis was identified on non-invasive test (Doppler sonography, angio-CT and angio-MRI) in 20 patients and on invasive catheter angiography (in time of coronary and peripheral angiography) in 7 cases. Careful neurological evaluation was performed in all patients before endovascular intervention, 24 hours after procedure and at the periodical control at 2 and 6 months by the same neurosurgeon specialists. Preprocedural cerebral CT scans were performed for the patients with permanent or remitted neurological deficits after a previously stroke (between 6-12 months). Postprocedural cerebral CT scan was only performed in the patients with neurological deficits installed after a stroke suffered at more than 2 weeks before the procedure. Control catheter angiography was performed earlier than one year for the 3 patients who benefit from a bilateral carotid stenting in two steps and after one year in 5 patients.

### Stenting procedure

Before the procedure all patients received 100 mg acetylsalicylic acid and 75 mg clopidogrel for at least 3 days. 300 mg clopidogrel loading dose was administrated on the same day of the procedure for those patients with no antiplatelet medication. A dose of 5000 units of heparine was administrated during the procedure to maintain an optimal activated clotting time between 200 and 250. 75 mg clopidogrel and 100 mg acetylsalicylic acid were continued to be administrated for at least 6 months. For bradycardia and hypotension reaction prevention, potentially associated with carotid dilatation, 1 mg of atropine was intravenously administrated.

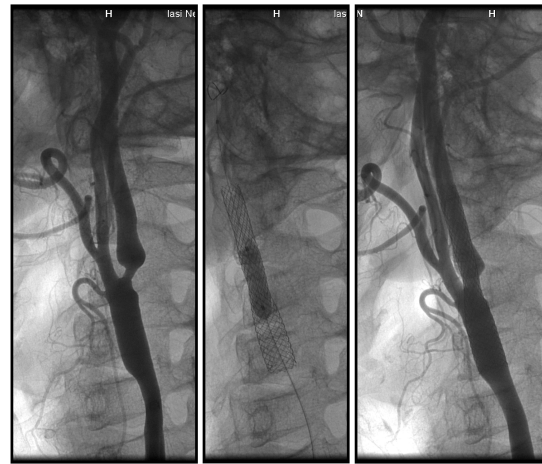
Arterial blood pressure, EKG and O<sub>2</sub> saturation were continuously monitored during the procedures.

All procedures were performed under local anesthesia with 5% lidocaine infiltrated at the access site. A standard retrograde trans-femoral access through an 8F vascular sheath was used for all stenting procedures. Selective common carotid artery angiographies were obtained with an 8F Mach1, Boston guiding catheter. The guiding catheters were advanced into the common carotid artery on support of a hydrophilic guide wire (0.035in, "J" peak, 150cm length). After that, an angiographic examination of the stenotic carotid lesion in an optimal projection (clearly exposure of the carotid bifurcation) was done. Keeping this angiographic image as reference image on the secondary screen, an embolic protection device was thereafter employed. Two different embolic protection device were used, the Boston Scientific filter wire "EZ" in 6 patient and Abbott Emboshield NAV6 Embolic Protection System in 14 patients. In 8 cases a predilatation procedure of the severe stenotic lesion with a 2.5/20 mm balloon was necessary for a

safety embolic protection device passes (Table 3).

A self-expandable stent was placed over the atheromatous lesion. A Boston Scientific stent "Wallstent" was used in 8 cases and an Abbott Xact Carotid Stent System was used in 19 cases. 17 patients benefited by postdilatation for intra-stent blood flow optimization with a 5.5/30mm balloon. A final carotid angiographic exposure is performed (Figure 1).

All the patients were discharged at home at two days except 4 patients who were transferred to neurology.



**Figure 1** Angiography images with **A** ICA stenosis  
**B** intrastent balloon postdilatation  
**C** ICA dilated with stent

**TABLE 1**

#### Criteria for high-risk patients:

Pathologic Criteria	Cases
Age over 80 years	-
History of open heart surgery	-
Need for open heart surgery within 30 days	1
Multi-vessel atherosclerosis	2
Left ventricular dysfunction with ejection deficit fraction <40%	-
Old myocardial infarction with coronary stenting	3
Severe bronchopulmonary disease	-
Severe renal diseases	-
Significant contralateral carotid artery disease	6
Previous endarterectomy	-
	<b>12</b>

**TABLE 2**  
**Demographic, clinic and angiographic dates**

Criteria	No.
Age (Mean ± SD) years	61 ± 12
Gender (male / female)	18 / 9
Symptomatic / Asymptomatic	15 / 13
Hemiplegia / Hemiparesis	3 / 4
Aphasia – disartria	5
Mean lesion length (mm)	18
Mean severity of stenosis (%)	84
Bilateral carotid disease > 70%	5
<b>Contralateral carotid occlusion</b>	2

**TABLE 3**  
**Procedural characteristics and angiographic results**

Characteristics	No.
Embolic protection device (Boston/Abbott)	6 / 14
Stent (Boston/Abbott)	8 / 19
Predilatation	8
Postdilatation	17
<b>Residual stenosis (Mean ± SD)</b>	14 ± 6

**Results**

The demographic data of the study group shows an average age of 61 years (range from 48 to 72) and gender distribution of 18 men and 9 women. In terms of clinical aspects 12 patients were classified as high risk patients (6 suffered from significant contralateral carotid artery disease, 3 had old myocardial infarction with coronary stenting and 2 had multi-vessel atherosclerosis. One asymptomatic patient, who referred to us for carotid stenting treatment, required an open heart surgery in the following 30 days and one was known with left ventricular dysfunction with ejection deficit fraction under 40% (Table 1, 2).

Good postdilatation results were

obtained with residual stenosis less than 20% in all cases (the mean residual stenosis was 14%). No subintimal dissection, arterial disruption or contrast extravasations were noted. Neurological examinations at two days and 2 months postinterventional show no major modification comparative with the admission neurological status. Mild headache, lightheadness, dizziness or minor discomfort at the neck level, remitted completely in 24 hours were observed in 4 patients. Three patients showed episodes of significant bradycardia after balloon dilatation. New stroke or deaths were not encountered at 6 months after the procedure, except one patient who experienced a temporary aphasia at 4 month.

**Discussion**

Our experience concerning the carotid angioplasty with stent placement suggest that this technique it's an efficient therapeutic alternative especially in those patients considered to be at higher risk for stroke. The short-term neurological and angiographic results of our patients series are well correlated with other largest series reports from the literature. Data from the most recent randomized trials reported a technical success rate of 98.4%, a minor stroke rate of 2.7%, a major stroke rate of 1.49%, and a mortality rate of 0.88% (3).

A rigorous comparison of the results provided by this study with those obtained from the published studies could not be done because of differences in patient's number, neurological status at the admission and upper age limit.

The European Carotid Stent Trial (ECST) had reported an overall severe stroke and death rates of 7% in patients with symptomatic patients while the

Asymptomatic Carotid Atherosclerosis Study (ACAS) had reported periprocedural stroke and death rates of 2.3% in lower-risk subset (3). Although, in our patients study there was no statistic difference between symptomatic group and the asymptomatic group, our results been more close to those obtained in ACAS.

Some studies recommend the use of carotid protection device even if an intr-stent balloon postdilatation is not necessary. Although, these studies mention a periprocedural increased risk due to not using a carotid protection device and during balloon postdilatation, we have not encountered such problems. We believe that the use of a carotid protection device for carotid stenting without balloon postdilatation is not absolutely necessary, and a reduction of balloon inflation time will minimize the disruptions of cerebral blood flow, especially in patients with contralateral carotid occlusion.

The technical success rate of our 27 consecutive carotid stenting procedures was 100%. The mean residual stenosis immediately after stent implantation was 14% indicating the feasibility of this procedure under optimal choice of materials and experienced specialist.

### Conclusions

The carotid artery stenting was proven to be an optimal treatment for most of the patients with symptomatic carotid stenosis or asymptomatic severe carotid stenosis

(>70%). We need for a long-time study including a greater number of patients in order to make a correct statistical analysis with other multicenter studies. Finally, our study could be a guide for the other neurosurgeon colleagues who wants to implement this treatment technique in their departments.

### References

1. Brahmajee K, Nallamotheu, Hitinder S. Gurm, Henry H. Ting, Philip P. Goodney, Mary A. M. Rogers, Jephtha P. Curtis, Justin B. Dimick, Eric R. Bates, Harlan M. Krumholz, John D. Birkmeyer (2011) Operator Experience and Carotid Stenting Outcomes in Medicare Beneficiaries, *JAMA*, 306(12):1338-1343;
2. Chaer RA, Makaroun MS. (2008) Evolution of carotid stenting: indications, *Semin Vasc Surg. Jun*; 21(2):59-63;
3. Haji-Zeinali Ali-Mohammad, Kazemi-Saleh Davood (2006) An experience with angioplasty and stenting of carotid artery stenosis with embolic protection devices, *Arch Iranian Med* 2006; 9 (2): 138 – 143;
4. Knur R. (2009) Carotid artery stenting: a systematic review of randomized clinical trials, *Vasa. Nov*; 38 (4): 281-91.
5. Giovanni S, Roberto G, Francesco V, Enrico P, Sebastiano F, Matteo S, Alessio S, Carlo AR, Massimiliano DP, Eleonora G. (2009) Carotid artery stenting : a single-centre experience with up to 8 years> follow up. *Eur Radiol* 19:982-989;
6. Namazi Mo. Hassan, Mohammadi Af., Safi M., Vakili H., Saadat H., Amini Ad. (2010) Carotid Artery Stenting: A Single-Center Experience, *J Teh Univ Heart Ctr* 4 (2010) 188-193;
7. Verzini F, Cao P, De Rango P, Parlani G, Maselli A, Romano L, Norgiolini L, Giordano G. (2006) Appropriateness of learning curve for carotid artery stenting: an analysis of periprocedural complications. *J Vasc Surg* 44:1205-1211;
8. Yun WS, Kwun WH, Suh BY. (2011) The early and mid-term results of carotid artery stenting in high-risk patients, *J Korean Surg Soc.* Apr;80(4):283-8.