

Personal experience in lumbar spinal stenosis (LSS)

G. Iacob, M. Craciun

Clinic of Neurosurgery, Universitary Hospital Bucharest România

Motto: "Outcome may be improved through a more careful selection of patients and an adequate surgical decompression" - Deyo R.A. et al. (11)

Abstract

Objective: To investigate the effectiveness of our strategy in lumbar spinal stenosis. This is based on the following: precise clinical radicular description of the level of claudication by electrodiagnosis, fine neuroradiologic studies, microsurgical decompression, assessment of the factors which might influence the outcome.

Methods: The study was performed on 145 patients who underwent decompression in the last 8 years: 95 males, 50 females, mean age 65 yrs (50-81). Comorbidities were carefully considered when choosing the surgical procedure, especially in elderly patients; an initial conservative approach of 3 weeks was used for most patients. Concerning etiology: 105 were degenerative, 16 post trauma, 24 others. Our cases included: 48 cases of single, focal stenosis, 97 diffuse (52 cases in 2 levels and 45 cases in 3 or more levels); 50% were graded as severe and evolved within 6 weeks, 30% were graded severe to moderate and 20% were moderate after a 2 month evolution; 15 were central, 17 lateral, 13 foraminal and 100 mixed. Precise clinical radicular description of the level of claudication by electrodiagnosis was used in all patients, MRI studies – 115 patients, CT studies - 30 patients, plain static x-rays of

lumbar spine, dynamic flexion and extension x-rays of lumbar spine – all patients; disability degree evaluation: Oswestry Disability Index, pain (visual analog scale and analgesic consumption), functional improvement (Neurogenic Claudication Outcome Score), walking performance and instability degree (Pre-op and intraoperative) to all patients.

We used a 4-5 cm incision for focal stenosis, 5-10 cm incision for 2-3 levels, C-arm for localization, high speed drill, cutting and diamond burrs, microscope, microinstruments, fenestration and medial facet undercutting to ensure an adequate root decompression. We excised the ligamentum flavum in the lateral recess which is often thickened. The lower lateral 6-12 mm of the lamina above and/or the superior lateral 3-9 mm of the lamina below were also resected to expose the root, the disc was excised and the posterior osteophytes were chiseled away with a fine micro chisel or diamond drill. In cases of focal stenosis we performed: foraminotomy, laminotomy, osteophylectomy, ligamentum flavectomy; diffuse/multilevel stenosis was approached as follows: laminotomies, foraminotomies, osteophylectomy, ligamentum flavectomy, medial facetectomy, fusion. In 24 cases we attempted a pedicle screw fixation and in

two cases Diam devices. No re-do surgery was required.

Results: One week after surgery, pain decreased in 87.9% of patients; nonsteroidal anti-inflammatory drug consumption and analgetics decreased in 81%. Two years after surgery, pain remained decreased in 79.8% of patients, Neurogenic Claudication Outcome Score decreased in 78.7% of patients and walking performance improved in 97.2% of patients. Patients who underwent both multilevel decompression or single - level decompression benefitted.

Conclusions: LSS surgery is functional, never preventive; the initial management should be non-surgical except for severe cases. Electrophysiological testing correlated with thorough neurological examination is more accurate than a radiological evaluation alone when choosing the roots to be decompressed. Microsurgical selective decompression accomplishes a good balance between bony and soft tissue decompression, while also maintaining spinal stability.

Keywords: lumbar spinal stenosis (LSS), microsurgical selective decompression

Introduction

The recent increase in the diagnosis of LSS resides not only in the improvement of neuroimaging tools but also in the progressive degenerative changes in intervertebral joints and ligamentous structures in the elderly. The latter eventually leads to spinal canal and neural foraminal narrowing (11)(17)(27). Despite progress in lumbar surgery on decompressive surgery and invasive fusion procedures, the risks and benefits of a surgical procedure in patients over 65 years old should be carefully considered (1) (5)

(7) (10) (11) (16) (17) (20) (22) (33) (36). The purpose of this paper was to present our approach in a field where there are no specific recommendations for surgical procedures, especially in this age group.

Methods

During the last 8 years, 145 patients underwent decompression and fusion for LSS: 95 males, 50 females, mean age 65 yrs (50-81). Patients with comorbidities were carefully weighted in the choice of a surgical procedure, especially patients over 65 years. EKG, cardiac echography, spirometry, abdominal echography, thoracic and abdominal CT scans were performed.


An initial conservative approach for 3 weeks was used in most patient. In 6 cases (4,13%) with cauda equine syndrome we performed an emergency surgery. 115 cases presented symptomatic lumbar stenosis resulting from progressive degenerative changes in intervertebral joints and ligamentous structures. This led to spinal canal and neural foraminal narrowing. Of these cases 23 patients had had previous lumbar surgery, 16 cases resulted post trauma, 2 presented spinal lipomatosis, 12 were constitutional. In 2 constitutional LSS we found a cervical stenosis as well. Our cases were classified as follows: 8 cases with single, focal stenosis, 97 diffuse (52 cases on 2 levels and 45 cases on 3 or more levels); 50% of cases with a severe evolution within 6 weeks, 30% severe to moderate and 20% moderate within 2 months; 15 were central, 17 lateral, 13 foraminal and 100 mixed.

The diagnostic techniques that we employed (Figure 1) were: clinical radicular description of the level of claudication by electrodiagnosis - all patients, MRI studies - 115 patients, CT studies - 30 patients,

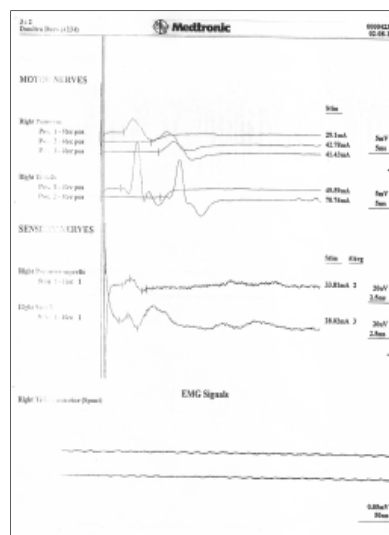
plain static x-rays of lumbar spine, dynamic flexion and extension x-rays of lumbar spine – all patients, disability degree evaluation: Oswestry Disability Index, pain (visual analog scale and analgesic consumption), functional improvement (Neurogenic Claudication Outcome Score), walking performance and instability degree (Pre-op and intraoperative) in all patients.

Our strategy was clearly explained to each patient: surgery has no effect on focal or diffuse low back pain, stiffness, “degenerative” illnesses; surgical choices; the availability of resources and facilities in our institution; our surgical aims were to achieve a good life quality and to restore functional capacity exerted on neurovascular compression, no pain: neurogenic claudication and mono or pluri radicular resting or in efforts pain, no subjective signs and neurologic deficit during walking, anesthesia technique, possible complications. All data and medical team are specified in the informed consent.

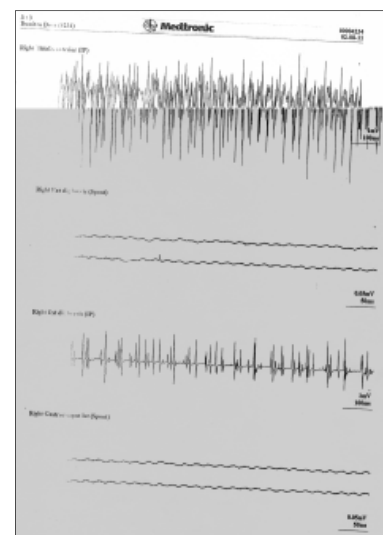
We used a 4-5 cm incision for focal stenosis, 5-10 cm incision for 2-3 levels, C-arm for localization, high speed drill, cutting and diamond burrs, microscope, microinstruments, fenestration and medial facet undercutting to ensure an adequate root decompression. We excised the ligamentum flavum in the lateral recess which is often thickened. The lower lateral 6-12 mm of the lamina above and/or the superior lateral 3-9 mm of the lamina below were also resected to expose the root, the disc was excised and the posterior osteophytes were chiseled away with a fine micro chisel or diamond drill. In cases of focal stenosis we performed: foraminotomy, laminotomy, osteophyctectomy, ligamentum flavectomy; diffuse/multilevel stenosis was approached as follows: laminotomies, foraminotomies, osteophyctectomy, ligamentum flavectomy, medial facetectomy, fusion. In 24 cases we attempted a pedicle screw fixation and in two cases Diam devices. No re-do surgery was required.



A



B



C

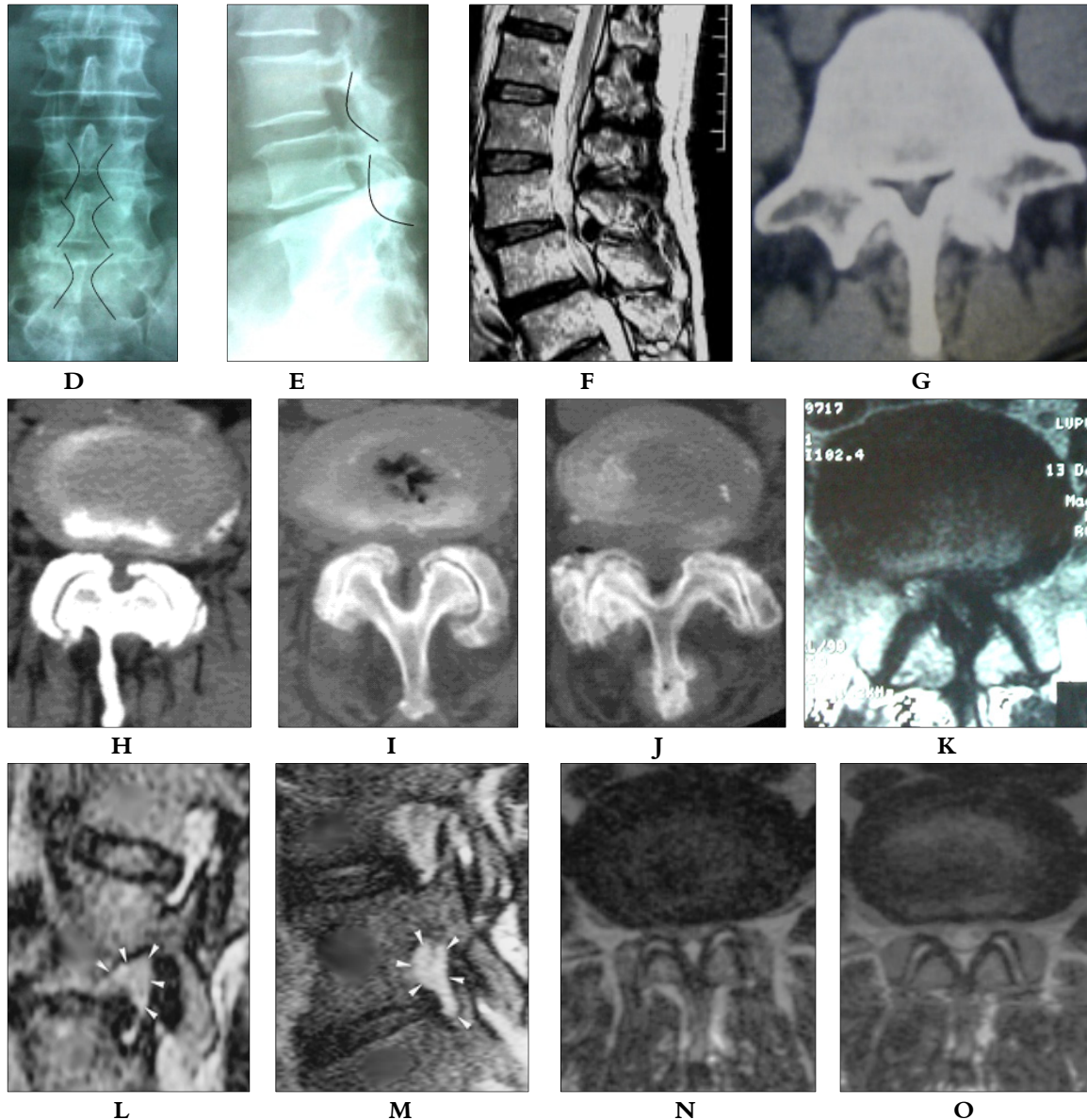


Figure 1 Main investigations in LSS: **A-C** electromyography for L5 motor deficit caused by a severe L4 stenosis, **D-E** plain static x-rays of lumbar spine in LSS stenosis, **F-I** MRI in central LSS, **J-K** LSS stenosis with disc herniation, **L-M** extension-flexion dynamic MRI to a patient explored abroad, **N-O** axial RM in extension-flexion

Results

One week after surgery, pain decreased in 87.9% of patients; nonsteroidal anti-inflammatory drug consumption and analgetics lessened by 81%. Two years after surgery, pain remained decreased in 79.8%

of patients, Neurogenic Claudication Outcome Score decreased in 78.7% of patients and walking performance improved in 97.2% of patients. Patients who underwent both multilevel decompression or single - level decompression benefitted

(Figure 2). In patients over 65 years we attempted decompression only, while also including any combination of discectomy and laminectomy without fusion. Medical complications occurred in 7 patients (4,82%): acute myocardial infarction, respiratory failure, pulmonary embolism, bacterial pneumonia, aspiration pneumonia, pneumonia of unknown etiology, crural thrombophlebitis, stroke and surgical complications in 11 patients (7,58%): wound complications (hemorrhage, hematoma or seroma), spondylodiscitis, CSF fistula. Previous spine surgery was associated with surgical complications: 3 spondylodiscitis, 2 CSF fistula, 2 cases with wound hematoma to patients on oral anticoagulants. No patient was reoperated for recurrent symptoms.

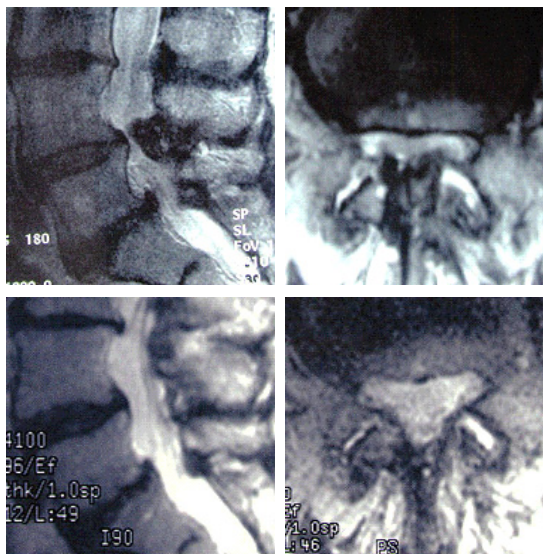


Figure 2 A-B pre and C-D post operatory MRI sagittal and axial sections, in a 68 years old case with severe L₄-L₅ LSS associated with a gr.1 L₅-S₁ spondilolisthesis

Discussions

LSS is defined as a focal or diffuse (multilevel) narrowing of the lumbar spinal canal \pm foramen \pm lateral recess,

causing nervous and vascular structures compression (16) (17). Although LSS had been described for over a century, it was first acknowledged as a distinct entity in 1954 by Verbiest (32). LSS is also known as a “loss of epidural reserve” and always it is important to elucidate the difference between “narrow” and “shrink” (27).

LSS is more frequently diagnosed due to improved neuroimaging procedures (17); it could be primary (congenital) – in less of 5% of cases; in 10-20% congenital LSS could be associated with a cervical stenosis too (17) and secondary (acquired) induced by non specific causes: degenerative changes (including central canal and lateral recess stenosis from posterior disk protrusion, zygapophyseal joint and ligamentum flavum hypertrophy, spondylolisthesis), specific: epiduritis, lipomatosis, neoplastic, iatrogenic changes result from surgical procedures such as laminectomy, fusion and discectomy; systemic processes that may be involved in secondary stenosis include: Paget disease, fluorosis, acromegaly and ankylosing spondylitis.

LSS could be classified according to posture: static or dynamic LSS according to ortostatic or sitting posture (35) (37) and anatomical criteria: central - due to hypertrophic spurring, bony projection or ligamentum flavum/laminar thickening, medial - secondary to inferior articular process hypertrophy, lateral - secondary to superior articular process hypertrophy, fleur de lis (clover leaf): laminar thickening with subsequent posterolateral bulging; on a level, segmentary (uni or bilateral), diffuse on/or several levels (16) (17).

In our clinical study 115 patients presented progressive degenerative changes in intervertebral joints and ligamentous

structures, leading to spinal canal and neural foraminal narrowing. Of these 23 had had previous lumbar surgery, 16 resulted post trauma, 2 presented with spinal lipomatosis, 12 were constitutional. In 2 constitutional LSS we found a cervical stenosis as well. Our cases were classified as follows: 8 cases with single, focal stenosis, 97 diffuse: 52 cases on 2 levels and 45 cases on 3 or more levels; 50% of cases with a severe evolution within 6 weeks, 30% severe to moderate and 20% moderate within 2 months; 15 were central, 17 lateral, 13 foraminal and 100 mixed.

LSS pathophysiology explains several mechanisms of neural compression, pain and instability (12) (17).

Neural compression could occur anteriorly: disk protrusion or herniation, osteotic overgrowth: osteophytes and posteriorly: lamar & ligamentous hypertrophy, facet hypertrophy, synovial cyst, spinal lipomatosis, spondylolisthesis.

Pain is induced by: mechanical factors such as: venous congestion, ischaemia (+/- microcirculation anomalies), compression radiculopathy, instability. The release of cytokines in inflammatory processes of facet joints (17) also triggers pain mechanisms, especially when the disc is involved (nucleus pulposus). The instability could be generated by the loss of discal integrity, ligamentous integrity, facetal integrity, supportive integrity, paraspinal and abdominal muscle tone and power; leading to: spondylolisthesis and scoliosis.

LSS includes mechanical instability without clinical signs and symptomatic instability with intermittent pain associated with clinical signs. Instability was defined by Panjabi (35) as: "the loss of the spine's ability to maintain its patterns of displacement, under physiologic loads so

there is no initial or additional neurologic deficit, no major deformity and no incapacitating pain". The degenerative process cannot be prevented by diet, exercise, lifestyle; a slow progression appears to occur in all affected individuals. In addition no clear correlation has been found between LSS and race, occupation, sex, body type, symptoms of stenosis.

LSS symptoms (17) may be: focal or diffuse low back pain and/or stiffness, radiculopathy, weakness, numbness or tingling of the legs, neurogenic claudication (up to 94%) leading to reduced walking capacity and mobility, rare cauda equina syndrome, rare bladder/bowel dysfunction. Patients walk in flexion and prefer to sit and lean forward. Physical examination findings (12)(17)(27) are insufficient when determining the presence or absence of LSS; these may reveal: positive straight leg raising (55 - 84.2%), sensory impairment (51.2 - 63.6%), motor deficit (35.7 - 52.2%), reflex changes (36.7 - 51.8%). In our cases we found radicular signs in 125 patients especially in lateral, foraminal or mixed LSS, motor deficits in 53 cases, sensory impairment in all cases, few anatomo-cinical correlations especially in segmentary stenosis (17). Cauda equine syndrome was rare, in only 6 cases (4,13% of cases). No systematic worsening of LSS symptoms was present, as the evolution was variable in each case.

LSS was assessed using the following neuroimagistic exams: plain static x-rays of lumbar spine with orientative value only; dynamic flexion and extension x-rays of lumbar spine to find an instability; CT lumbar scan indicated LSS if canal surface was < 145 mm², the saggital antero-posterior diameter < 12 mm if the axial section passed through the inferior part of

the pedicles, the transverse diameter interarticular process was < 15 mm on a axial section passing through the discs, dynamic MRI (37) involving saggital, axial or frontal sections of upright flexion and extension concerning surface, height and conflict nature; bone scan; CT Myelogram (17).

The diagnostic procedure was also based on: the precise clinical radicular description of the level of claudication by electrodiagnosis in all patients, MRI studies in 115 patients, CT studies in 30 patients, plain static x-rays of lumbar spine, dynamic flexion and extension x-rays of lumbar spine, disability degree evaluation: Oswestry Disability Index, pain (visual analog scale and analgesic consumption), functional improvement (Neurogenic Claudication Outcome Score), walking performance and instability degree (Pre-op and intraoperative) in all patients.

The natural evolution of all cases of lumbar spinal stenosis is not well understood. No correlation has been found between the time elapsed and the systematic progressive worsening. The evolution of LSS within 49 months (17)(21) is variable. Literature data disclosed that 70% of cases display unchanged symptoms. Improvements also including the walking ability are present in 15%. Worsening of symptoms occurs in 15% of cases. The 2006 Cochrane Database Sys.Rev (cited by 27) devised no specific recommendations although surgical treatment could alleviate pain and improve functional capacity. Only 3 randomized prospective controlled trials have approached the surgical vs nonsurgical treatment (2) (24) (34). These revealed no short term correlation between the patient's outcome and the surgery timing: early vs

late surgery. Moreover an initial non-surgical approach was advisable for most patients. Only one third of patients with a surgical intervention also responded to non-surgical treatment. The latter rendered satisfactory results in 70% of cases at 6 months and 57% at 4 years follow up.

The treatment choice in LSS should consider the following: (2-7) (9) (16-18) (22) (27) (28):

- a medical treatment should precede the surgical one
- there is no recommendation referring to the timing of surgery, except motor deficit, cauda equina syndrome with bladder/bowel dysfunction.
- it is important to inform the patient about the difference between lumbar pain and the diagnosis of radicular syndrome and that surgery is not effective in lumbar pain.
- the number of nerve roots requiring decompression is often smaller than what appears in radiological studies. Therefore surgical procedures should not be based on X-ray studies alone.
- the slow onset of neurogenic claudication is generated by an imbalance between the capacity of the spinal canal and its contents. This mostly involves a particular side and motion segment/s rather than multiple bilateral radiological levels.
- outcome could be improved by a careful selection of patients and an adequate surgical decompression. The latter implies a perfect correlation between the anatomical and clinical patterns as well as concordant results between the electrophysiological impairment test and the dermatomal pain distribution and myotomal muscle weakness after claudication.

The evaluation for surgical treatment should regard each case individually. It

should always consider the age, comorbidities, previous trials of conservative therapy and specific - degree of stenosis (MRI), neurological deficits and degree of disability (Oswestry Disability Index, Visual Analog Score for Pain, walking distance, daily life activities), the degree of instability. Other conditions for treatment evaluation include the patient's expectations (31) and the surgeon's experience. The latter could predict failure or intolerance to conservative therapy (34). Patients selected for operation could be classified as follows (3) (4) (12) (17):

A. incidental finding of LSS including those with no limitation of life style and not worried about symptoms. Patients in this category should be informed about LSS findings and carefully monitored. Treatment should be initiated for any comorbidities or other conditions responsible for symptoms of stenosis. Low back pain could be treated with NSAID's, mainly selective cox 2 inhibitors.

B. symptomatic LSS with mild or moderate, persistent or worsening symptoms of neurogenic claudication and/or radiculopathy despite conservative therapy for at least 3 months (massage, ultrasound, TENS, braces or supports, acupuncture, biofeedback, hot or cold packs, traction, or chiropractic manipulation gives symptomatic relief of radicular or low back pain, physical therapy - avoid hyperextension and side bending, general reconditioning of spinal and abdominal musculature and ligaments), minimal comorbidities with radiologically proved severe stenosis, reducing walking distance and daily life activities: previous studies found poor correlations between symptoms and the degree of stenosis - level B recommendation. Better correlations

were found between the severity of symptoms and the surgical outcome - level B (17). In these patients there are options for early surgical management: the surgeon experience could predict failure of conservative therapy or to those requesting patients failing or intolerant to conservative therapy, patients with associated instability (see dynamic IRM) and neurological deficit, rare in emergency for cauda equina syndrome (17).

C. symptomatic LSS in patients with comorbidities that increase the surgical risk such as pulmonary diseases, unstable cardiac status, morbid obesity, severe osteoporosis, extremely advanced age. In such cases a conservative treatment is desirable, to use adaptive techniques for restoring mobility, to utilize rehabilitation services (27).

The surgical aims in LSS are (3) (6) (7) (15) (17): to alleviate symptoms, restore functional capacity acting on neuro-vascular compression, no pain: neurogenic claudication and mono or pluri radicular resting or in efforts pain, no subjective signs and neurologic deficit during walking, to normalize daily life activities, to achieve a good quality of life.

The patient should be well informed that surgery has no effect on focal or diffuse low back pain and/or stiffness (31), "degenerative" illnesses; he should be aware of the surgical choices and resources and facilities available in our institution as well as of the stabilization that could be required if facet and discal anatomy is compromised. The surgeon should choose the best operative technique, to avoid reintervention (and not for prevention), to continue with current best practice - surgical expertise and experience for patient selection & for surgical skills.

The surgical strategy in LSS (17) (18):

1. decompression is not recommended in cases of dynamic stenosis: instability, hypermobility

2. the current surgical options are microsurgery - "the gold standard" and endoscopy. (Endoscopy Guidelines ISMISS – feb. 2008). Microsurgery offers the following advantages when compared to macrosurgery (17) (23) (29): it minimizes tissue disruption, time of surgery, post operative morbidity, length of hospital stay; smaller incisions, less tissue trauma, minimal blood loss, earlier return to previous activities, easier operative approach in obese patients, local or regional anesthesia combined with conscious sedation can be used, less postoperative pain medication is required.

3. the roots to be decompressed: all roots should be decompressed in cases of central lumbar canal stenosis even with unilateral radiculopathy, during walking or effort(19); in cases of bilateral lateral recess stenosis with unilateral radiculopathy, at one level both roots should be decompressed; cases of multilevel lateral recess stenosis, with unilateral radiculopathy imply radical fenestration and foraminotomy with decompression on the symptomatic side and level only; foraminal stenosis requires the decompression of the affected root.

4. regarding stabilization our aims are: to treat patients with severe symptoms and radiographic evidence of excessive motion (greater than 4 mm translation or 10° of rotation) who fail to respond to nonsurgical treatment) (10) (14) (30) and to prevent postoperative instability. Stabilization should be limited (17), never systematic or for associated lumbar pains. We used stabilization in patients with pre-operative instability (flexion-extension radiographs or

dynamic MRI), depending on the dimension of osteous resection, articular processes orientation – especially on anterior-posterior, to correct a deformity, to avoid hypermobility and to maintain lordosis and foraminal size. We performed stabilization in 24 cases, using pedicle screw fixation – Medtronic TSRH-3D and in two cases Diam devices.

5. the type of stabilisation to be used: arthrodesis and instrumentation could be performed using a rigid stabilization system with pedicle screw fixation in a classic procedure, percutaneously or with motion preservation: dynamic stabilization systems, facet arthroplasty: TFAS® Total Facet Arthroplasty System or with lumbar interspinous implants to unload the anterior column & reestablish the functional integrity of the posterior column: Colfex, Wallis, Diam and X-Stop.

LSS outcome (2) (3) (28) depends on age < 65 years, uniradicular deficit, simultaneous disc hernia, anatomic and clinical correlations of the root (s) to be decompressed, microsurgery, overall rating: improved (85%), some improvement (10%), no improvement (5%), worse (none). Mean follow up at 24 months indicated: walking distance improvement (95%), leg pain improvement (85%), weakness and numbness improvement (70%), on daily life activities: normal 82%, modification on life/work style (13%), stopped working (5%).

Despite possible complication of diverse etiology: infectious, neurologic, mechanic most surgically treated patients would again choose surgery (1) (2) (4) (13) (20) (21). For recurrent symptoms (17), patient selection should be based on clinical, radiological (contrast studies, dynamic MRI), electrophysiological studies (EMG

and NCS) of: residual stenosis at operative site due to inadequate first surgery, stenosis at adjacent levels to surgical site, new disc herniations, epidural and arachnoidal adhesions, instability and/or spondylolisthesis following first surgery.

Several techniques (7-9) (13) (17) (19) (20) (23) (25) (36) are used: partial decompressive lamino-arthrectomy uni/bilateral, complete facetectomy +/- discectomy; radical fenestration and foraminotomy, bilateral interlaminar fenestration and unroofing for the decompression of nerve roots through a unilateral approach, open door expansive lumbar laminoplasty, hemilaminotomy – arthrectomy with ligamentectomy & recess decompression, hemilaminotomy – arthrectomy several levels and unilateral lamino-foraminotomy, microendoscopic decompressive laminotomy, unilateral laminectomy for bilateral decompression, laminectomy – bilateral foraminotomy also known as “the recalibration” (it is mandatory to obtain consent for possible stabilization during the laminectomy procedure if facet and discal anatomy is compromised; 5% of laminectomies require stabilization in the end), the Wiltse approach with foraminotomy for isolated foraminal stenosis.

Our technique consists of a 4-5 cm incision for focal, 5-10 cm incision for 2-3 levels, C-arm for localization, high speed drill, cutting and diamond burrs, microscope, micro-instruments, fenestration and medial facet undercutting to adequate root decompression, the ligamentum flavum in the lateral recess often thickened is excised, the lower lateral 6-12 mm of the lamina above and/or the superior lateral 3-9 mm of the lamina below were resected to expose the root, the

disc is excised, posterior osteophytes are chiseled away with fine micro chisel or diamond drill. In 90 cases of one level focal stenosis we performed foraminotomy, laminotomy, osteophyctomy, ligamentum flavectomy;

Diffuse/multilevel stenosis on two levels (35 cases) and three levels (15 cases) required laminotomies, foraminotomies, osteophyctomy, ligamentum flavectomy, medial facetectomy. We have performed: foraminotomy in 138 cases, laminotomy in 112 cases, medial facetectomy in 47 cases, laminectomy in 16 cases.

Our results are comparable with literature data (17). One week after surgery, pain decreased in 87.9% of patients; nonsteroidal anti-inflammatory drug consumption and analgetics decreased in 81%. Two years after surgery, pain remained decreased in 79.8% of patients, Neurogenic Claudication Outcome Score decreased in 78.7% of patients and walking performance improved in 97.2% of patients. Patients who underwent both multilevel decompression or single - level decompression benefitted. In patients > 65 years we chose decompression only, including any combination of discectomy and laminectomy without fusion. We have had medical complications in 7 patients (4,82%): acute myocardial infarction, respiratory failure, pulmonary embolism, bacterial pneumonia, aspiration pneumonia, pneumonia with unknown organism, crural thrombophlebitis, stroke and surgical complications in 11 patients (7,58%): wound complications (hemorrhage, hematoma or seroma), spondylodiscitis, CSF fistula. Previous spine surgery was associated with surgical complications: 3 spondylodiscitis, 2 CSF fistula, 2 cases with wound hematoma to patients on oral

anticoagulants. No patient was reoperated for recurrent symptoms.

Conclusions

LSS surgery is functional and never preventive. The initial management of LSS should be non-surgical, except for very severe cases with cauda equina syndroms. The choice of the roots to be decompressed should not be based on the radiological evaluation. Better correlations with the neurological examination have been obtained for gold imaging standards such as MRI and dynamic flexion and extension X-rays as well as for electrophysiological testing. Surgical interventions should be adapted to the unique patho-anatomical situation in the persistently symptomatic patient. Selective decompression only at the neurological responsible level improved neurogenic intermittent claudication in the majority of patients. In addition unoperated radiological stenotic levels rarely became symptomatic on follow up. LSS surgical aims are: to minimize tissue damage, minimally invasive decompressive techniques adapted to the unique patho-anatomical situation in the persistently symptomatic patient (more than 80% of cases may be spared from a more extensive surgery), balance bony and soft tissue decompression while maintaining spinal stability. Stability should be limited, never systematic and never indicated for associated lumbar pains.

Logic dictates we should pursue and develop goals of minimally invasive surgery, anesthetic technique, supportive care and attempt to obtain evidence between conventional and newer techniques, to make more invasive surgery to old patients, for a better quality of life.

References

1. Aalto TJ et al. - Preoperative predictors for postoperative clinical outcome in lumbar spinal stenosis: Systematic review, *Spine* 2006, 31:E648-E663
2. Amundsen T, et al. - Lumbar spinal stenosis: conservative or surgical management? A prospective 10-year study, *Spine* 2000; 25:1424-35
3. Atlas S.J. al. - The Maine Lumbar Spine Study, part III. 1-year outcomes of surgical and nonsurgical management of lumbar spinal stenosis, *Spine* 1996; 21:1787-94.
4. Atlas SJ, et al. - Surgical and nonsurgical management of lumbar spinal stenosis: four-year outcomes from the Maine Lumbar Spine Study. *Spine* 2000; 25:556-562.
5. Atlas SJ, et al. - Long-term outcomes of surgical and non surgical management of lumbar spinal stenosis : 8 to 10 year results form Miane Lumbar Spine Study. *Spine* 2005 ; 30 : 936-43.
6. Atlas SJ, Delitto A. - Spinal stenosis versus non surgical treatment. *Clin Orthop Relat Res* 2006; 443: 198-207
7. Ausman J.I. - Spinal stenosis-what is the best treatment?, editorial, 2007 Elsevier Inc.2007.08.
8. Benz RJ et al. - Current techniques of decompression of the lumbar spine, *Clin Orthop Relat Res* 2001, 384:75-81
9. Cavusoglu H, et al. - Midterm outcome after unilateral approach for bilateral decompression of lumbar spinal stenosis: 5-year prospective study. *Eur Spine J* 2007, 16:2133-2142
10. Deyo R.A., Gray D.T., et al. - United States trends in lumbar fusion surgery for degenerative conditions. *Spine* 2005;30:1441-1445.
11. Deyo R.A., Mirza S.K., al. - Trends, Major Medical Complications, and Charges Associated with Surgery for Lumbar Spinal Stenosis in Older Adults, *JAMA*. 2010, April 7; 303(13):1259-1265
12. Fritz JM, et al. - Lumbar spinal stenosis: a review of current concepts in evaluation, management, and outcome measurements. *Arch Phys Med Rehabil* 1998 Jun; 79(6): 700-8
13. Fritzell P, Hagg O, Nordwall A. - Complications in lumbar fusion surgery for chronic low back pain: comparison of three surgical techniques used in a prospective randomized study. A report from the Swedish Lumbar Spine Study Group. *Eur Spine J* 2003;12:178-189.
14. Fritzell P, Hagg O, et al. and the Swedish Lumbar Spine Study Group. - 2001 Volvo Award winner in clinical studies: lumbar fusion versus nonsurgical treatment of chronic low back pain: a multicenter randomized controlled trial from the Swedish Lumbar Spine Study Group. *Spine* 2001;26:2521-2532.

15. Guiot B, et al. - A minimally invasive technique for decompression of the lumbar spine. *Spine* 2002, 27:432-438
16. Jacob G. - Stenoza canalului vertebral lombar, *Medicina Moderna*, 2002, vol IX, nr.2, 58-63
17. Iacob G., Craciun M. - Lumbar spinal stenosis (LSS): indications and operative treatment - the "Bucharest view", German-Romanian Course, Cluj-Napoca 24-25 May 2011
18. Irwin Z.N., Hilibrand A., et al. - Variation in surgical decision making for degenerative spinal disorders. Part I: lumbar spine. *Spine* 2005;30:2208-2213.
19. Iwatsuki K, Yoshimine T, Aoki M. - Bilateral interlaminar fenestration and unroofing for the decompression of nerve roots by using a unilateral approach in lumbar canal stenosis, *Surg Neurol* 2007;68:487-92
20. Jakola et al. - Clinical outcomes and safety assessment in elderly patients undergoing decompressive laminectomy for lumbar spinal stenosis: a prospective study, *BMC Surgery* 2010, 10:34
21. Johnsson KE, Uden A, Rosen I. - The effect of decompression on the natural course of spinal stenosis. A comparison of surgically treated and untreated patients. *Spine* 1991; 16:615-619.
22. Katz JN, et al. - Predictors of surgical outcome in degenerative lumbar spinal stenosis. *Spine* 1999, 24:2229-2233
23. Khoo L, et al. - Microendoscopic decompressive laminotomy for the treatment of lumbar stenosis, *Neurosurgery* 2002, 51 [Suppl 5]:S146-S154.
24. Malmivaara A, Slati P, et al. for the Finnish Lumbar Spinal Research group. - Surgical or nonoperative treatment for lumbar spinal stenosis? A randomized controlled trial. *Spine* 2007;32:1-8.
25. Mariconda M, et al. - Unilateral laminectomy for bilateral decompression of lumbar spinal stenosis: A prospective comparative study with conservatively treated patients, *J Spinal Disord Tech* 2002, 15:39-46
26. Martin BI, et al. - Reoperation rates following lumbar spine surgery and the influence of spinal fusion procedures, *Spine* 2007, 32:382-387
27. Marty M. - Canal lombaire étroit, rétréci ou mixte, Traitement conservateur ou chirurgical ?. 20e congrès français de rhumatologie 2007
28. North American Spine Society (NASS). Diagnosis and treatment of Surgery for lumbar spinal stenosis. Burr Ridge (IL): North American Spine Society (NASS); 2007 Jan., 262
29. Oertel M, et al. - Long-term results of microsurgical treatment of lumbar spinal stenosis by unilateral laminotomy for bilateral decompression, *Neurosurgery* 2006, 59:1264-1270
30. Sonntag VKH, Marciano FF. Is fusion indicated for lumbar spinal disorders? *Spine*. 1995;20(suppl):138S-142S
31. Verbeek J, et al. - Patient expectation of treatment for back pain. A systematic review of qualitative and quantitative studies. *Spine* 2004 ; 29 : 2309-18.
32. Verbiest H. - A radicular syndrome from developmental narrowing of the lumbar vertebral canal. *J Bone Joint Surg Br* 1954 ; 36-B : 230-7
33. Weinstein J.N., Lurie J.D., et al. - United States trends and regional variations in lumbar spine surgery: 1992-2003. *Spine* 2006;31:2707-2714.
34. Weinstein J.N., Tosteson T.D., et al. - Surgical versus nonsurgical therapy for lumbar spinal stenosis. *N Engl J Med* 2008;358:794-810.
35. White A.A., Panjabi M.M. - Clinical biomechanics of the spine, 2nd ed, Lippincott, Philadelphia, PA, 1990
36. Wilby M.J., Seeley H., Laing R.J. - Laminectomy for lumbar canal stenosis: a safe and effective treatment, *Br J Neurosurg*, 2006 Dec;20(6):391-5
37. Wildermuth S, et al. - Lumbar spine: quantitative and qualitative assessment of positional (upright flexion and extension) MR imaging and myelography. *Radiology* 1998 ; 207 (2) : 391-8.