

Spontaneous hematoma of the septum pellucidum and corpus callosum: a case report

Spyridon Roditis

PhD student in Neurosurgery, “Gr.T. Popa” University of Medicine and Pharmacy, Iasi
Laiko Hospital of Athens, Greece

Abstract

The hemorrhagic lesion in the septum pellucidum and corpus callosum is not common and it can be found in patients with brain trauma (diffuse axonal injury), aneurysms of the pericallosal artery, after ruptured arteriovenous malformations or intracranial tumors. A 59-year-old man, a chronic alcoholic, developed a little hematoma in the septum pellucidum and corpus callosum with subarachnoid haemorrhage on the tentorium and all explorations showed no cause of these. Evolution was favorable with conservative treatment.

Keywords: corpus callosum, septum pellucidum, splenial hematoma, spontaneous hematoma

Introduction

Hematoma of the septum pellucidum and corpus callosum have been found in patients with various conditions including brain trauma, aneurysms of the pericallosal artery or after ruptured of arteriovenous malformations, hemorrhage occurring in intracranial tumors or in virus-associated encephalitis with hemorrhagic fever etc.

Severe head injuries are often associated with rotational forces resulting diffuse axonal injuries. Shear injuries commonly

occur at gray-white matter junctions, but they are also found in the corpus callosum, centrum semiovale, in the basal ganglionic regions, brain stem and cerebellum. The thalamic and basal ganglia injuries are hemorrhagic in 50% of cases and the shear injuries of the corpus callosum are more often nonhemorrhagic. The hemorrhagic lesion in the corpus callosum is a rare feature in subarachnoid haemorrhage, which may result from aneurysms of the anterior communicating artery or pericallosal artery or after ruptured arteriovenous malformation or arteriovenous fistula.

Intracranial tumors like pituitary adenoma, glioblastoma multiforme and metastatic tumors are a well recognized but uncommon cause of intracranial hemorrhage. Hemorrhage occurring in glioblastoma multiforme are frequently deep into the hemisphere, basal ganglia or corpus callosum. Primary cerebral neuroblastoma of the corpus callosum is a cause of hematoma in the corpus callosum and of intraventricular hemorrhage.

Spontaneous hematoma of the septum pellucidum and corpus callosum is rare and the cause can be a micro arterio-venous malformation in the corpus callosum.

Case report

A 59-year-old man, a chronic alcoholic, had been admitted to our neurosurgical hospital

with episodic generalized tonic-clonic convulsions for the last three days, with intense headache and vomiting, and in a disoriented state in time. Patient had normal blood pressure, without history of arterial hypertension and no recent history of head injury. Age, the sex and chronic alcoholism are the only detected risk factors.

Cranial computer tomography demonstrated a hematoma in the septum

pellucidum and corpus callosum with subarachnoid haemorrhage on the tentorium. Magnetic resonance angiography and cerebral angiography (Seldinger technique) did not show any vascular cause of this hematoma into the septum pellucidum and corpus callosum, like aneurysms or ruptured arteriovenous malformation. (Figures 1, 2, 3 and 4).

The patient was treated conservatively: after initial antiedematous treatment, antiepileptic therapy and haemostatic therapy, the patient became conscious and further the patient's condition has improved gradually.

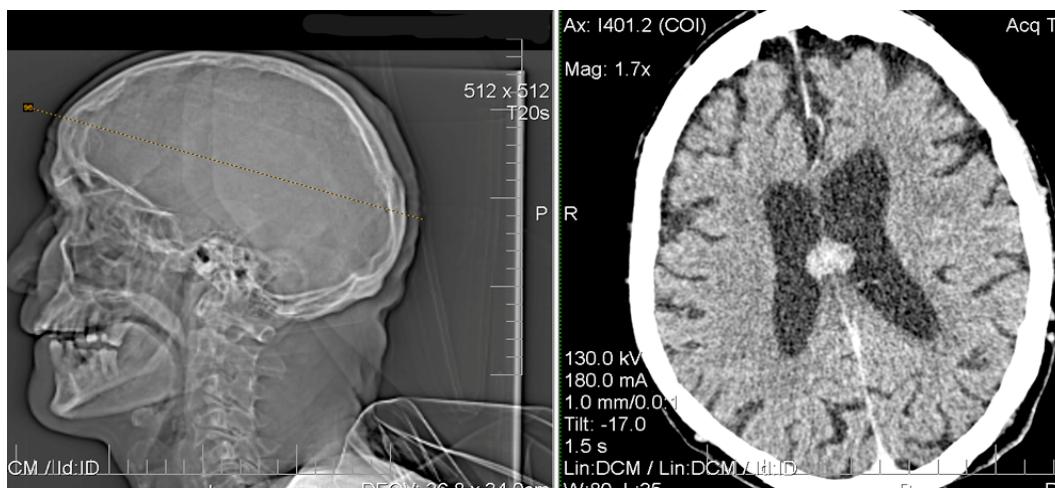


Figure 1 Computer tomography image shows a hematoma in the septum pellucidum and corpus callosum

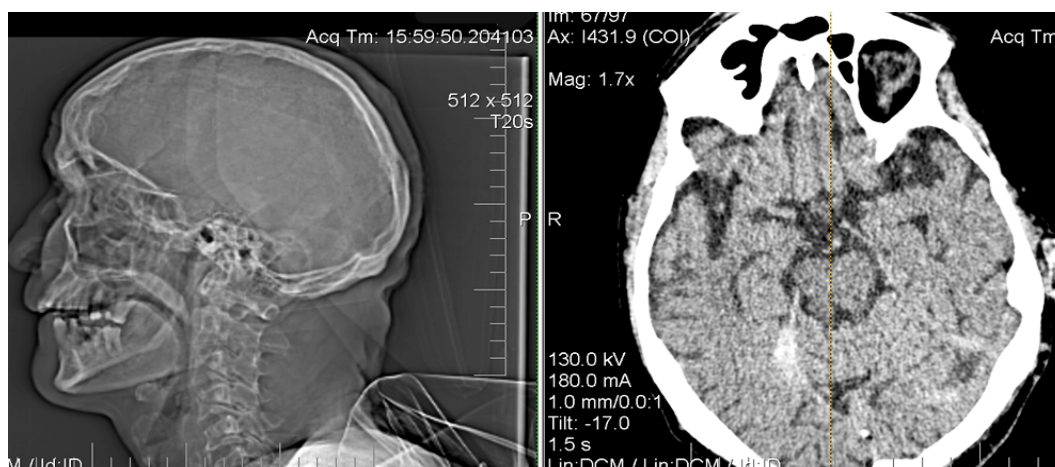


Figure 2 Computer tomography image shows a subarachnoid haemorrhage on the tentorium. (right side)

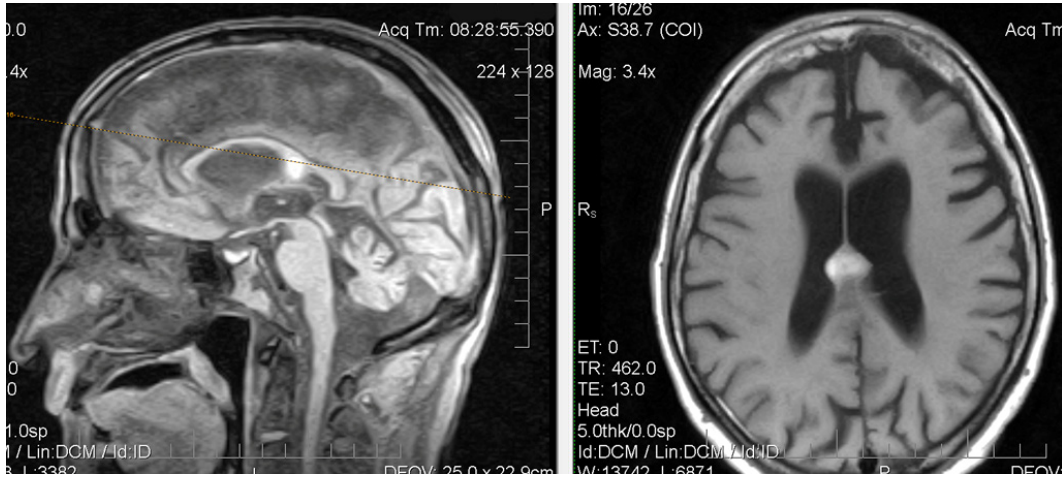


Figure 3 Brain MRI without contrast shows the hematoma in the septum pellucidum and corpus callosum

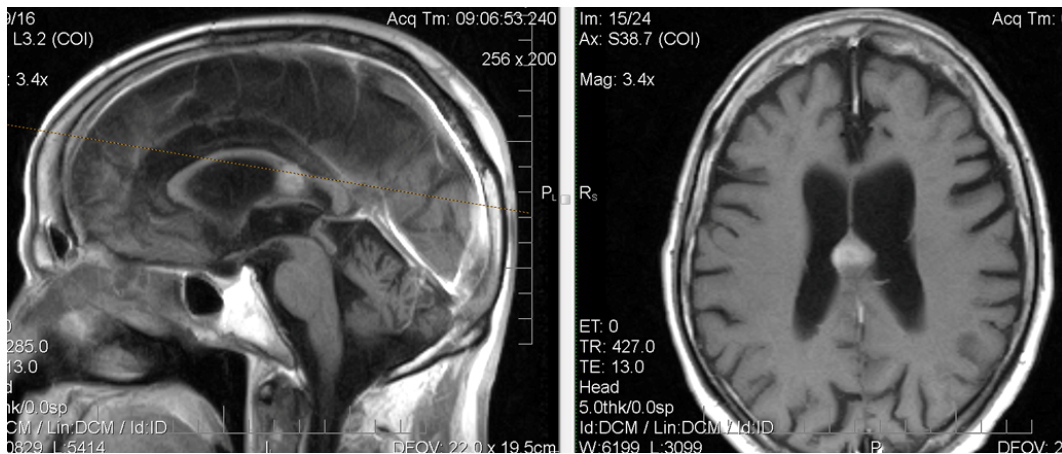


Figure 4 Brain MRI with contrast shows the hematoma in the septum pellucidum and corpus callosum and angio MRI did not show aneurysms or arteriovenous malformation

Discussion

Intracerebral hemorrhage occurs within the brain tissue itself and can occur spontaneously in hemorrhagic stroke or it can be caused by brain trauma. Other causes can be ruptured aneurysms or after ruptured of arteriovenous malformations, hemorrhage occurring in intracranial tumors or in virus-associated encephalitis with hemorrhagic fever. Intracerebral hemorrhage and can be lobar intracerebral hemorrhage or it may occur in other brain structures, such as the thalamus, basal ganglia, pons, or cerebellum (deep

intracerebral hemorrhage). Amyloid angiopathy is other cause of intracerebral hemorrhage in old patients and a very small proportion is due to cerebral venous sinus thrombosis.

Major risk factors for intracerebral hemorrhage include: high blood pressure, diabetes, alcoholic drinks and current cigarette smoking. Other factors that raise the risk of intracerebral hemorrhage include: blood and bleeding disorders (decreased levels of blood platelets, hemophilia etc.), liver disease (associated with increased bleeding risk in general) or

use of aspirin or anticoagulant medications.

Similarly, hematoma of the septum pellucidum and corpus callosum can be caused by abnormalities of the blood vessels (aneurysm or vascular malformation), high blood pressure (hypertensive intracerebral hemorrhage), protein deposits along blood vessels (amyloid angiopathy) or traumatic brain injuries. Other causes are hemorrhage occurring in intracranial tumors or in virus-associated encephalitis with hemorrhagic fever. Hemorrhage occurring in glioblastoma multiforme are frequently deep into the hemisphere, basal ganglia or corpus callosum also primary cerebral neuroblastoma of the corpus callosum is a cause of hematoma in the corpus callosum and of intraventricular hemorrhage. In some cases, no cause can be found.

In literature there are few reported cases of hematoma of the septum pellucidum and corpus callosum. Butt et al, 1985, reported hemorrhage into the septum pellucidum coexisting with intraventricular hemorrhage in preterm infants and Kanpolat and Mertol, 1987, reported hematoma of the septum pellucidum in adults secondary to trauma and hypertension. Authors showed that mass effect of the haematoma of septum pellucidum may block the foramen of Monro, leading to hydrocephalus and increased intracranial pressure. But Schulder, Hirano and Elkin, 1987, ask if the „caval-septal”hematoma exist.

Ogura et al., 1982 reported two cases of traumatic hematoma in the corpus callosum caused by blunt mechanical head trauma which were accompanied neither by skull fracture nor by scalp injury. The hematomas occupied from the genu to the body of the corpus callosum and they were verified by surgery.

Shigemori et al., 1986, reported five

cases with massive haematoma of the corpus callosum caused by blunt head trauma, the patients presented also concomitant intraventricular and subarachnoid haemorrhages or small haemorrhagic foci in the basal ganglia or thalamus. The authors noted that the sites of the impacts were the frontal and occipital areas which were close to the midline and above the level of the corpus callosum.

Jackson et al., 1993, analyzed 348 patients with aneurysmal subarachnoid haemorrhage resulted from aneurysms of the anterior communicating artery or pericallosal artery and they found haematomas in the corpus callosum in 8 cases (9 %). Authors considered that these haematomas appeared to result from passage of blood up through the cistern of the lamina terminalis into the septum pellucidum and thence into the ventral aspect of the anterior corpus callosum.

Sorimachi et al. 2010 presented three patients with hemorrhage in the splenium of the corpus callosum at two weeks after the onset of subarachnoid hemorrhage associated with acute hydrocephalus. Authors consider that splenial hematoma is a potential cause of neurological deterioration after surgery for subarachnoid hemorrhage, in addition to vasospasm, hydrocephalus, and rebleeding.

In 2006 Erbaş et al. reported a case of hematoma of the corpus callosum secondary to isolated inferior sagittal sinus thrombosis. Authors showed that isolated inferior sagittal sinus thrombosis is an extremely rare condition and it should be considered in the differential diagnosis of non-traumatic corpus callosum hematoma.

The presented patient had a limited bleeding of the septum pellucidum and corpus callosum with a small subarachnoid

haemorrhage on the tentorium. CT and MRI images show a relatively small volume of the hematoma which is oval-spherical in shape, developed in the splenius of the corpus callosum and extended lower in the septum pellucidum (in the cavum of the septum pellucidum). The simultaneous existence of this hematoma of the septum pellucidum and corpus callosum and of this subarachnoid hemorrhage suggests a common cause for these two hemorrhagic lesions, but history did not reveal head injury and angiographies showed no aneurysms or arteriovenous malformations. Also patient had normal blood pressure, without history of arterial hypertension and the only detected risk factors for a hemorrhagic stroke are age, the sex and chronic alcoholism. The evolution was favorable under conservative treatment.

Conclusion

This is one of the few cases of a spontaneous hematoma of the septum pellucidum and corpus callosum and the performed exploration did not reveal a cause of these hemorrhagic lesions.

Correspondence:

Dr. Spyridon Roditis
Laiko Hospital of Athens
AG.Thoma 17, T.K. 11527, Athens, Greece
sproditis@yahoo.com

References

1. Barth P G Space-occupying lesions associated with cavum septi pellucidi. <http://www.medlink.com/medlinkcontent.asp>
2. Erbaş G, Oner AY, Akpek S, Tokgoz N. Corpus callosum hematoma secondary to isolated inferior sagittal sinus thrombosis. *Acta Radiol.* 2006 Dec; 47 (10): 1085-8.
3. Jackson A, Fitzgerald JB, Hartley RW, Leonard A, Yates J. CT appearances of haematomas in the corpus callosum in patients with subarachnoid haemorrhage. *Neuroradiology.* 1993; 35(6):420-3.
4. Kanpolat Y, Mertol T. Haematoma of cavum septi pellucidi due to hypertension. *Acta Neurochir (Wien).* 1987; 89(3-4):135-6.
5. Kasahara T, Toyokura M, Shimoda N, Ishida A Cerebral hemorrhage restricted to the corpus callosum *Am J Physical Medicine & Rehabilitation* 2005, vol. 84, no5, pp. 386-390
6. Komatsu S, Sato T, Kagawa S, Mori T, Namiki T. Traumatic lesions of the corpus callosum. *Neurosurgery.* 1979 Jul; 5(1 Pt 1):32-5.
7. Lau LS, Bannan E, Tress B. Pseudotumour of the corpus callosum due to subarachnoid haemorrhage from pericallosal aneurysm. *Neuroradiology.* 1984; 26(1):67-9.
8. Mochizuki K, Ochi H, Ogura Y, Iino M, Kuroki H, Matoba R. A case of diffuse axonal injury in violent death. *Leg Med (Tokyo).* 2009 Suppl 1:S518-9.
9. Ogura K, Yamamoto I, Hara M, Suzuki Y, Nakane T, Watanabe M. Computerized tomography of the traumatic hematoma in the corpus callosum. Report of 2 cases. *No Shinkei Geka.* 1982 Dec; 10(12):1299-301.
10. Pinto JA, Melo JR, Pereira JR, Veiga-Pires JA. Haematomas of the septum pellucidum. Aetiology and incidence. *Rof.* 1988 May; 148(5):591-3.
11. Schulder M, Hirano A, Elkin C. "Caval-septal" hematoma: does it exist? *Neurosurgery.* 1987 Aug; 21(2):239-41.
12. Shigemori M, Kojyo N, Yuge T, Tokutomi T, Nakashima H, Kuramoto S. Massive traumatic haematoma of the corpus callosum. *Acta Neurochir (Wien).* 1986; 81(1-2):36-9.
13. Sorimachi T, Yajima N, Sasaki O, Koike T, Fujii Y. Hematoma in the splenium of the corpus callosum in the subacute stage of subarachnoid hemorrhage--three case reports. *Neurol Med Chir (Tokyo).* 2010; 50(3):209-12.
14. Takatoshi S, Naoki Y, Osamu S, Tetsuo K, Yukihiro F Hematoma in the splenium of the corpus callosum in the subacute stage of subarachnoid hemorrhage. *Neurol Med Chir (Tokyo)* 50(3):209-12 (2010)
15. Yajima Y, Hayakawa H, Mimasaka S, Nata M, Hashiyada M, Funayama M. Intracerebral haematoma: traumatic or non-traumatic. *J Clin Forensic Med.* 2001 Sep; 8(3):163-5.