

Convexity meningiomas posing difficult challenges for neurosurgeons: Two case reports and literature review

Kumar Ashish, Pandey P.N., Ghani Arshad, Jaiswal Gaurav

LN Hospital, Maulana Azad Medical College, New Delhi

Department of Neurosurgery, LN Hospital, Maulana Azad Medical College, New Delhi

Abstract

Meningiomas have been intriguing since the time of Harvey Cushing. Although, most of them have been conquered by “today’s neurosurgeons”, still they can pose difficult challenges sometimes. Convexity meningiomas are relatively easier to tackle especially if they are not too large and do not displace critical neurovascular structures. However, they can complicate matters at times and hence, extreme precautions need to be practised. We report two such cases of convexity meningiomas with unusual set of events where one had an unusual post operative complication and the other had an unusual mode of presentation. Extradural hematomas (EDH) are a common complication after intracranial surgeries. They are usually picked up in the early post-operative scans and are managed according to their size and mass effect. The first patient is a 60 year old female where delayed EDH was detected after a sudden bout of hypertension after the initial scan after 48 hours of surgery was normal. Intraoperatively, middle meningeal artery (MMA) had re-bled due to this sudden rise in the blood pressure. Second case is a 33 year old female who presented with an intracerebral bleed due to hemorrhage within a convexity meningioma.

Keywords: convexity meningioma,

extradural hematoma, intracerebral hemorrhage

Introduction

Meningiomas pose a tough challenge for neurosurgeons across the world due to their so called benign nature and expected excellent outcome after complete excision. Very thin margins of error make the convexity meningioma surgery even more interesting as usually Simpson grade 0 excisions are expected more often. But sometimes, these convexity meningiomas may have varied presentations and can cause unusual complications. We report two such patients who presented in rather unusual manner and hence deserve to be noticed so that, awareness regarding such presentations/complications makes surgeons expectant and wary of them.

Case 1

A 60 year old female presented to us with occasional severe headaches. She had no other symptoms and her neurological examination was normal. Magnetic Resonance Imaging (MRI) had revealed a convexity meningioma in the left parietal region which was isointense on T1-weighted image, hypointense on T2-weighted image and was intensely contrast enhancing (Figure 1). She was hypertensive since many years and was on anti

hypertensive medicines. Her prothrombin time and platelet counts were within normal range and she was not on any anti-thrombotic drugs. She wished to undergo surgery and underwent left parietal craniotomy and excision of meningioma after a thorough pre-operative work up. The surgery was straightforward. A thick posterior branch of the middle meningeal artery (MMA) on the surface of dura (coming in the line of the dural incision) was controlled well with bipolar cautery. The meningioma was removed (Simpson grade 0 excision) and duraplasty was done in the region of involved dura. The post operative period was uneventful and the patient was planned for discharge. The post operative Computed Tomography (CT) scan after 48 hours of surgery showed no evidence of blood in the tumour bed and was satisfactory (Figure 2). After 6 hours of this scan, she suddenly started complaining of severe headache. She was given analgesics and the blood pressure medications as the pressure shot up to 190/120 mm of Hg (millimetres of mercury). She developed altered sensorium within minutes and had respiratory distress. The pupil on the left side was blown up (4mm, not reacting to light). She underwent a second CT scan in a span of 6 hours, which showed a large extradural hematoma (EDH) at the operative site with mass effect and midline shift (Figure 3). Her repeat coagulation profile was normal. The patient was immediately taken for re-surgery and the hematoma was evacuated. The same branch of MMA was found to be ferociously bleeding. It was coagulated and ligated this time. The patient was shifted to the intensive care unit (ICU). Post operatively, she was electively ventilated for 24 hours and the blood pressure was being closely monitored. 24 hours later, she

developed another bout of hypertension (190/110 mm of Hg) and started having hematemesis. She later developed multiple organ dysfunctions and succumbed to it.

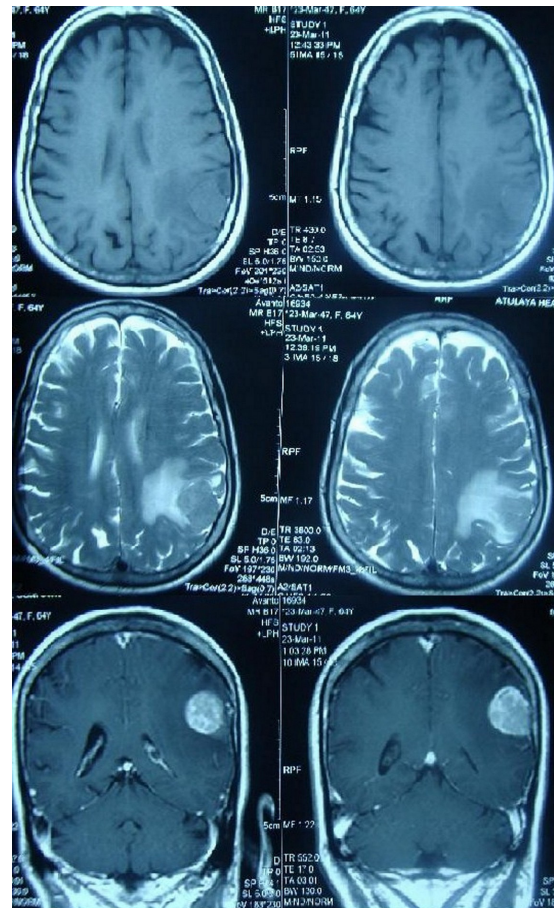


Figure 1

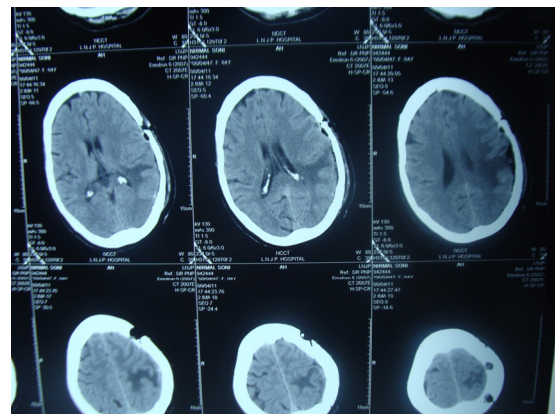


Figure 2

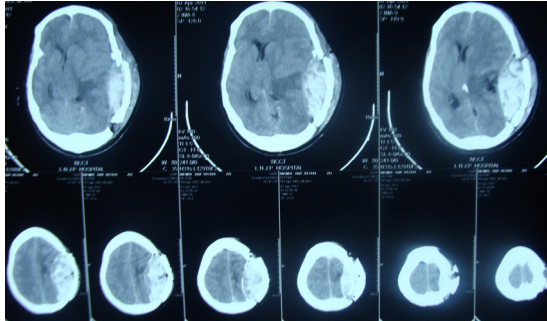


Figure 3

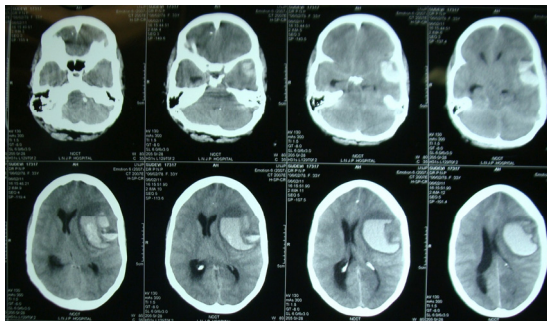


Figure 4

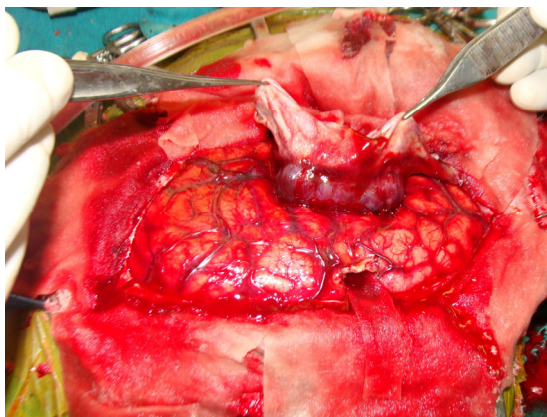


Figure 5

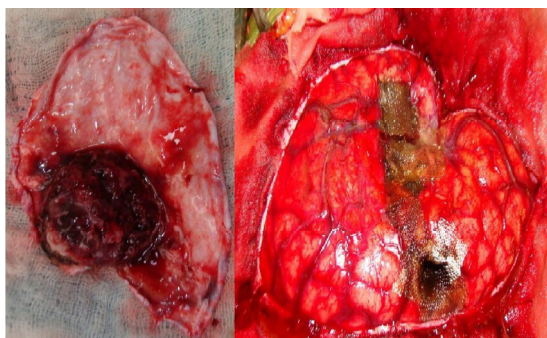


Figure 6

Case 2

A 33 year old female presented to us with sudden loss of consciousness 12 hours back. Although she had occasional headaches, nothing major was noticed by the relatives. On examination, she had bradycardia and her blood pressure was 100/60 mm of Hg (millimetres of mercury). She had a Glasgow Coma Scale (GCS) of 4/15 and the pupil on the left was dilated (3mm; non-reacting to light). She was immediately intubated and was taken up for an emergency CT scan (Figure 4) which showed large left sided intra-cerebral hematoma with mass effect and midline shift. Although, a tumour bleed was suspected, nothing could be conclusively established without a contrast scan (which was not available for the emergency scan). The patient was deteriorating rapidly and hence was taken for decompression surgery and clot evacuation. Evaluation for the etiology was planned as a second stage procedure once the patient was optimized. Intra-operatively, the brain was tense and hence the hematoma was first evacuated by middle frontal gyrus approach while a dural based hemorrhagic lesion (suspected to be a convexity meningioma) was observed too (Figure 5). It was excised (Simpson grade 0 excision) and lax duraplasty was done (Figure 6). The patient was electively ventilated post operatively. However, she succumbed after 24 hours of surgery due to other metabolic complications. The histopathology was fibroblastic meningioma.

Discussion

Convexity meningiomas in both the cases posed great difficulties for us. In the first case, delayed EDH after 56 hours of surgery with a satisfactory post operative

CT scan was unusual in our experience. The probable reason would have been a reactionary haemorrhage due to MMA clot dislodgement due to a bout of hypertension. Lee et al studied surgeries of 153 meningiomas and found statistically significant relationship of post-operative hematomas in patients older than 70 years and having platelet counts less than $150 \times 10^9/l$ (8). Gerlach et al have also echoed similar findings (2). The other possible risk factors not validated yet, are: the preoperative use of anti-thrombotic medicines, location and histology of meningioma, invasion of venous sinus, arachnoid infiltration and the extent of removal (partial versus total). Although hematomas are commonly found more often after meningioma surgery than any other intra-cranial tumour surgery (4,10), most likely it occurs in the tumour bed itself and early CT should pick it up under most circumstances. Palmer et al also found the majority of postoperative hematomas intraparenchymal (43%) and frequently occurring after meningioma surgery (6.2%) (10). Our patient had a normal coagulation profile, but we think that the delayed reactionary haemorrhage (>56 hours) occurred due to a hypertensive episode and hence, post operative monitoring of the same should have been more stringent. Although, old age patients with hypertension are prone for post-operative bleeding, such rare catastrophe has never been reported in the literature. We did not find any similar case where an EDH developed so late in the post-operative period. In the second case, presentation as intracerebral bleed was unusual. Bosnjak et al determined the clinico-pathological features of patients with intracranial bleeding from unsuspected meningioma and found out that an increased bleeding

tendency was seen in patients <30 years and >70 years, in "convexity" and intraventricular locations and "fibrous" meningiomas (1). All these features were present in our patient. They further noticed that 96.2% patients survived after their meningiomas spontaneously hemorrhaged. In patients who were unconscious before surgery (as in our case), overall mortality rate was 74.1%, and that in surgically treated cases was 46.2%. Various authors have reported similar cases in the past and most of them have reported this complication with an angioblastic meningioma (3,5,6,7,9). Various hypotheses have been proposed for such an occurrence. Most common one is the rupture of abnormal vascular network of tumour or the invasion of thin vessels by the tumour cells. The other possible explanation is the rapid growth of lesion causing intratumoral necrosis and hemorrhage.

The objective of this article is to highlight a rare presentation and complication associated with convexity meningiomas. We suggest that high risk patients should be closely observed for hemodynamic stability for a significantly longer post-operative period and also, intra-operatively, if any significant calibre MMA branches are encountered in the line of durotomy, it should be both ligated and coagulated so as to remain doubly secure and hence prevent such mishaps accounting to high mortality and morbidity. Patients with intracerebral hematomas should be first managed by hematoma evacuation. Excision of the meningioma later will lead to improved outcomes once the intracranial pressure (ICP) has been brought down. In spite of this, the prognosis remains grave which stresses on the role of screening in population for such tumours.

Corresponding Author: Dr Ashish Kumar, Room number 21, PG Men's Hostel, Maulana Azad Medical College, New Delhi-110002, Phone: 9999622962, Email: drashishmch@hotmail.com

References

1. Bosnjak R, Derham C, Popović M, Ravnik J. Spontaneous intracranial meningioma bleeding: clinicopathological features and outcome. *J Neurosurg.* 2005 ;103:473-84.
2. Gerlach R, Raabe A, Scharrer I, Meixensberger J, Seifert V: Post-operative hematoma after surgery for intracranial meningiomas: causes, avoidable risk factors and clinical outcome. *Neurol Res* 26: 61-6,2004.
3. Helle TL, Conley FK. Haemorrhage associated with meningioma: a case report and review of literature. *Journal of Neurology, Neurosurgery, and Psychiatry,* 1980;43: 725-29.
4. Kalfas IH, Little JR : Postoperative Hemorrhage : a survey of 4992 intracranial procedures. *Neurosurgery* 23: 343-347, 1988.
5. Kohli CL, Crouch RL. Meningioma with intracerebral hematoma. *Neurosurgery* 1984;15: 237-40.
6. Kurokawa H, Kikuchi K, Kamisato N, Miura S, Ishida Y. Massive intracerebral hemorrhage due to a convexity meningioma. *Rinsho Hoshasen* 1989 ;34:723-6.
7. Lazaro RP, Messer HD, Brinker RP. Intracranial hemorrhage associated with meningioma. *Neurosurgery* 1981;8:96-101.
8. Lee BY, Hong SK, Chu WH, Kang JK: Risk Factors of Postoperative Hematomas after Surgery for Intracranial Meningiomas. *J Korean Neurosurg Soc* 39:109-113,2006.
9. Nakao S, Sato S, Ban S, Inutsuka N, Yamamoto T, Ogata M: Massive intracerebral hemorrhage caused by angioblastic meningioma. *Surg Neurol* 1977;7:245-48.
10. Palmer JD, Sparrow OC, Fausto I : Postoperative hematoma : a 5-year survey and identification of avoidable risk factors. *Neurosurgery* 35:1061-64, 1994.