

Giant asymptomatic intracranial hydatid cyst in a 3 years old child – case report

A. Tascu, A.V. Ciurea, Iulia Vapor, A. Iliescu, F. Brehar

“Bagdasar-Arseni” Clinical Emergency Hospital, Bucharest, Romania

Introduction

Objective

Although hydatid cysts are known commonly to affect the liver and lung, it can also affect the brain (1-2% of cases). Brain involvement is more commonly seen in children (50-75% of intracranial hydatid cysts), and usually has

intraparenchymal localization. In this paper we present a case of a 3 years old child diagnosed incidentally with a giant intracranial hydatid cyst.

Case presentation

The patient was admitted in the hospital with a mild craniocerebral trauma, with an epicranial haematoma. The clinical and neurological examinations were normal. The CT scan of the brain revealed a giant solitary cystic lesion, located in the left frontoparietal lobe, with features suggestive of hydatid cyst. The removal of the cyst, without rupture, was performed using the Dowling technique modified by Arana-Iniguez. Postoperatively the neurological exam was normal and the patient was asymptomatic at 7 months follow-up.

Conclusion

The hydatid cyst usually enlarges slowly, but this is variable, the growth being higher in children, in whom it can reach giant dimensions without or with minimal symptoms. It is a benign lesion, and the removal of the cyst without rupture is very important.

Case presentation

A three years old child was admitted in the hospital after a mild cranio-cerebral trauma. The neurological exam was normal and the local exam revealed a frontoparietal epicranial hematoma. The skull X-rays showed a linear parietal fracture. The CT scan of the brain revealed a giant solitary cystic lesion, hypodense, non-enhancing, located in the left frontoparieto-occipital lobe, with the diameter 10 cm, and a midline shift of 1, 5 cm. The brain MRI (Figures 1, 2, 3) showed a cystic lesion hyperintense on the T2-weighted images (similar to CSF) with a hypointense halo around the cyst capsule. The features were suggestive of hydatid cyst. The clinical exam, chest X-rays and abdominal ultrasound effectuated showed no signs of other localisations. Routine laboratory tests were all normal. The serologic tests for hydatid disease were not performed.

Intraoperatively we used the Dowling method modified by Arana-Iniguez. A large craniotomy was performed (Figure 5 A). After that the dura mater was opened carefully taking care not to open the cyst because the cortex overlying the cyst was very thin (Figure 5 B) a linear corticotomy was made (this must be no less than three quarters of the diameter of the cyst) (Figure 5 C, D). Saline solution (0, 9%) was used to dissect the cyst from the surrounding brain and to facilitate the hydatid removal (Figure

5 E, F). Also is useful using the Valsalva manoeuvre and counterpressure to the surrounding brain. The hydatid cyst was removed without rupture (Figure 6). The dura was closed in a watertight fashion after filling-up the remaining cavity (Figure 5 G) with saline solution (0, 9%).

The postoperative CT scan showed no signs of bleeding. The 7 months follow-up CT scan revealed a subdural liquid accumulation which was non-compressive, so we decided not to operate the patient and follow-up periodically (Figure 5 A, B).

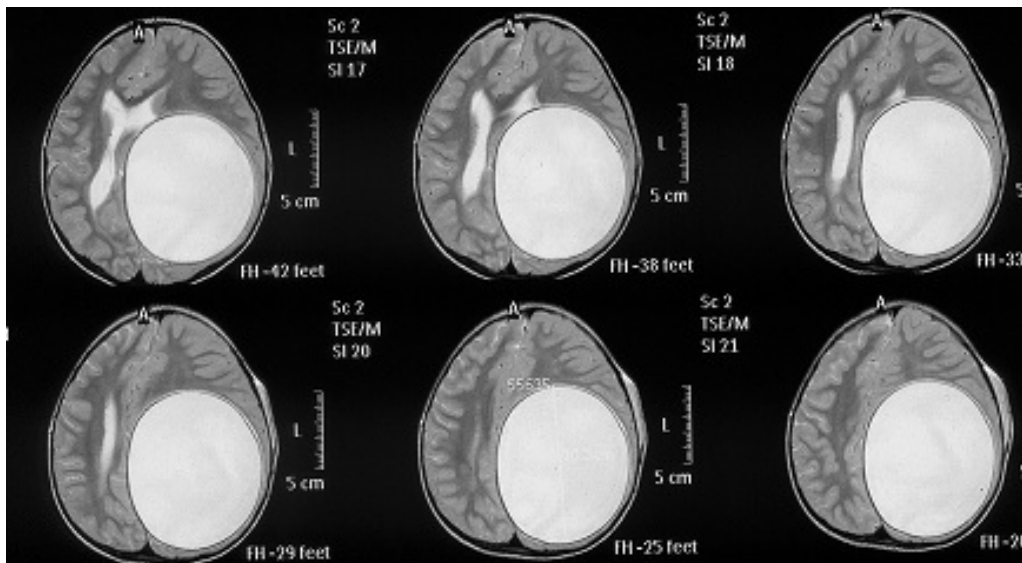


Figure 1 Preoperative MRI shows a cystic lesion hyperintense on T2-weighted images (similar to CSF) with a hypointense halo around the cyst capsule

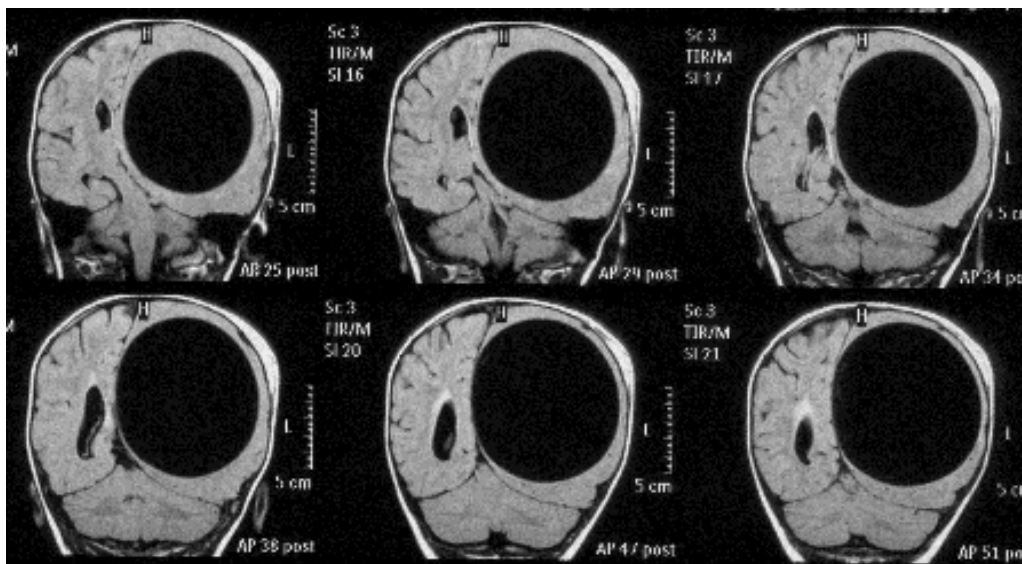


Figure 2 Preoperative MRI: T1 weighted images shows a cystic lesion. Midline shift is 1,5 cm. Also can be seen the epicranial haematoma

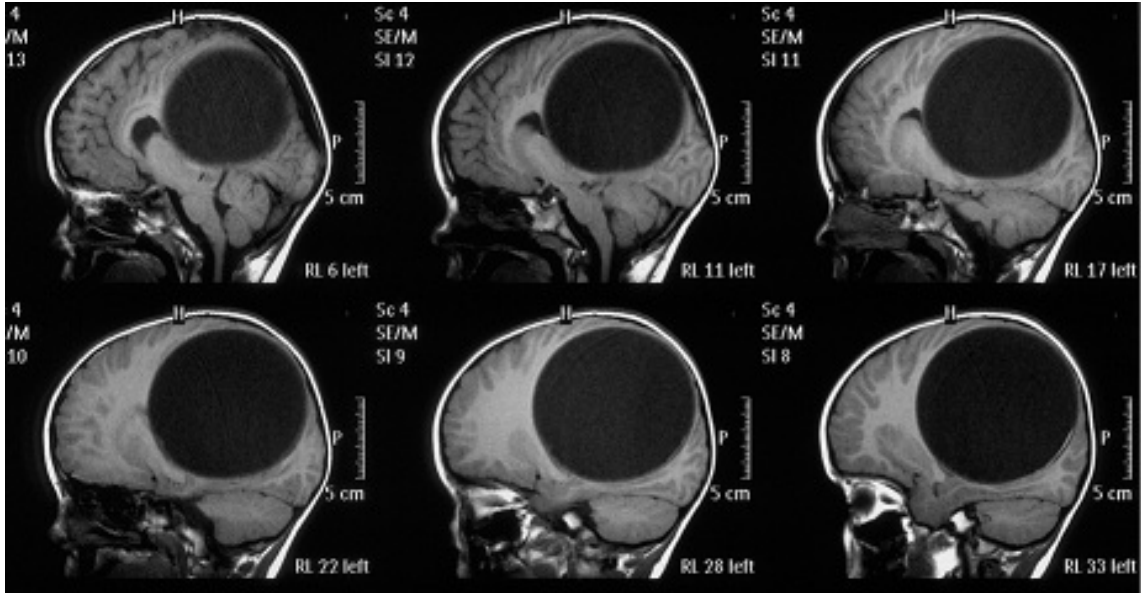


Figure 3 Preoperative MRI- T2 weighted images, sagittal sections shows the compression of corpus callosum

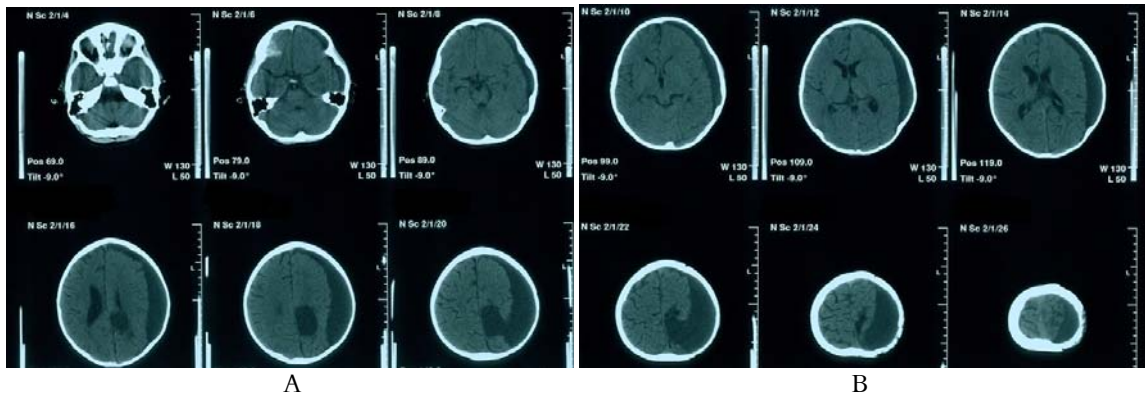
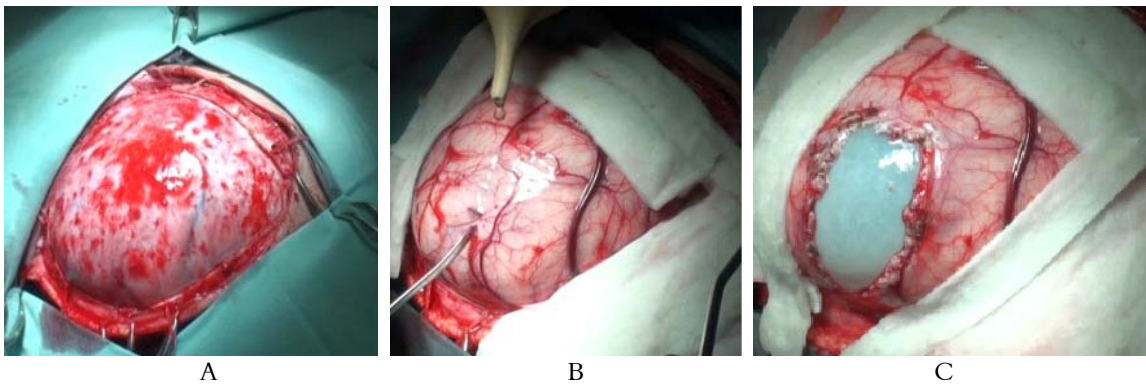


Figure 4 (A, B) Postoperative CT scan (7 months follow-up) shows a subdural collection, non-compressive



A

B

C

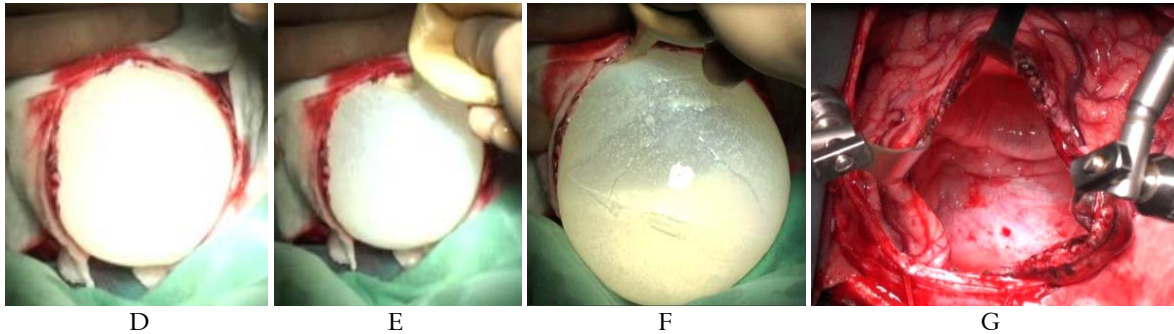


Figure 5 Intraoperative images. A- Large craniotomy ; B- After opening dura mater you can notice that cortex overlying the cyst is very thin; C- Corticotomy must be at least $\frac{3}{4}$ of the diameter of the cyst; D - Counterpressure applied to surrounding brain is useful; E, F- Dissection of the hydatid cyst from surrounding brain is made using saline solution; G- Big cavity which remains after the removal of the cyst sometimes can lead to subdural collections and porencephalic cysts.

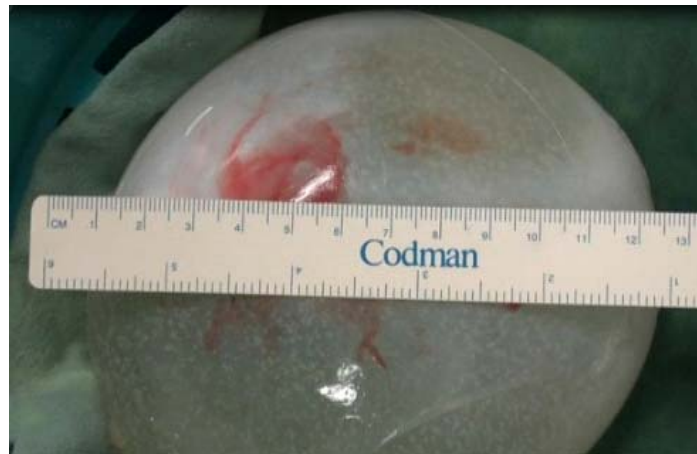

Figure 6 Hydatid cyst after removal without rupture

Discussion

Hydatid cyst is an anthrozoosis caused by *Ecchinococcus Granulosus*. Infection with the larval stage of the tapeworm causes hydatid cysts in humans. Hydatid disease is endemic in the sheep and cattle-raising areas of the world (Mediterranean countries, South America, Middle East and Australia). In Romania, the disease is endemic in Dobrogea, in the mountain areas, and in the towns located along the Danube River.

Although hydatid cysts are known commonly to affect the liver and lung, it can also affect the brain (only 1-2% of cases). Brain involvement is more

commonly seen in children (50-75% of intracranial hydatid cysts), and usually has intraparenchymal localization. Primary cysts are usually solitary, secondary cysts are usually multiple (from embolization of cardiac cysts that rupture or from iatrogenic rupture of cerebral cyst). Ninety percent of the cases have solitary lesion, most frequently supratentorial, intraparenchymal, and in the middle cerebral artery territory. The cyst usually enlarges slowly, rates of approximately 1 cm per year are quoted, but this is variable, the growth being higher in children where it can reach a growth rate of 4, 5 cm every 6 months.

There are debates about the presence of

solitary brain hydatid cyst. Some authors sustain the hypothesis that usually the cysts are multiple but due to the fact that the growth rate of intracranial hydatid cyst is higher than in other organs, at the moment of diagnose the others are too small to be detected clinically or radiological. Sometimes hydatid cyst with other localisation can be diagnosed 20-30 years after the diagnosis and treatment of brain hydatid cyst. Also, usually, the postoperative treatment includes the administration of drugs which can also inhibit the growth of other possible cysts. Also the immune system can inhibit the growth of hydatid cyst in other organs, except the central nervous system due to the limited access to the immune system.

The diagnostic tools include CT and MRI (both may provide signs of a hydatid cyst specific enough to achieve a diagnosis) and serologic tests for hydatid disease, such as enzyme-linked immunosorbent assay or indirect hemagglutination. The CT images reveal a cystic lesion, round, without any surrounding edema and without enhancement. On T2-weighted MR images, the hydatid cyst appears as a cystic lesion with a hypointense halo around the cyst capsule.

The main treatment is complete removal of the cyst without rupture. Adjuvant therapy with mebendazole is recommended in cases with systemic disease, recurrence or when rupture of the cyst occurs during surgery. This can be done by using the Dowling technique modified by Arana-Iniguez. This consists of dissection of the cyst from the surrounding brain using a saline solution (0, 9%), also using the Valsalva manoeuvre and counterpressure to the surrounding brain. It is very important not to rupture the cyst. The main two complications of the rupture of the cyst are the anaphylactic reaction, and the contamination of the adjacent tissues with possible recurrence of multiple hydatid cysts. In the literature are reported

recurrence rates of 19% and a mortality of 10,12%, morbidity 9, 8% and perioperative mortality of 8,48 %. When large cysts are removed, in the pediatric population, have been reported subdural collections and porencephalic cysts. In some cases if those lesions have mass effect it might be necessary the placement of a shunt.

Conclusions

Hydatid cyst usually is a slow growing lesion, but this is variable, the growth being higher in children in whom it can reach giant dimensions without or with minimal symptoms. It is a benign lesion and the removal of the cyst without rupture is the most important surgical goal.

References

- 1.A Leland Albright, Ian F Pollack, P David Adelson. Principles and Practice of Pediatric Neurosurgery: 1191-1192, 2009
- 2.Farid Radmenesh, Farideh Nejat. Primary Cerebral hydatid cyst: two cases report. Iran J Pediatrics, 18: 83-86, 2008
- 3.J Lunardi P, Missori P, Di Lorenzo N, Fortuna A. Cerebral hydatidosis in childhood: a retrospective survey with emphasis on long-term follow-up. Neurosurgery, 29 (4): 515-7, 1991 Oct
- 4.Mark S Greenberg. Handbook of Neurosurgery, 2006: 238-239
- 5.Mehmet Turgut, Kemal Benli, Muzaffer Eryilmaz. Secondary multiple intracranial hydatid cysts caused by intracerebral embolism of cardiac echinococcosis: an exceptional case of hydatidosis. Case report. J Neurosurg, 86: 714-718, 1997
- 6.Nur Altinors, Murad Bavbek, Hakan H Caner, Bulnet Erdogan. Central nervous system hydatidosis in Turkey: a cooperative study and literature analysis of 458 cases. J Neurosurgery, vol 93: 1-8, 2000 July
- 7.Said Hilmani, Abderrazak Bertal, Abdelhakim Lakhdar, Ali Ouboukhlik, Abdenabi Elkamar, Abdessamad Elazhari. Craniocerebral hydatid cyst. Case illustration. J Neurosurg (1 Suppl Pediatrics), 105: 77, 2006
- 8.Salaou Ouman, Ibrahiouin Kadija, Cheleaoiu Abdemajid, Hilmani Said, et al. Intracerebral hydatid cyst: about 1104 cases. African Journal of Neurological Sciences, vol 26: 22-26, 2007
- 9.Tazun Y, Kadioglu HH, Izci Y, et al. The clinical, radiological and surgical aspects of cerebral hydatid. Pediatr Neurosurg, 40 (4): 55-60, 2004
- 10.Yusuf Izci, Yusuf Tüzün, Halil Ibrahim Seçer, Engin Gönül. Cerebral hydatid cysts: technique and pitfalls of surgical management. J Neurosurg, 24: 1-5, 2008