

The role of the intraoperative ultrasonography in low-grade gliomas. Case report

V. Pasca¹, Șt.I. Florian^{1,2}, Andreea Magyoros¹

¹Cluj County Emergency Hospital, Neurosurgical Department

²University of Medicine and Pharmacy "Iuliu Hatieganu" Cluj-Napoca

Abstract

Objective: Use of intraoperative ultrasound for localizing tumors and determining the extent of resection.

Materials and methods: We report two patients diagnosed with brain tumors that underwent intraoperative ultrasonography in localizing and defining the borders of tumors and assessing the extent of their resection.

Discussions: Intraoperative ultrasound brain scanning is extremely useful to detect the cerebral lesion, the relationships with the nearby structures, the estimation of vascularization, the grade of resection and other associated lesions. The tumor image is different from the normal anatomical CNS structures, and some features like soft or hard tissue, cystic or necrotic areas can be visualized.

Conclusion: Cerebral intraoperative ultrasound is a benefit for the surgical act, thus being the neurosurgeon's "deep-seated eye".

Keywords: low - grade glioma, ultrasonography mode B, doppler

Background

Medical practice requires a correlation of clinical aspects, imaging and treatment methods in order to have a successful

outcome. In the neurosurgical field, approaching the intracranial lesion is more challenging than in other surgical specialties because the cranial vault can not be "squeezed" as the neurosurgeon would like to do it. In corticalized brain tumors the approach is easy. The maximum usage of ultrasound takes place during gliomas and metastases operations because of their subcortical deep-seated localization, where the need to pinpoint the tumor site is important so that a major brain damage to be avoided. CT scan and MR imaging are utilized to diagnose brain lesions. Intraoperatively, the MRI and ultrasound scanning are the tools used to localize the lesions. Intraop. MRI is of a higher sensitivity and can be correlated with the preop. MR images but, it's still expensive, needing a special equipment and a quite long examination time. The real-time B-mode and Doppler sonography is easy, fast, reproducible, inexpensive and relatively simple equipment (1,5). One of the limitations of the intraoperative ultrasonography is that it is difficult to correlate with the preoperative examinations (CT, MRI), because the slices are different and the quality of the image somehow is poorer. However, some lesions are highly visible in ultrasound without requiring contrast enhancement.

This study, supported by two clinical case presentations, highlights both the usefulness of the intraoperative ultrasound for lesion site and the quality of the echographic images.

Material and methods

Case one

(Figure 1 A, B, C, D)

Patient BC, a 36 years old male, admitted with headaches, vomiting, right omonime hemianopsia. The native and contrast enhanced cerebral CT scan revealed a hypodense lesion in the left occipital lobe with slight post contrast enhancement. T1 weighted MRI images showed a decreased signal intensity lesion with distortion of the nearby structures and low contrast enhancement. On T2-weighted images the lesion is of low signal intensity and with ill-defined tumor margins. Intraoperative ultrasound was performed for tumor location and its relationships with the surrounding anatomical structures. The sonographic image was of a homogenous, hyperechogenic lesion, poor delineated with the aspect of an amphora with the neck oriented upwards. The cortical sulcus for the optimal approach to the tumor was also visualized and the Doppler mode unveiled a low-grade tumor vascularization. Macroscopically, a grey, friable, poorly defined, poorly vascularized and infiltrative tumor was removed. After ablation, the ultrasound was used to assess the extent of resection at the end of surgery. There was a clear boundary between the tumor and the cerebral edema and no signs of hemorrhage or ischemic lesions after surgery.

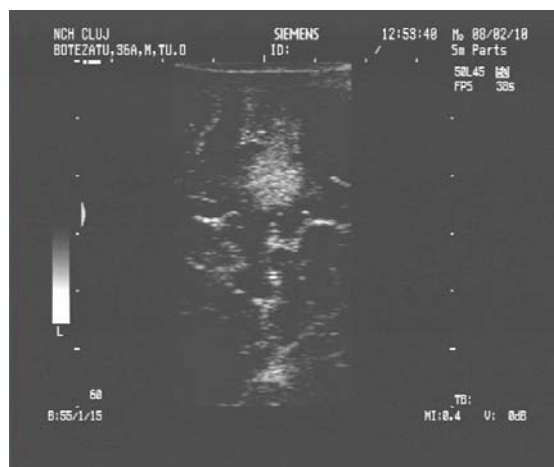


Figure 1 A Preoperative B mode ultrasonography

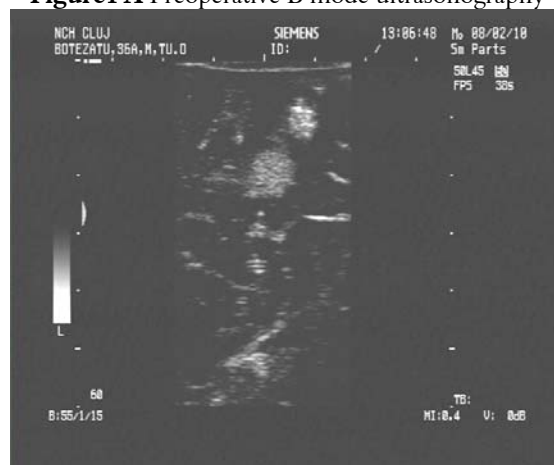

Figure 1 B B mode ultrasonography: for the tumor and reper

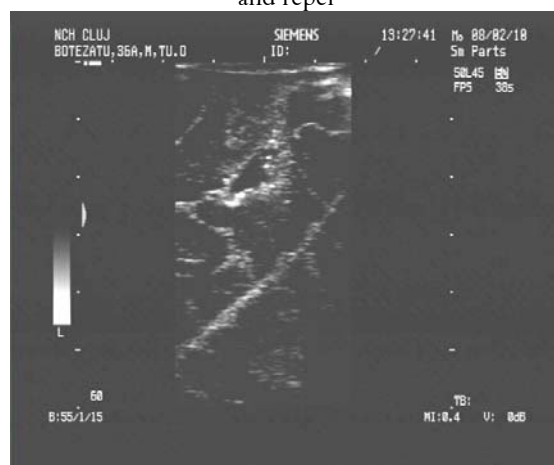


Figure 1 C Postoperative ultrasonography

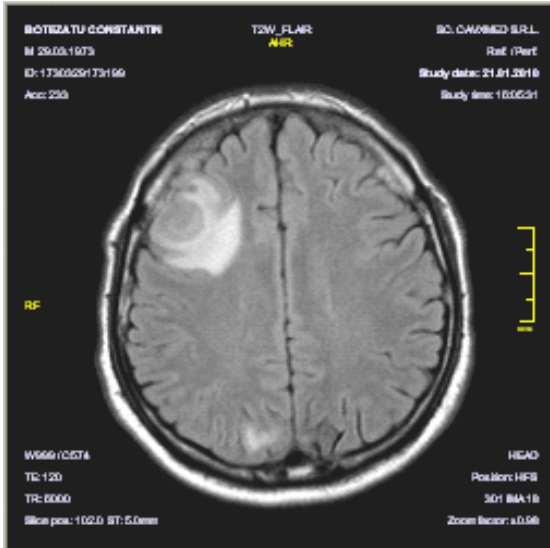


Figure 1 D MRI cerebral

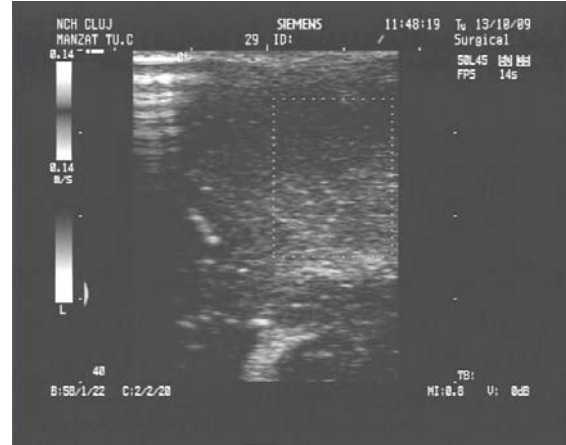


Figure 2 C Doppler ultrasonography

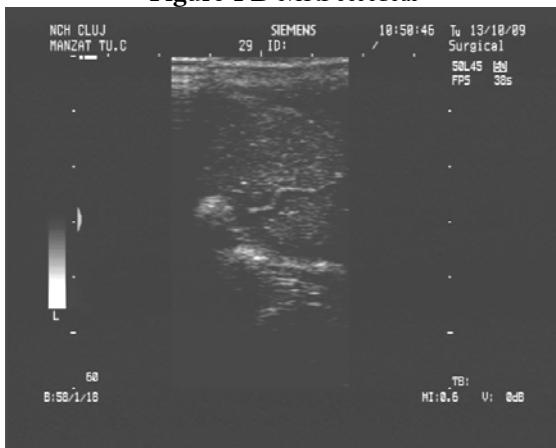


Figure 2 A Preoperative ultrasonography

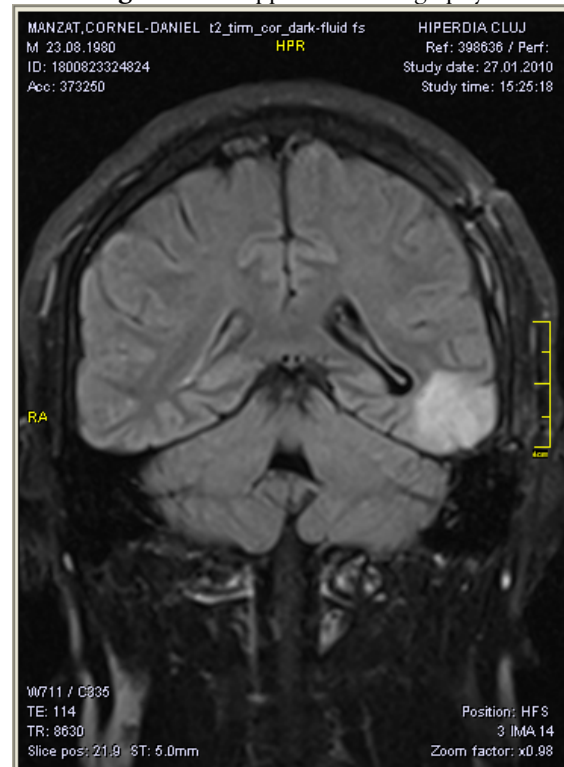


Figure 2 D MRI cerebral

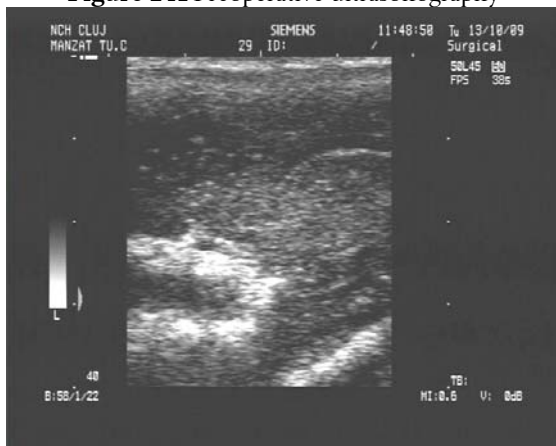

Figure 2 B Postoperative ultrasonography highlighting zone resection and the tumoral rest

Case two

(Figure 2 A, B, C, D)

Female patient, MA, 29 years old admitted in our department with partial seizures, dromomania, moderate intracranial hypertension syndrome, without papillary stasis at the

ophthalmoscope examination. On the CT scan a hypointense lesion in the left temporal lobe with poor enhancement after contrast administration and displacement of the neighboring structures was detected. The MRI T1-weighted images showed the left temporal lobe lesion, hypointense, poorly defined margins, with little contrast enhancement and with the corresponding mass effect. In T2-weighted imaging, the lesion has a moderate signal intensity and cerebral edema around the tumor mass. During surgery, the echographic imaging helped in localizing and defining the margins of the tumor. The tumor echo-image was hyperdense, homogenous with no well defined borders, poorly vascularized and with a moderate mass effect. After evaluating the cortical sulci above the tumor and the depth of the tumor, an ash-grey colored, friable, low-grade vascularized and poorly defined mass lesion was removed. Postoperatively, the resection control was done with the real-time B mode ultrasound.

Discussions

Astrocytomas are intraaxial, infiltrating brain tumors with a poor blood supply. According to the WHO grading system there are three types: WHO grade I corresponds to pilocytic astrocytoma, WHO grade II corresponds to low-grade (diffuse) astrocytoma, WHO grade III corresponds to anaplastic astrocytoma.

Grade II astrocytoma appears as a poorly defined, homogeneous, infiltrating, low blood supply, usually unilocular lesion. Astrocytomas of the CNS arise in the subcortical areas and the regional effects include compression, invasion, and destruction of the brain parenchyma, leading to cortical surface flattening and

altered cortical vascularization. Sonographically, the lesion is hyperechoic, homogenous with ill-defined margins and perilesional edema which is seen as less echo-intense than the tumor. The mass effect on the surrounding CNS structures is evident and the cortical sulci are left in place, the tumor extending along the arcuate fibers (7, 8 and 9). On the Doppler mode the tumor vascularization is poor and the blood supply to the surrounding brain is affected according to the tumor localization. There are no intratumoral cysts or necroses which are seen as hypo or anechogenic areas.

As Keles et al. stated,(6) the main advantage is that the intraoperative ultrasound is a real time examination performed on certain anatomical features of each operative field. As it requires a certain pressure on the cortex during ultrasound examination, the brain structures and the image of the lesion are slightly modified from that of CT or MRI investigations but, with all those the relationship between them remains the same. Brain CT and MRI studies are useful to pinpoint brain injuries and their effect on nearby structures, giving an overview of the intracranial content and details of lesion. The drawback is that they are not “live” examinations.

Intraoperative cerebral ultrasonography uses ultrasonic waves to highlight the injury. Images are formed by analyzing the reflected waves from interfaces situated at different distances from the transducer (5). Using distinct physical principles the echo images are different according to one of the three modes used in ultrasonography. Intraoperative cerebral echography is a complementary examination for detecting the mass lesion in order to obtain the most easy and safe surgical approach (2,4). After

tumor excision, the cerebral sonography is useful in assessing the extent of the resection, the anatomical relationship and the existence of some of the surgery produced injuries like hemorrhage, cerebral ischemia. Ultrasound B-mode Doppler sonography enables the estimation of tumoral and perilesional vascularization and the pulsed Doppler specifies if the vessels are of arterial or venous type. Signs like cortical blood supply, flattening of the cortical sulci, changing in the consistency of brain parenchyma at light palpation are indirect marks of a tumoral mass, and they are only clues in the whole surgical planning. B-mode real-time linear sonographic scanning can be used to identify and localize the margins of the lesion, the degree of the vascularization, the relationship to the surrounding neurovascular structures and cortical grooves, the type of the mass (cystic, parenchymatous or mixt), size and the depth of the lesion(3).

Conclusion

Real-time B-mode intraoperative ultrasound is a complementary, convenient and user-friendly method for identifying, localizing, characterizing the pathological aspects, assessing the extent of tumor resection, pointing the relationships with surface and deep cerebral structures and, recognizing surgical complications at the time of tumor removal (hemorrhage,

ischaemia, edema). The intraoperative ultrasound scanning is a useful medical tool, which doesn't exclude the CT and MRI examinations, and needs a good understanding of ultrasonography and anatomy. It is considered as the neurosurgeon's "deep-seated" eye.

References

- 1.Dudea S.M., Badea R. „Manual de ultrasonografie vasculara Doppler” Editura medicala Universitara „Iuliu Hatieganu” Cluj-Napoca 2001.
- 2.Keles G.E., Lamborn K. R, Berger M.S., „Coregistration accuracy and detection of brain shift using intraoperative sononavigation during resection of hemispheric tumors” *Neurosurgery* 53:556-564, 2003.
- 3.Litofsy N.S., Bauer A.M., Kasper R.S., „Image-guided resection of high-grade glioma: patient selection factors and outcome” *Neurosurgical Focus*, 2006.
- 4.Lopez-Hernanades F., Hernandez-Palazon J., Reus-Pintado M, „Craniotomia guada por ultrasonografia bidimensional para exeresis de tumor cerebral supratentorial” *Neurocirugia* 2008, 19: 530-536.
- 5.Mircea P.A., Dudea.S.M., Badea R. „Ecografie generala” Tipografia UMF. „Iuliu Hatieganu” Cluj-Napoca 2000
- 6.Nikas D.C, Hartov A., Lunn K., Rick K., Paulsen K., Roberts D.W., „Coregistered intraoperative ultrasonography in resection of malignant glioma” *Neurosurgery Focus* 14(2): Article 6, 2003.
- 7.Solhelm O., Selbekk T. et col. „Intraselar ultrasound in transsfenoidal surgery: a novel technique” *Neurosurgery* 2010 66(1), 173-186.
- 8.Tirakotai W, Miller D, Heinze S, Benes L, Bertalanffy H, Sure U. „ A novel platform for image – guided ultrasound”, *Neurosurgery* 58: 710-718, 2006.
- 9.Unsgaarg G. „ Brain operation guided by real- time two dimensional ultrasound: new possibilities as a result of improved image quality” *Neurosurgery online*, vol.51, N.2, aug.2002, 402-412.