

## Medulloblastoma – an overview

**A.V. Ciurea, Claudiu Palade**

1<sup>st</sup> Neurosurgery Clinic, “Bagdasar-Arseni” Emergency Hospital

### Abstract

The authors intend to present in this paper the most actual trends and perspectives in the challenging field of medulloblastoma multimodal treatment.

The data collected from the medical literature and augmented with personal experience, outline a scientific and pragmatic conduct of medical thinking and action.

The epidemiology, clinical presentation, neuroimaging modalities, pathology and therapy (surgical, XRT and chemotherapy) regarding this medical issue are thoroughly glanced and outlined.

### Epidemiology

Medulloblastoma is a malignant and invasive embryonal tumor of the cerebellum, corresponding histologically to World Health Organization (WHO) grade IV, that has sometimes been referred to as an infratentorial primitive neuroectodermal tumor, or PNET. [21]

Although medulloblastoma is the most common histologic type of malignant central nervous system (CNS) tumor in childhood (0 to 19 years), accounting for 17.2% of these tumors, they account for only 0.7% of all malignant CNS tumors in adults (age  $\geq 20$ ). The incidence of this tumor steadily decreases with increasing age after a peak occurrence at age 6. It is estimated that only 29% of medulloblastomas occur in patients age 20

or older. This tumor rarely occurs after the age of 50. Sixtytwo percent of patients are male (61% age  $< 20$  and 63% age  $\geq 20$ ).

### Important clinical features

The clinical presentation of posterior fossa tumors is similar in adults and children, and many signs and symptoms are related to hydrocephalus caused by obstruction of cerebrospinal fluid (CSF) flow by the tumor.

Early in the course of disease, complaints of nonspecific headache, fatigue, slight imbalance, and personality changes may occur. As the disease progresses, signs and symptoms of increased intracranial pressure predominate, especially headache. These headaches are usually present on awakening in the morning and improve or resolve after rising and as the day progresses. Headaches may become persistent if the tumor is not diagnosed and treated. Nausea and vomiting are also common. Sixth cranial nerve palsies and diplopia, caused by increased intracranial pressure, are not uncommon.

Focal neurologic deficits caused by pressure on or infiltration of the brainstem, cranial nerves, or cerebellar structures also occur.

Dizziness or other cerebellar dysfunction occurs in most patients, and the pattern of deficits is related to the location of tumor in the posterior fossa. Lesions occurring in the midline are likely

to cause truncal and gait ataxia, whereas limb ataxia is more common in lesions involving the lateral cerebellar hemispheres.

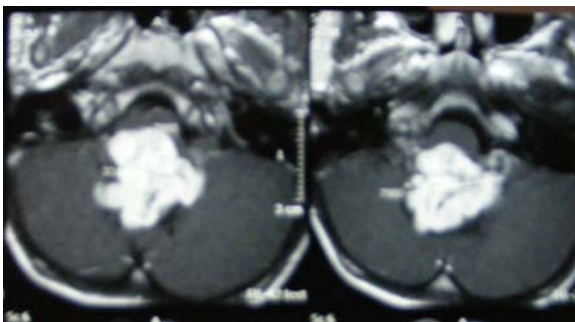
Other focal neurologic deficits such as hemiparesis, hearing loss, and seventh cranial nerve palsies occur less often. Seizures are rarely seen in children or adults with PF tumors unless extension into the supratentorial cortex occurs.

Alterations of consciousness may occur late in the course of the disease. Hemorrhage into the PF mass may cause acute loss of consciousness and coma.

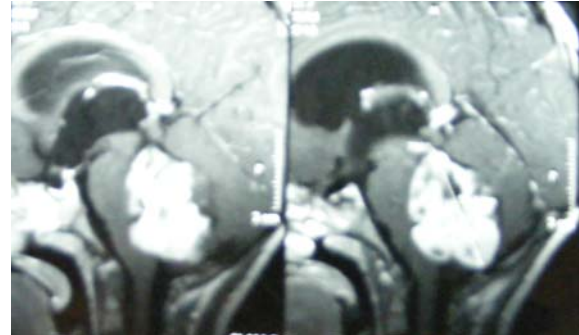
### Neuroimaging

Because of its exquisite contrast resolution, MRI is the imaging modality of choice in the preoperative work-up for infratentorial tumors and for the evaluation of leptomeningeal metastasis. Once medulloblastoma is suspected on imaging or confirmed cytologically or pathologically, MRI of the brain and entire spine before and after administration of gadolinium contrast becomes necessary.

The goal of this imaging is to determine whether there are demonstrable metastases in the craniospinal axis because of the significant impact these metastases have on management and prognosis.[2,28,38]



**Figure 1** Preoperative MRI aspect –axial incidence (personal case)



**Figure 2** Preoperative MRI aspect – sagittal incidence (personal case)

It is estimated that approximately one half of adult patients with medulloblastoma have their tumors originate peripherally in the cerebellum (paramedian and lateral locations). On rare occasions, a medulloblastoma presents as an exclusively extra-axial mass in the cerebellopontine angle and may be mistaken for a meningioma or vestibular schwannoma on computed tomography (CT) and MRI scans.[2,38]

Adult medulloblastoma is typically heterogeneous on CT and can appear hypodense or hyperdense to gray matter and have variable patterns of enhancement.[2,6] The more common peripheral tumors are poorly enhanced with contrast, whereas the less common vermian central tumors tend to be intensely enhanced with contrast. On MRI, tumors show hypointense signal on T1 - and hyperintense signal on T2 - weighted images. Contrast-enhanced T1 sequences best demonstrate the heterogeneity of these tumors. Small cysts are commonly encountered in the peripheral tumors, whereas a predominantly cystic medulloblastoma is rare.[6,34,38]

Melanotic medulloblastoma is a rare form of medulloblastoma that can potentially demonstrate high T1 signal on

the unenhanced T1 sequences.[22,60] This high signal can suggest or be confused with hemorrhage.

A rare entity in the adult literature, “lipidized” or “lipomatous” medulloblastoma has been provisionally reclassified by WHO as cerebellar liponeurocytoma (9506/1) and can also demonstrate high signal on unenhanced T1 sequences. MRI of the brain and spine is useful in assessing response to treatment, stability, tumor progression, and metastatic disease. MRI of the entire spine with and without gadolinium contrast enhancement has become the study of choice for evaluating drop metastases.

### Pathological aspects

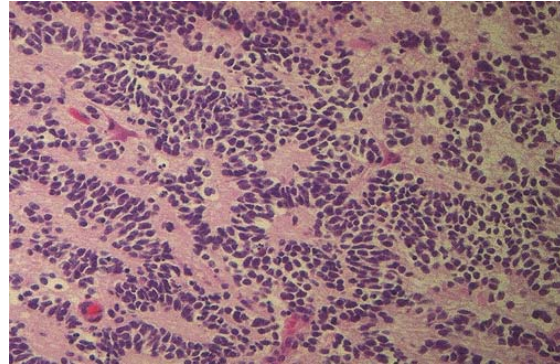
The gross appearance and histology of medulloblastoma occurring in adults overlap substantially with the features of pediatric medulloblastoma. The histology includes the five principal patterns:

- 1) undifferentiated or classic medulloblastoma,
- 2) desmoplastic nodular medulloblastoma,
- 3) medulloblastoma with neuroblastic or neuronal differentiation,
- 4) large cell or anaplastic medulloblastoma,
- 5) medulloblastoma with glial differentiation.[7,21]

The other variant forms such as:

- 6) medullomyoblastoma and
- 7) melanotic medulloblastoma are rare in the adult population, [44,57] and they are the forms containing more heterogeneous differentiation.

Undifferentiated or “classic” medulloblastoma, consisting of patternless masses of monotonous small cells, comprises the majority of medulloblastomas in both adult and pediatric groups.



**Figure 3** Microscopic aspect of a medulloblastoma specimen (HE stain)

Evidence of neuronal differentiation by hematoxylin and eosin (H&E) staining in some cases includes the formation of neuroblastic rosettes and, occasionally, the presence of ganglion cells. Despite the common lack of evidence of differentiation by routine H&E staining, evidence of neuronal differentiation may be demonstrable by immunohistochemical staining for synaptophysin or other neuronal markers or by the electron microscopic demonstration of neurites, synaptic structures, or neurosecretory granules.

The findings of necrosis, apoptosis, calcification, infiltrative behavior, intratumoral hemorrhage, and tumor extension into the overlying leptomeninges occur in both pediatric and adult cases.

The nodular or desmoplastic variety, defined by the presence of prominent nodules or “pale islands” of tumor of lower cellularity in a background of collagen-rich, highly proliferative tumor, occurs more often in the older population.[1,23,33,45,56]

A rare variant medulloblastoma with extensive nodularity and neuronal differentiation associated with a more favorable prognosis is more common in the pediatric population.[17,24]

Medulloblastoma with neuroblastic or neuronal differentiation characterized by extensive nodularity and differentiation toward neurocytes or ganglion cells and referred to by some authors as “cerebellar neuroblastoma,” is an uncommon variant and occurs primarily in infants and very young children.

Large cell or anaplastic medulloblastoma, characterized by populations of larger, more pleomorphic tumor cells than those in classic medulloblastoma, is also an uncommon variant occurring predominantly in the pediatric population and is often associated with an unfavorable outcome. [16,25]

Glial rather than neuronal differentiation in medulloblastoma has been reported in up to one third of cases of medulloblastoma occurring in older individuals. Mature glial cells, identified by the presence of eosinophilic cytoplasm and cell processes, may be difficult to identify in H&E-stained sections. By immunohistochemical staining for glial fibrillary acidic protein (GFAP), immunoreactive fibrillated cells can be identified in most pediatric [11] and adult medulloblastomas, typically in a perivascular location or at the periphery of the tumor. Although such cells have commonly been considered entrapped reactive astrocytes rather than tumor cells, similar cells have been observed in metastatic medulloblastoma in nonbrain sites, suggesting that they are actually tumor cells.

Glial differentiation in tumor cells, usually defined by the finding of glial fibrillary acidic protein-immunoreactivity in the perikaryon or short cell processes of cells with distinctively neoplastic nuclear features, has been described in a small percentage of medulloblastomas,

particularly in the adult population. GFAP-immunoreactive cells have also been noted within the nodules and in the internodular tumor cell population of desmoplastic nodular medulloblastomas. Studies investigating the prognostic significance of glial differentiation have yielded contradictory results. [11,29,35]

In the pediatric population, suggestions of correlations between genetic markers and prognosis such as cytogenetic studies of chromosome 17 and others, p53 overexpression, studies of ErbB2 receptors, high TRKC receptor expression, amplification of MYC, and abnormalities in the sonic hedgehog (SHH)–PTCH pathway have been noted, with the best correlations occurring in the large cell–anaplastic variant. [17,42,65]

In adult medulloblastoma, a recent study correlated overexpression of MDM2 with shorter survival. [27,28]

More recently, cDNA-based gene-expression profiling has demonstrated that medulloblastomas are distinct from primitive neuroectodermal tumors and that the “classic” and desmoplastic subtypes are distinct. [54] These studies confirmed earlier observations about high TRKC receptor expression and amplification of MYC. These studies have also strongly supported the hypothesis that medulloblastomas are derived from cerebellar granular cells through the activation of the SHH pathway and suggested various novel prognostic markers related to SHH pathway activation. However, more extensive investigation will need to be carried out to verify the utility of the various genetic and molecular markers in assessing prognosis, especially in the forms of medulloblastoma more commonly encountered in the adult population such as

desmoplastic nodular medulloblastoma. Furthermore, a parallel between pediatric and adult tumors cannot be assumed.

### **Tumor staging**

The Chang staging system, which was published in 1969, evaluates tumor size, local extension, and the presence or absence of metastases.[10] The tumor (T) staging portion of the staging system may no longer have the same prognostic value that it once had. Several pediatric studies have shown that the amount of residual disease, age, and M stage are more predictive of outcome than T stage.[39,66]

It was initially based on the surgeon's intraoperative observations; however, in the modern era of neuroimaging, preoperative and postoperative scans provide similar if not better information.

### **Chang Staging System for Metastasis (M staging portion)**

#### *Stage Definition*

M0 - No evidence of gross subarachnoid or hematogenous metastasis

M1 - Microscopic tumor cells found in cerebrospinal fluid

M2 - Gross nodular seedings demonstrated in the cerebellar, cerebral subarachnoid space, or in the third or lateral ventricles

M3 - Gross nodular seeding in spinal subarachnoid space

M4 - Extraneuroaxial metastasis

The Chang metastasis (M) stage (M0 denotes local disease only, M1 denotes positive CSF cytology, M2 denotes tumor present beyond the primary site but within the brain, M3 denotes gross nodular seeding in the spinal subarachnoid space,

and M4 denotes extracranial spread) has consistently been related to outcome in pediatric studies, although this is less clear in adult series.

Evaluation for the purpose of staging includes preoperative MRI scans of the cranial vault and entire spine. CSF sampling should be performed before surgery or 10 to 14 days postoperatively to avoid a false positive related to surgery. Postoperative MRI scans of the brain should be obtained within 24 to 48 hours after resection to minimize postoperative imaging changes and accurately evaluate the extent of resection. If a preoperative MRI scan of the spine was not performed, it should be performed 2 weeks after surgical resection to allow for resolution of postoperative blood and protein artifacts that may be misinterpreted as metastatic tumor.

Over the past 10 to 15 years, sequential studies carried out by the Children's Cancer Group (CCG) and the Pediatric Oncology Group (POG)[18,19,49,51] have revealed two risk categories defined by age, extent of surgical resection, and M stage.

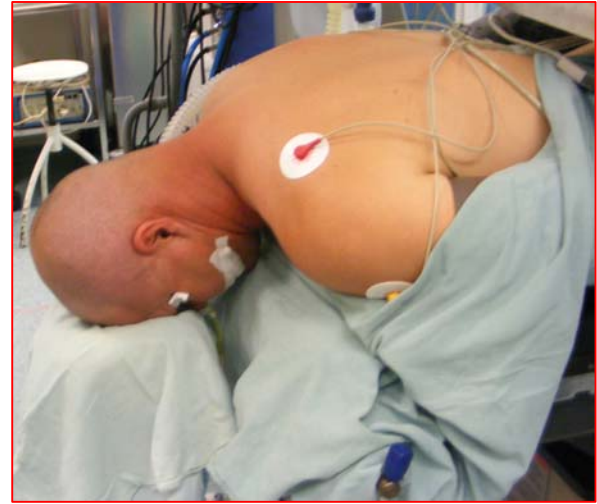Patients are considered to be average or standard risk if they are older than 3 years, have no more than 1.5 cm<sup>2</sup> of residual tumor after surgical resection, and have no CSF or spinal involvement (M0).(66) All other pediatric medulloblastoma patients are considered to be poor or high risk. Although recent data suggest that a histologic variant showing moderate to severe anaplasia may have an adverse prognosis in pediatric tumors,16 this and other possible genetic and histopathologic prognostic variables have not yet been used in prospective risk categorization, and need to be verified in other studies.[17,27,28,42,65]

### Surgical treatment

Surgery plays an integral and important role in the management of adults with medulloblastoma. The goals of surgical therapy are threefold: histologic diagnosis, maximal safe tumor resection, and restoration of patency of CSF pathways. Because medulloblastomas commonly present with some degree of hydrocephalus, the first surgical decision often pertains to management of this condition. Tumor resection alleviates hydrocephalus in up to 90% of patients in most modern series,[63] and avoids shunt-related complications such as upward herniation of the brainstem, intratumoral hemorrhage, and CSF dissemination.

Thus prompt, definitive surgical resection with use of steroids to control edema is preferred to a staged approach of shunting followed by resection. If steroids fail or urgent ventricular drainage is required, a nondominant ventriculostomy is preferred over a shunt, because it allows more precise control of intracranial pressure and drainage. Care should be taken to measure opening pressure and drain slowly at 20 cm of CSF or higher, and resection should be accomplished promptly.

Numerous studies have demonstrated the relationship between extent of resection and prognosis [41]; thus optimization of the surgical procedure is critical. This is achieved in part by meticulous preoperative preparation and by using stereotactic computer-aided navigation (CAN) tools, intraoperative ultrasound, and in some cases, brainstem evoked-potential monitoring.



**Figure 4** Patient Positioning (Prone position) – routinely used by the senior author

Surgery is more often performed with patients prone to avoid the risk of air embolism and subdural hematoma associated with sitting. The patient is managed preoperatively with antibiotics, corticosteroids, mannitol, and moderate hyperventilation.

A ventriculostomy is usually performed at the time of surgery if it has not already been performed and is managed as noted previously.

After a generous craniotomy or craniectomy centered over the tumor, the cisterna magna is opened to drain CSF. Although invasive, the tumor usually is surrounded by a pseudocapsule facilitating identification and removal from the surrounding brain. CAN and ultrasound are also helpful in this regard.

Using microsurgical techniques, the tumor is internally debulked using an ultrasonic aspirator and a self-retaining retractor to minimize cerebellar retraction. The surgeon must anticipate the location of critical structures such as the posterior inferior cerebellar artery, inferior vermian veins, cranial nerves (in the case of laterally

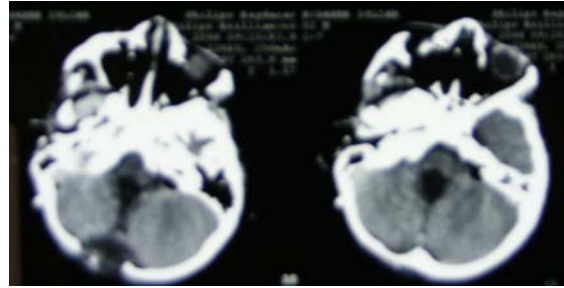
placed tumors), the dentate nuclei, the cerebellar peduncles, and the floor of the fourth ventricle. Often, the tumor can be gently peeled from these structures without damaging the pial membrane. The surgeon places cottonoids along the cisterna magna and along the roof and floor of the fourth ventricle to prevent iatrogenic dissemination of tumor along CSF pathways as these structures are exposed.

Invasive tumor is aggressively resected from the cerebellum and, if required, a single cerebellar peduncle. However, aggressive resection of tumor invading the floor of the fourth ventricle or the second cerebellar peduncle is avoided to reduce unacceptable postoperative morbidity.

After as complete a gross resection consistent with good neurologic function has been achieved, the resection cavity is reinspected using microscopic magnification, CAN, and ultrasound to identify and then resect any residual tumor, cerebellar hematoma, or retraction injury. Meticulous hemostasis minimizes postoperative nausea, vomiting, and hydrocephalus.

A watertight closure of the dura is performed using tisseal or fibrin glue to avoid CSF leak, pseudomeningocele, and chemical meningitis. Postoperatively, the ventriculostomy is drained until the blood clears, and then the patient weaned from ventricular drainage if possible.

Postoperative MRI with and without contrast is done within 48 hours postoperatively, both as a baseline and to assess extent of resection. MRI of the spinal axis should be performed approximately 2 weeks after surgery if it has not been done preoperatively. (Figure 5-personal case)



**Figure 5** (Postoperative aspect- CT scan same personal case shown in Fig 1&2)

If significant resectable residual neoplasm is seen or the patient requires a ventriculoperitoneal shunt, prompt reoperation is indicated to avoid delay of postoperative radiation therapy and chemotherapy.

Operative mortality should be well under 1%; morbidity is 5% to 10% in most series.[41]

Most common complications are transient, including ataxia, nystagmus, and dysmetria. Cranial nerve palsies are related to manipulation along the floor of the fourth ventricle.

Cerebellar mutism may also be induced by damage to the dentate nuclei. It is advisable to wait 10 to 14 days after surgery before beginning radiation therapy to ensure adequate wound healing and minimize the possibility of wound dehiscence.

### **Radiation therapy**

When radiation therapy is used in newly diagnosed patients, the standard dose delivered to the craniospinal axis is 35 to 36 Gy if patients have no evidence of neuraxis dissemination (M0). The PF is then boosted for an additional 18 to 20 Gy so that the total dose to the PF is approximately 54 to 56 Gy. If CSF cytology is positive (M1), the recommended dose to

the CSA according to the pediatric experience is still only 36 Gy. If nodular disease in the subarachnoid space (M2 or M3) is present, a boost is delivered immediately following CSI to the site of the original metastatic disease (M2 to M3) up to a total dose of 45 Gy. The fractionation scheme used most often is 1.8 Gy daily, 5 days per week.

The current standard therapy is to boost the entire PF to a total dose of 54 to 55.8 Gy at a fractionation of 1.8 Gy per day using high-energy photons (x-rays). There are no convincing data that administering higher doses to the PF by conventional fractionation or hyperfractionated treatment schedules improves outcomes,[55] although boosting residual disease with a stereotactic radiosurgical boost has shown promise in a limited number of patients.[52,64]

The duration of radiation therapy may also influence outcomes. Taylor et al[61] showed a statistically significant reduction in overall survival and EFS if the time from the first radiation treatment to the last radiation treatment was more than 50 days. In this study, there was no difference in the mean or median duration of radiation therapy between those patients treated with radiation therapy alone and those treated with chemotherapy followed by irradiation. It is advisable to complete radiation therapy without breaks.

Complications associated with radiation therapy can be divided into two time frames: acute effects occurring during or shortly after treatment, and late effects occurring months to years after completion of treatment.

Acute side effects in adults are usually more pronounced than in children and consist of nausea, vomiting, fatigue,

alopecia, skin erythema, significant bone marrow suppression, soreness in the back of the throat with resultant dysphagia, transient loss of taste, transient xerostomia, and occasionally wound dehiscence (usually when there is not an adequate 10- to 14-day interval between surgery and initiation of radiation therapy). Late effects are generally less prominent in adults than in children and include potential pituitary dysfunction, possible infertility, effects on cognition, and possible induction of second malignancies. Although the neurocognitive effects in treated adults have not been studied as extensively as in children, there are data to suggest that cranial doses of 30 to 36 Gy may have an impact on cognitive function in survivors, especially on memory, reasoning, visuospatial ability, and arithmetic calculation skills.[40]

### **Chemotherapy**

The usefulness of chemotherapy has been established in the pediatric medulloblastoma population. However, for adults with medulloblastoma, the role of chemotherapy is not yet established. The most commonly used regimen is the Packer regimen, which consists of weekly vincristine during CSI and eight cycles of CCNU, cisplatin, and vincristine (CCV) after CSI for children with medulloblastoma. This has become the standard against which all other chemotherapy regimens are measured.[49] There has not been a preradiation chemotherapy combination used in a randomized trial that has shown better efficacy as measured by overall survival or progression-free survival, although a recently reported study by Taylor et al describes EFS at 5 years that is comparable. [61]



The most notable dose-limiting side effects of this CCV-chemotherapy combination are peripheral neuropathy, hearing loss, renal insufficiency, and myelosuppression. As with most chemotherapy regimens, occasional patients succumb to overwhelming infection.

Less serious side effects include nausea, vomiting, constipation, obstipation, and elevated transaminases. Hundreds of children have been treated with this combination, but there is little in the literature to describe the tolerance that adults have to the same combination. Whereas the thrust of recent pediatric trials has been to add chemotherapy to decrease the dose of craniospinal axis radiation and thereby decrease the harmful effects of radiation on neurocognitive and endocrine function such as low full-scale intelligence quotients (IQs) and short stature, there has not been a comparable effort in treating adults for several reasons. These reasons include the fact that there is an approximate 60% 5-year progression-free survival rate with surgery and CSI alone [8] a belief that there is less harm to giving standard radiation doses to adults than children, and a less convincing case for a survival benefit to receiving chemotherapy as part of initial therapy. As a result, there is a perception among many clinicians that one can safely rely more on radiation and omit chemotherapy. However, there has been little formal investigation of neuropsychologic sequelae in adults who are long-term survivors of medulloblastoma.

In the largest series of adult patients reported to date, a retrospective analysis involving 156 patients treated at 13 institutions in France, Carrie et al concluded that 5- and 10-year EFS rates of

61% and 48%, respectively, were similar to those observed in children.

Their ultimate conclusion was that radiation therapy at the usual dose without chemotherapy should be considered the standard postoperative treatment in adults with medulloblastoma.

Greenberg et al [30] retrospectively analyzed a group of adults diagnosed between 1991 and 1997 who were treated at one of three institutions with chemotherapy consisting of the Packer regimen<sup>51</sup> or a POG protocol consisting of preradiation chemotherapy with cycles of cisplatin and etoposide alternating with cyclophosphamide and vincristine<sup>15</sup> followed by CSI.

There is agreement among those who have written about the management and treatment of medulloblastoma in adults that patients should have maximal safe tumor resection followed by CSI. The role of and type of chemotherapy that should be employed and when it should be used remains less clear.

Most neuro-oncologists would agree that patients with poor-risk medulloblastoma should also be treated with chemotherapy as part of initial therapy, but there is not agreement about its use in average-risk patients. There is a suggestion that combinations of cyclophosphamide or ifosfamide plus carboplatin or cisplatin plus vincristine with or without etoposide may be as effective and less toxic to adults than the Packer CCV regimen. Clinical trials in the adult population would help clarify the role of chemotherapy, especially in patients with average-risk disease.

## Outcome

The ability to categorize patients by risk factors has led to specific tailoring of treatment for the pediatric population,[66] and it is against these results that adult studies need to be compared.

Since the initial encouraging reports describing the use of combination chemotherapy and reduced-dose radiation therapy by Packer et al [51] in the early 1990s, this approach has become the standard of care at most pediatric institutions. In 1999, Packer et al [49] reported the results of a CCG study using a reduced craniospinal dose (23.4 Gy) of irradiation given with weekly vincristine followed by chemotherapy consisting of CCNU, vincristine, and cisplatin for eight cycles following CSI for average-risk patients between the ages of 3 and 10 years. The total dose to the PF remained at 55.8 Gy. The progression-free survival rates were 86% at 3 years and 79% at 5 years, which were more favorable than historical comparisons from previous CCG or POG studies. In 2003, Taylor et al [61] reported the results of a European prospective randomized trial in which pediatric patients with M0 and M1 disease were randomized to radiation therapy alone versus preradiation therapy chemotherapy with vincristine, etoposide, carboplatin, and cyclophosphamide.

The radiation therapy consisted of 35 Gy CSI in 1.67 Gy daily fractions followed by a PF boost of 20 Gy for a total PF dose of 55 Gy in both treatment arms. The EFS was superior in the patients who received preradiation chemotherapy, with EFS at 5 years of 74% versus 59.8% in the patients who received radiation therapy alone.

Improvements in imaging modalities, surgical techniques, and the precision of

radiation therapy delivery, as well as the addition of systemic chemotherapy over the past 2 decades, have contributed to the increased overall survival in pediatric series. It is more difficult to assess improvement in the outcome of adults with medulloblastoma because of the paucity of patients and lack of prospective or randomized adult trials.

It is most likely that the improvement in survival of these groups is related most to the improvements in surgical techniques, radiation therapy, and imaging and probably less to the improvements in the addition of chemotherapy, at least in the adult population.

## Conclusions

Medulloblastoma represent an important therapeutical problem of pediatric neurosurgical pathology.

MRI of the head and spine represent an efficient and early diagnostic procedure.

There is a high probability of CSF dissemination in medulloblastoma natural history.

The authors emphasize the role of the multimodal therapy.

Severe prognosis is expected in this condition - overall survival ranges from 25% to 84% at 5 years with 10-year survival rates ranging from 35.6% to 51%. [44,45,46]

### Correspondence to:

rsneurosurgery@gmail.com

claudiu\_palade@yahoo.com

## References

1. Abacioglu U, Uzel O, Sengoz M, et al: Medulloblastoma in adults: treatment results and prognostic factors. *Int J Radiat Oncol Biol* 54:855–860, 2002.

2. Becker RL, Backer AD, Sobel DF: Adult medulloblastoma: review of 13 cases with emphasis on MRI. *Neuroradiology* 37:104–108, 1995.
3. Berman DM, Karhadkar SS, Hallahan AR, et al: Medulloblastoma growth inhibition by hedgehog pathway blockade. *Science*, 297:1559–1561, 2002.
4. Bloom HJG, Wallace MB, Henk JM: The treatment and prognosis of medulloblastoma in children: a study of 82 verified cases. *Am J Roentgenol Rad Ther Nucl Med* 105:43–62, 1969.
5. Bourguoin PM, Tampieri D, Grahovac SZ, et al: CT and MR imaging findings in adults with cerebellar medulloblastoma: comparison with findings in children. *Am J Radiol* 159:609–612, 1992.
6. Burger PC, Scheithauer BW, Vogel FS: *Surgical Pathology of the Nervous System and Its Coverings*. New York, Churchill Livingstone, 2002.
7. Carrie C, Lasset C, Alapetite C, et al: Multivariate analysis of prognostic factors in adult patients with medulloblastoma. *Cancer* 74:2352–2360, 1994.
8. Chan AW, Tarbell NJ, Black PM, et al: Adult medulloblastoma: prognostic factors and patterns of relapse. *Neurosurgery*, 47:623–632, 2000.
9. Chang CH, Housepain EM, Herbert CJ: An operative staging system and a megavoltage radiotherapeutic technic for cerebellar medulloblastomas. *Radiology* 93:1351–1359, 1969.
10. Ciurea AV: Medulloblastomas in Ciurea AV: *Treatise of Neurosurgery* (eds), Medical Publishers House, Bucharest, 2010
11. Ciurea AV, Constantinovici A: Medulloblastoma in *Practical Handbook of Neurosurgery*, Medical Publishers House, Bucharest, 1998
12. Coffin CM, Mukai K, Dehner LP: Glial differentiation in medulloblastomas. *Am J Pathol* 7:555–565, 1983.
13. Cushing H: Experience with the cerebellar medulloblastomas. *ACTA Pathol Microbiol Scand* 7:1–86, 1930.
14. Cutler EC, Sosman MC, Vaughan WW: The place of radiation in the treatment of cerebellar medulloblastomata. *Am J Roentgenol Rad Ther Nucl Med* 35:429–445, 1939.
15. Douglas JG, Barker JL, Ellenbogen RG, Geyer JR: Concurrent chemotherapy and reduced-dose cranial spinal irradiation followed by conformal posterior fossa tumor bed boost for average-risk medulloblastoma: efficacy and patterns of failure. *Int J Radiat Oncol Biol Phys* 58:1161–1164, 2004.
16. Duetsch M, Thomas PRM, Krischer J: Results of a prospective randomized trial comparing standard dose neuraxis irradiation (3,600 cGy/20) with reduced neuraxis irradiation (2,340 cGy/13) in patients with low-stage medulloblastoma. *Pediatr Neurosurg* 24:167–177, 1996.
17. Duffner PK, Horowitz ME, Krischer JP, et al: Postoperative chemotherapy and delayed radiation in children less than three years of age with malignant brain tumors. *N Engl J Med* 328:1725–1731, 1993.
18. Eberhart CG, Kepner JL, Goldthwaite PT, et al: Histopathologic grading of medulloblastoma. *Cancer* 94:552–560, 2002.
19. Ellison D: Classifying the medulloblastoma: insights from morphology and molecular genetics. *Neuropathol Appl Neurobiol* 28:257–282, 2002.
20. Evans AE, Jenkin RDT, Spoto R, et al: The treatment of medulloblastoma. *J Neurosurg* 72:572–582, 1990.
21. Freeman CR, Taylor RE, Kortmann R, et al: Radiotherapy for medulloblastoma in children: a perspective on current international clinical research efforts. *Med Pediatric Oncology* 39:99–108, 2002.
22. Frost PJ, Laperriere NJ, Shun Wong C, et al: Medulloblastoma in adults. *Int J Radiat Oncol Biol Phys* 32:951–957, 1995.
23. Giangaspero F, Bigner SH, Kleihues P, et al: Medulloblastoma. In Kleihues P, Cavenee WK (eds): *Pathology and Genetics of Tumors of the Nervous System*. Lyon, France, IARC Press, 2000.
24. Giangaspero F, Cenacchi G, Roncaroli F, et al: Medullocytoma (lipidized medulloblastoma). *Am J Surg Pathol* 20:656–664, 1996.
25. Giangaspero F, Chieco P, Ceccarelli C, et al: “Desmoplastic” versus “classic” medulloblastoma: comparison of DNA content, histopathology and differentiation. *Virchow Arch* 418:207–214, 1991.
26. Giangaspero F, Perilongo G, Fondelli MP, et al: Medulloblastoma with extensive nodularity: a variant with favorable prognosis. *J Neurosurg* 91:971–977, 1999.
27. Giangaspero F, Rigobello L, Badiali M, et al: Large cell medulloblastoma: a distinct variant with highly aggressive behavior. *Am J Pathol* 16:687–693, 1992.
28. Gilbertson R, Wickramasinghe C, Herman R, et al: Clinical and molecular stratification of disease risk in medulloblastoma. *Br J Cancer* 85:705–712, 2001.
29. Giliemorth J, Kehler U, Knopp U, et al: A multifocal cerebellar and supratentorial medulloblastoma in an adult. *Acta Neurochir (Wien)* 140:723–724, 1998.
30. Giordana MT, Duo D, Gasverde S, et al: MDM2 Overexpression is associated with short survival in adults with medulloblastoma. *Neuro-oncology* 4:115–122, 2002.
31. Giordana MT, Schiffer P, Lanotte M, et al: Epidemiology of adult medulloblastoma. *Int J Cancer* 80:689–692, 1999.
32. Goldberg-Stern H, Gadoth N, Stern S, et al: The prognostic significance of glial fibrillary acidic protein staining in medulloblastoma. *Cancer* 68:568–573, 1991.

33. Greenberg HS, Chamberlain MC, Glantz MJ, et al: Adult medulloblastoma: multiagent chemotherapy. *Neuro-oncology* 3:29–34, 2001.
34. Haie-Meder C, Song PY: Medulloblastoma: Differences in adults and children—regarding Frost et al: *IJROBP* 32: 951–957; 1995 and Prados et al: *IJROBP* 32:1145–1152; 1995. *Int J Radiat Oncol Biol Phys* 32:1255–1257, 1995.
35. Hernan R, Fasheh R, Calabrese C, et al: ERBB2 up-regulates S100A4 and several other prometastatic genes in medulloblastoma. *Cancer Res* 63:140–148, 2003.
36. Hubbard JL, Scheithauer BW, Kispert DB, et al: Adult cerebellar medulloblastomas: the pathological, radiographic, and clinical disease spectrum. *J Neurosurg* 70:536–544, 1989.
37. Hyman AD, Lanzieri CF, Solodnik P, et al: Cystic adult medulloblastoma. *CT. J Comput Tomogr* 10:139–143, 1988.
38. Janss AJ, Yachnis AT, Silber JH, et al: Glial differentiation predicts poor clinical outcome in primitive neuroectodermal brain tumors. *Ann Neurol* 39:481–489, 1996.
39. Katsetos CD, Herman MM, Frankfurter A, et al: Cerebellar desmoplastic medulloblastomas. A further immunohistochemical characterization of the reticulin-free pale islands. *Arch Pathol Lab Med* 113:1019–1029, 1989.
40. Kim JY, Sutton ME, Lu DJ, et al: Activation of neurotrophin-3 receptor TrkC induces apoptosis in medulloblastomas. *Cancer Res* 59:711–719, 1999.
41. Koci TM, Chiang F, Mehringer CM, et al: Adult cerebellar medulloblastoma: imaging features with emphasis on MR findings. *AJNR: Am J Neuroradiol* 14:929–939, 1993.
42. Kortmann RD, Kuhl J, Timmerman B, et al: Postoperative neoadjuvant chemotherapy before radiotherapy as compared to immediate radiotherapy followed by maintenance chemotherapy in the treatment of medulloblastoma in childhood: results of the German prospective randomized trial HIT 91. *Int J Radiat Oncol Biol Phys* 46:269–279, 2000.
43. Kramer JH, Crowe AB, Larson DA, et al: Neuropsychological sequelae of medulloblastoma in adults. *Int J Radiat Oncol Biol Phys* 38:21–26, 1997.
44. Kunschner LJ, Kuttesch J, Hess K, et al: Survival and recurrence factors in adult medulloblastomas: the MD Anderson Cancer Center Experience from 1978 to 1998. *Neuro-oncology* 3:167–173, 2001.
45. Leonard JR, Cai DX, Rivet DJ, et al: Large cell/anaplastic medulloblastomas and medulloblastomas: clinicopathological and genetic features. *J Neurosurg* 95:82–88, 2001.
46. MacDonald TJ, Brown KM, LaFleur B, et al: Expression profiling of medulloblastoma: PDGFRA and the RAS/MAPK pathway as therapeutic targets for metastatic disease. *Nat Genet* 29:143–152, 2001.
47. Mahapatra AK, Sinha AK, Sharma MC: Medulloblastoma: a rare cerebellar tumor in children. *Childs Nerv Syst* 14:312–316, 1998.
48. Malheiros SM, Franco CM, Stavale JN, et al: Medulloblastoma in adults: a series from Brazil. *J Neurooncol* 60:247–253, 2002.
49. Millot F, Delval O, Giraud C, et al: High-dose chemotherapy with hematopoietic stem cell transplantation in adults with bone marrow relapse of medulloblastoma: report of two cases. *Bone Marrow Transplant* 24:1347–1349, 1999.
50. Moots PL, Jennings MT, Bowen MG, et al: Multiagent chemotherapy followed by craniospinal radiation (CSRT) for adults with poor risk medulloblastoma (MBL) and ependymoma with subarachnoid dissemination (D.E.). *Neurology* 50:A380 Abstract, 1998.
51. Moots PL, O'Neill A, Barger GR, et al: Toxicities associated with chemotherapy followed by craniospinal radiation for adults with poor-risk medulloblastoma/PNET and disseminated ependymoma: a preliminary report of ECOG 4397. *Annual Meeting Proceedings of the American Society of Clinical Oncology*, 23(Abst 1573):125, 2004.
52. Newton HB: Review of the molecular genetics and chemotherapeutic treatment of adult and pediatric medulloblastoma. *Expert Opin Investig Drugs* 10:2089–2104, 2001.
53. Packer RJ, Goldwein J, Nicholson HS, et al: Treatment of children with medulloblastomas with reduced-dose craniospinal radiation therapy and adjuvant chemotherapy: a Children's Cancer Group study. *J Clin Oncol* 17:2127–2136, 1999.
54. Packer RJ, Sutton LN, Elterman R, et al: Outcome for children with medulloblastoma treated with radiation and cisplatin, CCNU, and vincristine chemotherapy. *J Neurosurg* 81:690–698, 1994.
55. Packer RJ, Sutton LN, Goldwein JW, et al: Improved survival with the use of adjuvant chemotherapy in the treatment of medulloblastoma. *J Neurosurg* 74:433–440, 1991.
56. Patrice SJ, Tarbell NJ, Goumnerova LC, et al: Results of radiosurgery in the management of recurrent and residual medulloblastoma. *Pediatr Neurosurg* 22:197–203, 1995.
57. Peterson K, Walker RW: Medulloblastoma/primitive neuroectodermal tumor in 45 adults. *Neurology* 45:440–442, 1995.
58. Pomeroy SL, Tamayo P, Gassenbeek M, et al: Prediction of central nervous system embryonal tumor outcome based on gene expression. *Nature* 415:436–442, 2002.

59. Prados MD, Edwards MS, Chang SM, et al: Hyperfractionated craniospinal radiation therapy for primitive neuroectodermal tumors: results of a phase II study. *Int J Radiat Oncol Biol Phys* 43:279–285, 1999.
60. Prados MD, Warnick RE, Wara WM, et al: Medulloblastoma in adults. *Int J Radiat Oncol Biol Phys* 32:1145–1152, 1995.
61. Ramsay DA, Bonnin J, MacDonald DR, et al: Medulloblastomas in late middle age and the elderly: report of 2 cases. *Clin Neuropathol* 14:337–342, 1995.
62. Rao C, Friedlander ME, Klein E, et al: Medullomyoblastoma: a population-based study of 532 cases. *Cancer* 65:157–163, 1990.
63. Sarkar C, Pramanik P, Karak AK, et al: Are childhood and adult medulloblastomas different? A comparative study of clinicopathological features, proliferation index, and apoptotic index. *J Neurooncol* 59:49–61, 2002.
64. Segal RA, Goumnerova LC, Kwon YK, et al: Expression of the neurotrophin receptor TrkC is linked to a favorable outcome in medulloblastoma. *Proc Natl Acad Science USA* 91:12867–12871, 1994.
65. Soylemezoglu F, Soffer D, Onol B, et al: Lipomatous medulloblastoma in adults. *Am J Surg Pathol* 20:413–418, 1996.
66. Taylor RE, Bailey CC, Robinson K, et al: Results of a randomized study of preradiation chemotherapy versus radiotherapy alone for nonmetastatic medulloblastoma: The International Society of Pediatric Oncology/United Kingdom Children's Cancer Study Group PNET-3 Study. *J Clin Oncol* 21:1581–1591, 2003.
67. Thomas PRM, Deutsch M, Kepner JL, et al: Low-stage medulloblastoma: final analysis of trial comparing standard-dose with reduced-dose neuraxis irradiation. *J Clin Oncol* 18:3004–3011, 2000.
68. Tomita T, Rosenblatt S: Management of hydrocephalus secondary to posterior fossa tumors. In Matsumoto S, Tamaki N (eds): *Hydrocephalus: Pathogenesis and Treatment*. Tokly, Springer-Verlag, 1991.
69. Wolden SL, Dunkel IJ, Souweidane MM, et al: Patterns of failure using a conformal radiation therapy tumor bed boost for medulloblastoma. *J Clin Oncol* 21:3079–3083, 2003.
70. Woo C, Baldassarre S, Lulu B, et al: The use of stereotactic radiosurgical boost in the treatment of medulloblastoma. *Int J Radiat Oncol Biol Phys* 37:761–764, 1997.
71. Woodburn RT, Azzarelli B, Montebello JF, et al: Intense p53 staining is a valuable prognostic indicator for poor prognosis in medulloblastoma/central nervous system primitive neuroectodermal tumors. *J Neurooncol* 52:57–62, 2001.
72. Zeltzer PM, Boyett JM, Finlay JL, et al: Metastasis stage, adjuvant treatment, and residual tumor are prognostic factors for medulloblastoma in children: conclusions from the Children's Cancer Group 921 randomized phase III study. *J Clin Oncol* 17:832–845, 1999.