

Subarachnoid Hemorrhage

Yoko Kato, Hirotohi Sano

Department of Neurosurgery, Fujita Health University, Japan

Abstract

Intracranial aneurysms represent the most common etiology of nontraumatic subarachnoid hemorrhage. Management of intracranial aneurysms must be meticulous and tailor made for each patient. Various strategies in the management include main artery ligation, aneurysm neck occlusion, wrapping or coating, clipping or coiling. This article presents an overview on subarachnoid hemorrhage, pathophysiology, investigations, a management guideline and outcome in intracranial aneurysms.

Keywords: subarachnoid hemorrhage, cerebral blood flow, clinical grades aneurysm

Introduction

Modern management of intra-cranial aneurysms must be very meticulous and tailor made for each patient. Various strategies in the management include main artery ligation, aneurysm neck occlusion, wrapping or coating, clipping or coiling. Indications for treatment include unruptured symptomatic aneurysms, aneurysms with mass effect, cranial nerve deficits, ischemia, small leak, size less than 3mm, family history of aneurysms. Contraindications to treatment include elderly patients, medical comorbidity and intra-cavernous aneurysms. Guidelines for treatment in Japan include young age- less than 6, history of previous rupture, family

history of SAH, large aneurysms more than 7 mm, symptomatic patient, increasing size of aneurysm on follow-up, location of the aneurysm in a low surgical risk area.

Epidemiology

Epidemiological studies have shown that 60% of patients die or are disabled due to aneurismal rupture, with the primary cause of death being an initial bleed or a rebleed with vasospasm. Subarachnoid hemorrhage (SAH) caused by the rupture of an intracranial aneurysm is one of the most common neurosurgical emergencies with one third of strokes having SAH and aneurysms accounting for 70% of these. Aneurysms rupture in a rate of 12 per 100,000 population per year, especially in the 5th and 6th decades, with high mortality and morbidity, especially from the first hemorrhage in about 43% of the cases and surgeons can attempt to avoid re-bleed, since surgery and the strategies for management have become very safe with modern technical gadgets. 2.5% of normal population can harbor unruptured aneurysms with a prevalence of 0.65% with a preponderance of aneurysms in the ratio of 2: 1 among women. ICA aneurysms are more common in women, where as Acorn aneurysms are more common in men, with presence of multiple aneurysms in 15 - 30% of the patients. With gain of more operative skill and experience, it is safer to deal with these aneurysms regardless of their size or Position.

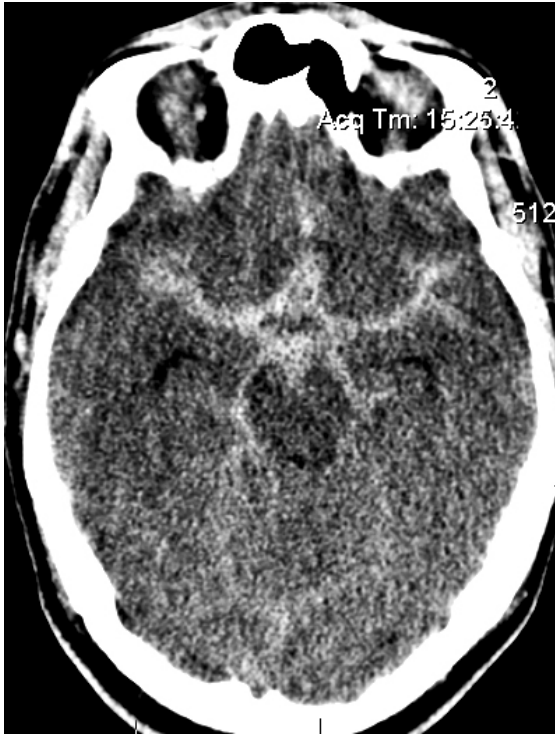

Figure 1 CT scan of the brain showing subarachnoid hemorrhage

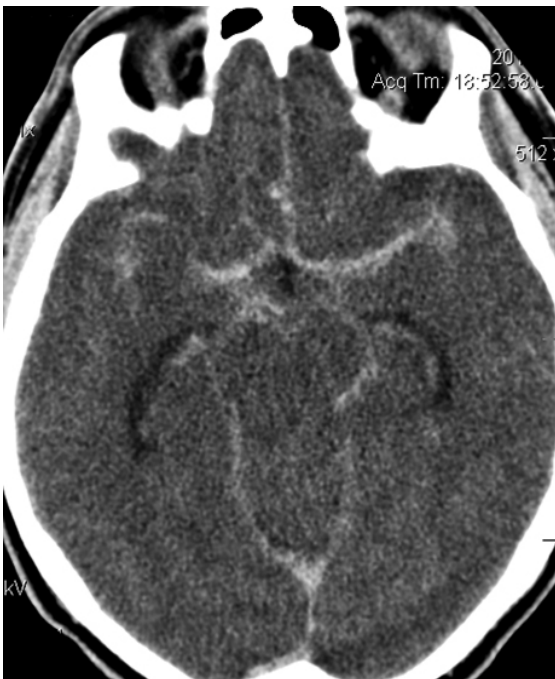

Figure 2 Axial CT scan of the brain showing subarachnoid hemorrhage

Surgical decision making, timing of surgery, prevention of re-bleed, use of endovascular techniques along with grade of the patient, presence or absence of intraparenchymal or intraventricular bleed, with or without vasospasm, affect the outcome.

Etiopathogenesis and Neurogenetics

The exact etiopathogenesis of intracranial aneurysms is not clear. Implications of risk factors include smoking, hypertension, genetic factors with association of connective tissue disorders like polycystic kidney disease, Ehler's – Danolos syndrome Type IV, Marfan's Syndrome, NF-1, pseudoxanthoma elasticum and Alpha-1 antitrypsin deficiency. At least 5% of patients detected with intracranial aneurysms have heritable connectivity tissue disorder. It can also arise due to new mutations. In patients with polycystic kidney disease, one in four patients have aneurysms and account for 6 to 7% of all patients. Sub-arachnoid hemorrhage and mortality is more in patients with polycystic kidney disease. The gene is localized on chromosome 16 and chromosome 4. Similarly, Type - IV Ehler's -Danolos syndrome have the gene located in pro-alpha 1-3 chain collagen Type III of chromosome 2. Patients with alpha-I antitrypsin deficiency suffer with vascular problems like aneurysms, arterial dissections and FMD. With risk of sub-arachnoid bleed, the gene is located on allele PiZ and PiS marker genes on chromosome 14, WHICH is a polymorphic gene. Patients with Marfan's syndrome have gene mutation encoding fibrillin-1, which is involved in connective tissue structural integrity. In NF-1, gene encoding neurofibromin with GAP - Guanosine

Triphosphate Activating Protein - is involved.

In pseudo xanthoma elasticum, the elastic fibers and basic molecular defect is involved in the vessels and is an autosomal recessive and / or dominant variant, mapped on to chromosome 16p13.1. Familial aneurysms are not associated with heritable CTD. The actual inheritance pattern is not known but an inheritance either autosomal dominant or recessive or multifactorial type of transmission may be involved with genetic heterogeneity. They have a tendency to rupture 5 years earlier than sporadic aneurysms and also rupture at a size smaller by 2 mm than the sporadic variants.

Screening studies for detection of familial intracranial aneurysms has been performed by CT angiography or MR angiography and is indicated even in asymptomatic first degree relatives in families with two or more affected members with a detection rate of 10% and with aneurysms detected in 30% of these patients, being larger than 5mm in diameter. There are no actual guidelines for screening. However, a medical history, family history, physical examination, genetic counseling, renal sonography, collagen analysis and screening of relatives is warranted. Advances in genetics have made linkages to chromosomal locus or an intracranial aneurysm gene. Genetic polymorphism of angiotensin 1 converting enzyme and endoglin genes may be implicated in these patients.

Risk factors

There are several confounding factors which determine the rate of rupture like the size of the aneurysm, the location, multiplicity, growth, symptoms, age, sex

and a predisposing history of hypertension and/or smoking. The most important variable is the size of the aneurysm. The risk of rupture is very less in aneurysms, less than 10 mm (1.4% - 1.8% per year). Several investigations by Rinkel and colleagues, ISUI Data give a cumulative rate of rupture between 0.05% per year for less than 10 mm Size aneurysms and 1% for those larger than 10 mm and 6% for those larger than 25mm. Patients with larger than 25mm have a grave prognosis.

The location of the aneurysm is an independent variable with greater risk in posterior circulation aneurysms than in anterior circulation aneurysms - (42% vs 7% in several studies). Approximately, 15 - 20% of patients harboring aneurysms: have multiple aneurysms and the Finnish data supports a greater likelihood of rupture in such patients. Japanese data also supports an increased risk of rupture in multiple aneurysms. The growth of the aneurysm is not a conclusive determinant for rupture.

Aneurysms with clinical features, unrelated to hemorrhage, are said to be symptomatic and may manifest with mild or recurrent headaches, cranial nerve palsies, brain stem signs in about 20 - 32% of the cases. Risk of rupture also is 8 - 10 times higher in a symptomatic aneurysm, than in an asymptomatic one. More often, symptomatic aneurysms are found in greater incidence in the posterior circulation than in the anterior circulation.

Increasing age, causes an increase in the risk of aneurysmal rupture, evident in several studies with a rupture rate of 45 - 50% in patients in more than 60 years and about 25% in younger patients with aneurysms less than 10 mm. Hypertension, as an independent risk factor for aneurysmal rupture, is not conclusively proved.

However, data suggests that co-existence of hypertension and sub-arachnoid hemorrhage can be more risky with greater incidence of complications.

Cigarette smoking increases the risk of rupture by 2.5 times and causes rupture in younger age groups. It is more often seen in women than in men. Assessment of the natural history, the availability of investigations and capability for effective management, determines the effective plan and management criteria that should be tailor-made for every patient.

The American Heart Guidelines have published several criteria for management of aneurysms and recommended clipping for aneurysms greater than 5 - 7 mm in diameter with acceptable risk. Management should be tailor-made based on the surgical skill, experience, patient's age, availability of other modalities of treatment etc.

Pathophysiology

Sub-arachnoid hemorrhage is the pathological condition with existence of blood in the sub-arachnoid space, which occurs spontaneously without any traumatic etiology. The blood escaping from the aneurysm may vary from a very small warning leak to massive amounts (more than 150 ml) and can lead to death. The consequences depend upon the location of the bleed, the volume of bleed, the volume of CSF space, age of the patient, pre-morbid conditions, clinical grade, risk of vasospasm, seizures, hydrocephalus, ICP, cerebral blood flow, cerebral metabolism and systemic implications of hyponatremia, hypovolemia, catabolic state and cardiac arrhythmias.

High flow rates of aneurysms with tear of the wall produce large volume SAH in a short time with rapid rise of ICP, whereas,

a small continuous leak may gradually increase the SAH. There is a progressive increase in the ICP with worsening grade, with an average of 10 mm Hg, in clinical Grade I and II and 15 mm Hg with clinical Grade II and III and 30 mm Hg in clinical Grade III to V.

Other causes of sub-arachnoid hemorrhage like infections, trauma, drug intoxications AVM ruptures, amyloidosis, SLE, PAN, CVT, pregnancy, hematological disorders like leukemia, lymphoma, myeloma, DIC etc., must be ruled out apart from other intracranial space occupying lesions.

The cerebral blood flow is globally decreased after SAH to about 35 - 45 ml/100gm/min in patients with Grade I to IV without vasospasm and 33 - 38 ml/100gm/min in patients with Grade I to IV with vasospasm. The CMR02 - cerebral metabolic rate of oxygen, is markedly reduced. Vasospasm caused narrowing of skull base vessels and dilation of distal intracerebral vessels. The cerebral blood flow and metabolism is reduced for weeks together after SAH. Development of infarction is heralded by CMR02 fall with increased hyperemia. The toxic effect of sub-arachnoid blood by a neural mechanism can cause global ischemia, lactic acidosis, mitochondrial respiration, sodium-potassium ATP activity and extra-cellular calcium and potassium alterations. The blood pressure, the partial pressure of carbon-di-oxide, also get altered with an impaired auto regulation, depending upon the extent of the vasospasm and the reduction in the cerebral blood flow, causing vasomotor paralysis. Intra-arterial Xenon-133, transcranial Doppler's studies have demonstrated impaired CO₂ reactivity.

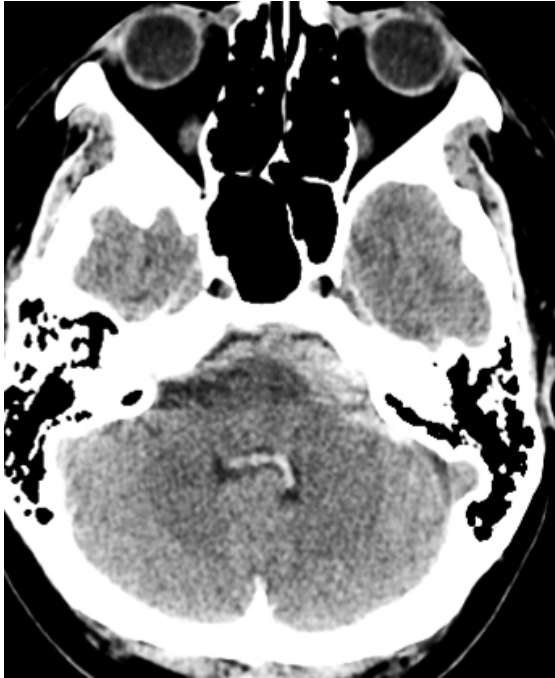

Figure 3 Axial CT scan: subarachnoid hemorrhage of posterior cranial fossa and in the fourth ventricle

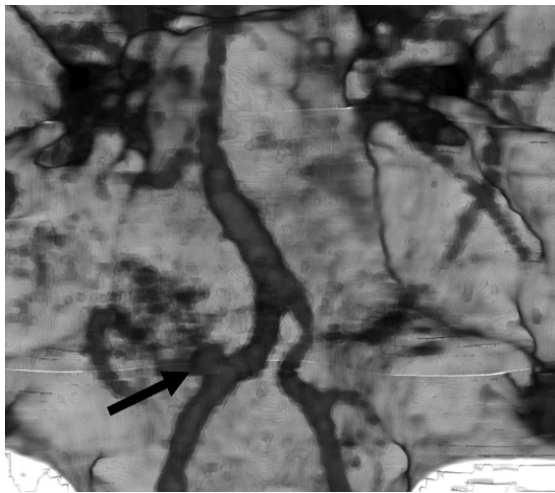


Figure 4 CT angiography reconstruction of posterior inferior cerebellar artery (PICA) Aneurysm

Clinical Features

Patients can have a sudden severe headache, never experienced earlier in their life, coming as a bolt from the blue. Some individuals can have warning bleeds with severe headaches of sudden onset associated

with nausea, vomiting, giddiness etc. The warning hemorrhage is extremely important to prevent a catastrophic SAH and must not be misdiagnosed. Features like vomiting, onset of headache with exertion, altered level of consciousness, meningism, focal deficits are all sinister and ominous.

Depending on the site and size of the aneurysm, patients can have hemiparesis, monoparesis, visual field loss, visual loss with or without diplopia and extra-ocular movement impairment. Patients can also have dysphasia and dysarthria. Loss of consciousness and mucal rigidity is a very important finding. Sudden death can occur in up to 15% of the patients with large SAH. 3rd nerve palsy and other cranial nerve deficits can occur. The diagnosis must not be confused with viral headaches, systemic infection, migraine, hypertension, cervical spine pathologies, intra-cranial space occupying lesions, sinusitis, aseptic meningitis and intoxications.

Depending on the site of the aneurysm, patients can have specific symptomatology in the form of bilateral lower limb weakness in ACA ruptures, hemiparesis, hemianopia, dysarthria, dysphasia and paresthesia with MCA ruptures, seizures with ACA or ACom ruptures, 3rd nerve lesions with ICA or PCA lesions, unilateral visual loss with carotid ophthalmic aneurysms etc. Focal deficits, vasospasm, seizures and mass lesion due to bleed can confound and complicate signs and symptoms. 25% of patients can have vitreous hemorrhage and hemiparesis. Aneurysm ruptures are also associated with specific causative factors like sudden exertion, lifting weights, emotional strain, defecation, coital acts, profound coughing or during parturition.

Investigations

Non-enhanced CT (NECT) remains the first step in diagnosis with majority of cases being detected on the day of ictus. Patients may have SAH, IVH, ICH, SDH or hydrocephalus at the time of first CT itself. With facilities of high resolution scannings, CT-angio can be performed at the same sitting. The volume of blood on CT is a factor for prognostication in relation to vasospasm and outcome, with a system of grading proposed by Fisher. In cases of doubt regarding SAH, lumbar puncture may be performed in the absence of raised ICP, which shows a constant count of RBCs of a few thousands to about 300 cells per cc and the blood having a propensity not to clot. The spectrophotometry of the sample shows xanthochromia. Microscopy shows a decrease in RBC: WBC count and an increase in the protein and CSF pressure. Hemosiderin laden macrophages are seen after a few days. A tap at another level also reveals a constant count of RBCs.

Catheter based 4-vessel angiography is the gold standard and is usually performed in all cases, except in several centers with very good CT-angio facilities. Magnification, subtraction and stereoscopy will delineate the cause of the bleed, the site of the lesion, the shape of the lesion, the direction of the aneurysm and the dome-neck relationship. Risk of angiography and rupture during angiography are complications which are very rare.

In multiple aneurysms, the site of the aneurysm which has bled, can be reliably deciphered by following an algorithm - exclusion of extra-dural aneurysms, CT with contrast, site of vasospasm or mass

effect on angiography, an irregularly shaped aneurysm, focal deficits, highest chance of rupture in accordance with statistics and repeated studies. The most proximal and the largest aneurysm which is irregular in shape, usually ruptures. In among 10 - 30% of the patients, no actual cause of SAH is found. An MRI or an MRA in such patients or repeated angiograms may delineate a missed lesion, especially in the ACom territory and perimesencephalic area.

Investigations for diagnoses can be performed by a Multi-phase 256 row multi-slice CT scan and 4D CT, which is much better than 64 row multi-slice CT. It gives a very good multi-phasic scan and helps in delineating the artery, vein and the bone very clearly. Even very small aneurysms are very clearly depicted. 4D CT and dynamic flow, also called 'ECG gated Helical CT', is extremely advantageous in identification of a thin wall region and helps in detecting dangerous, unruptured aneurysms, impending ruptures and help in either clipping or coiling. The hemodynamic stress at the site of bifurcation and analysis of the dynamic flow in large aneurysms, the stress at the bifurcation of aneurysms are very clearly portrayed. Apart from this, the jet flow in the parent artery can be made out very clearly. However, in many centers, the gold standard of diagnoses remains 4-vessel digital angiography.

Clinical grading

Clinical grading is important to document the condition on arrival, prognostication and usefulness of the method of treatment. Botterell grade, Hunt and Hess's grad and the WFNS grade of aneurismal bleed is tabulated below.

Grade	Botterell Classification	Hunt and Hess	WFNS
I	Conscious +/- symptoms of SAH	Asymptomatic/minimal headache/slight mucal rigidity	GCS 15, no motor deficits
II	Drowsy, no deficits	Moderate headache and mucal rigidity / no deficits other than cranial nerve palsy	GCS 13 - 14, no deficits
III	Drowsy, with deficits, with ICH	Drowsy, confused with mild focal deficit	GCS 13 - 14, with deficits
IV	Major deficit, large clot	Stuper. moderate to severe hemiparesis, early decerebration and vegetative state	GCS 7 - 12, with / without deficits
V	Moribund state with extensor rigidity	Deep coma, decerebration, moribund state	GCS 3 - 6, with or without deficits.

Management Guidelines

A proper history, physical examination and assessment of the airway, breathing, circulation, level of consciousness, cranial nerve, sensory and motor function are all mandatory. Emergent placement of an EVD may be necessary and life-saving. Unconscious patients must be intubated and ventilated. Intra-thecal TPA may be required for reducing the risk of re-bleed. Treatment is based on the history, findings, age, grade, location, size, site, family history, associated diseases etc.

Patients must be kept in ICU setting in a darkened room, limited visitors and minimal external stimulation and least mobilization, with good analgesia and adequate oxygen apart from measures to prevent DVT. The vital signs, neurological chart, the TCD must be monitored at regular intervals. If facilities are available, cerebral blood flow also can be monitored. A CVP or Swan-Ganz catheter can be placed for assessing intravascular volume status for fluid replacement. Fluid intake

must be regulated, depending upon the output and must be approximately around 2 - 3 liters. The hematocrit should be maintained more than 30% for maintaining good oxygenation. Advantages with HHH therapy are controversial.

Nirnodipine, in a dose of 60 mg, 4th hourly, with SAH Grade I - III may help and is recommended for three full weeks. Hypotension and intestinal obstruction must be watched for. Steroid use is controversial. The optimal blood pressure must be maintained so that the cerebral perfusion pressure is adequate. Administration of good analgesics, propofol, anti hypertensives like sodium nitroprusside, labetalol and other calcium channel blockers are given.

In patients with a Grade IV or a Grade V SAH, the initial management is to resuscitate the patient by intubation and administration of anti edema measures along with ventilation. The basic aim is to stabilize the patient and subsequently perform a head CT to evaluate for the

presence of subarachnoid hemorrhage and/or intracerebral hemorrhage. A CT angio can be done at the same sitting. If the patient has an intracerebral hemorrhage, 4-vessel angiogram can also be done. With the presence of hydrocephalus or intraventricular bleed, a ventriculostomy and a simultaneous introduction of an intracranial pressure monitoring device can be done.

An angiogram gives the diagnosis of the site of bleed, size of aneurysm, the direction of the sac, the association of other adjacent structures etc. With the patient's intracranial pressure well controlled and in those patients less than 65 years, without any medical problems, a craniotomy can be performed immediately. In very elderly gentlemen, patients with associated comorbid medical problems, the option of endovascular treatment can be considered. Also, in patients whose ICP is not controlled, endovascular treatment with coiling can be considered. Patients can be re-assessed after stabilization, improvement in intracerebral pressure and then taken up for rehabilitative measures.

ICH - increases the likelihood of mortality. Patients in whom the intracerebral hemorrhage is evacuated, younger age group, better clinical grade, smaller ICH volume less than 25 ml, are associated with better outcomes, than in patients who are comatose with brain stem compression and larger ICH.

Larger bone flaps are preferable to prevent brain herniation and strangulation, as also, good relaxation with mannitol and proper exposure with drilling of the sphenoid wing and orbital roof. Measures should be taken to prevent retraction of the brain and some times before closure, lobectomy or ventriculostomy or dural

augmentation without bone replacement may be necessary in severe cerebral swelling and herniation.

Acute hydrocephalus and intraventricular hemorrhage is associated with poor grade and an EVD is necessary in such patients. Infusion of urokinase has been tried without good outcome in several series. Vasospasm is associated with acute hydrocephalus and ventricular drainage, ventilation and hyperdynamic treatment is necessary.

Chronic hydrocephalus is seen in 1/4 of the patients with SAH and is associated with poor clinical grade, hypertension, alcoholism, female sex, pneumonia and meningitis. It requires a longer duration of EVD placement or lumbar puncture or laminar terminal fenestration or a shunt.

Within 48 hours after SAH the vasospasm is seen in 15% of the patients and is associated with arterial narrowing and poor prognosis. Immediate aneurismal obliteration and aggressive management of symptomatic vasospasm is required in patients such conditions to have a reasonable neurological recovery and prevent infarction.

Intra-operative aneurismal rupture, major vessel occlusion, cerebral contusion due to retraction, evacuation of ICH, decompression by lobectomy, inexperienced operator, improper technique and other primary factors not favoring an easy surgery like the aneurismal size, site, morphology, calcified necks etc., are associated with poor prognosis and post-operative complications even in pre-operatively good grade patients. They may also have neuro psychological, cognitive deficits after surgery.

Special situations of patients with advanced age, very young age, traumatic

aneurysms, mycotic aneurysms, pregnant ladies, aneurysms with AVMs, fusiform or microaneurysms or those associated with co-existing carotid artery disease or giant aneurysms or residual aneurysms, need to be treated with caution.

Advanced age is associated with poor outcome, as also aneurysms in children. They are usually in a very poor clinical grade and have other confounding factors like hypertension, atherosclerosis, vasospasm and other co-morbid medical complications that alter the operative outcome and post-operative sequelae. Pregnant ladies have major physiological alterations in the body, hormonal changes, risk to the foetus, more so in the last trimester and can lead to more risk for both the baby and the mother. Care should be taken to avoid hypotension, administration of mannitol, prevention of uterine hypoperfusion, fetal hyperosmolality, hyper ventilation and a stand-by team for a section in case there is a mishap during surgery. As far possible, surgery should be deferred until the end of the second trimester and drugs like anti-convulsants and calcium channel blockers must be avoided.

5 – 6% of the aneurysms are mycotic and are associated with infective endocarditis, immunocompromise with fungal infections, bacterial infections etc., and are located in the distal MCA territory. 50% resolve or reduce in size with antibiotic treatment and need to be followed up with serial blood cultures. Aneurysms associated with abscess or clots need to be operated with precautions for either excision, by-pass or ligation.

Less than 1% of aneurysms are traumatic and are usually due to penetrating injuries or stab wounds and manifest within 3 weeks after injury. A neck is usually not

found and are prone for intra-operative rupture. They may require encircling clips or trapping or excision, with or without by-pass.

Aneurysms with AVMs account for up to 15% cases and arise due to hemodynamic stress in AVMs at the site of branching. They may be of type-I, located at a distance from the AVM. In type-II, they are more proximal to the feeding vessel. Type-III lesions are pedicular varieties in the middle of the feeding pedicle and type-IV lesions are intranidal in the AVM. The treatment strategy, the natural history, management protocol for each of these is different. Skull-base aneurysms are more often fusiform and are located in the vertebro-basilar territory, characterized by dilatation, elongation, atherosclerosis, dolichoectasia and tortuosity of the vessels, associated with turbulence and thrombus formation causing ischemic symptoms. They usually require wrapping, anti coagulation and sometimes huntarian ligation.

Aneurysms less than 3mm are microaneurysms and cannot be either coiled or clipped. Open surgery with coagulation and wrapping may help. Co-existent lesions like carotid artery disease and aneurysms are treated with precedence given to the lesion with the worse natural history.

Giant aneurysms approximately represent 4% to 6% of intracranial aneurysms and have a high 2-year mortality between 60 - 100%. The aim is to prevent rupture and treat mass effect. Wide exposure, proximal and distal control and clip reconstruction are the basic technical considerations in these aneurysms. Cerebral protection with barbiturates, skull base techniques for vascular control and collaboration with other techniques help in giving a better prognosis.

Endovascular techniques can be used for aneurismal occlusion in anticipated surgical difficulty, medical contraindications and failed surgery. The limiting factors include a wide neck more than 4mm with a dome-to-neck ratio of less than 2 and inadequate endovascular access or an unstable intraluminal thrombus. Aneurysms of the MCA are those with a branch arising from the neck, are also difficult candidates.

By-pass techniques are not needed in patients who maintain a cerebral perfusion of more than 30 ml/100gm/minute, who are neurologically stable during occlusion and those who remain neurologically intact. The basic techniques in giant aneurysms include the short time-trapping, evacuation of the aneurysm either directly or through interventional radiography and reconstruction of the artery, either by a standard pterional ipsilateral approach and / or removal of anterior clinoid process, to facilitate proper exposure and evacuation of hematomas in ruptured cases. Intra-operative use of digital subtraction angiography, endoscopy and in the very recent past, use of Infrared Indo cyanine Green (ICG) Video Angiography has helped a great deal in assessment of intra-operative completeness of clipping. This is a revolutionary technology and helps in intra-operative proper visualization and closes the gap between speculation and reality, supplying vital information, enhancing efficacy since synchronous video recording of infra-red and white light is possible. The mechanism involved is that the blood, being seen as a white flow after ICG bolus on a dark background and the microscope switching from White light to infra-red light immediately. No extra instrumentation is required and can be repeated as and when required for

conformation of results. It is completely integrated on to the microscope.

Various difficulties in clipping due to either a narrow operative field, the wall thickness, partial thrombosis of sac, requirement for preservation of perforators, selection of clips and clipping techniques, along with reducing the ischemic time and evaluation of by-pass surgeries, can be overcome with expertise and experience. Partially thrombosed MC aneurysms require a thrombectomy and / or an aneurysmectomy along with end-to-end anastomosis with a great emphasis for preserving the perforators. The anatomy of the vasculature, the location of the aneurysm, the size, the shape, the direction, the branches of the main vessels, presence of perforators all determined the operative plan and strategy. Intentional neck reconstruction in Fuciform or multi-lobulated aneurysms with parent artery branching or perforators arising from base or dome, creating a smaller neck for complete occlusion by coiling, preserving parent artery patency to alter flow physiologically between inflow and outflow vessels and minimize risk of dissecting tight adherent zone between neck or wall and parent artery or perforators are important strategies in management.

The suction decompression of giant aneurysms followed by clip reconstruction of the parent vessel, thrombectomy in partially thrombosed aneurysms where suction was not effective and aneurysmectomy in strategically located aneurysms with a hard thrombus at the neck, are strategies in the management of giant aneurysms. Preservation of the patency of the parent vessel, perforators requiring dome-side clipping or drilling of the related bone like anterior clinoid, to get

full access and exposure with the use of proper lighting, instrumentation, endoscopy, intra operative angiography, intra operative Doppler and near infra-red indo cyanine green angiography and open surgeries are indicated in young patients with small aneurysms with no associated co-morbid medical disorders and those which are easily accessible or in patients with a bleb on the aneurysmal sac. Temporary trapping is always safe if less than 5 minutes, usually safe if around 10 minutes, probably safe if around 15 minutes and is of questionable safety if more than 20 minutes. Hypo thermia may be required, if it is required for more than 20 minutes.

Complications

Complications like re-bleed, increase in the ICP, ICH, IVH, hydrocephalus, vasospasm, seizures etc, must be adequately looked for and treated aggressively. Medical complications like anemia, hypertension, cardiac arrhythmias, fever, respiratory tract infection, urinary tract infection, enzyme abnormalities, electrolyte disturbances, pulmonary edema and atelectasis and pneumonia can cause very serious morbidity and mortality. Venous thromboembolism can occur in 2-4% of patients which can progress to pulmonary thrombo embolism and be fatal in up to 50% of these. Potential risk factors include lower limb trauma, varicosities, puerperal state, pregnancy, concomitant use of oral contraceptives, patients with prior infection, malignancy or antithrombin-III, protein C, protein S deficiencies. Low dose, low molecular weight, heparin may be started in patients with high risk, with proper monitoring of the coagulation profile. ECG abnormalities can occur in almost all patients with peak P waves, pathological Q

waves, increased QRS complexes and ST depression, with inverted T-waves and a prolonged QTc interval and / or large U waves. They must be differentiated from myocardial infarction. Patients can develop tachycardia, extrasystoles, couplets, SVT, bradycardia and arrhythmias.

Electrolyte balance must be adequately maintained, as patients with SAH are prone for hypo or hyper natremia and hypokalemia. They can even have hypovolemia. Patients can develop features of SIADH, cerebral salt wasting and diabetes insipidus. The differentiation between them can be made by the volume status. Acute change in body weight, change in hematocrit, BUN gives idea regarding changing volume status.

Treatment for salt wasting is adequate water and sodium replacement to keep it at normal levels and prevention of sodium loss by administration of fludrocortisone acetate. Fluid restriction is the main treatment for SIADH. DI can be treated by fluid replacement with hypotonic 5% dextrose or 0.45% saline. Desmopresin or DDAVP can be administered exogenously, with 1 - 2 microgram intranasal bolus doses. Patients can have weight loss, infection, impaired wound healing and may require gastrostomy or jejunostomy tube insertions apart from TPN. Stress ulcerations of the GI tract can occur and must be treated with H2 blockers, proton pump inhibitors or surcalfate.

Thick clot in the sub-arachnoid space, poor GCS on admission, age less than 35 and more than 65 years, with pre-existing hypertension and cigarette smoking, all predispose patients to severe vasospasm. The blood in the sub-arachnoid space can cause a structural proliferative vasculopathy of immune etiology and vascular

inflammation causing extra cellular wall contraction. It may be associated with vasoconstriction due to release of free radicals, lipid peroxidases, neurogenic factors, nitric oxide deficits, endothelin excess and deranged production of eicosanoids.

The oxy-hemoglobin is converted into free radicals which cause hydrolysis of phosphor lipids causing an increase in the calcium and calpine activation and protein degradation causing sustained vasoconstriction. Removal of sub-arachnoid blood during surgery, proper fluid management, maintenance of CPP more than 70 mmHg, hypervolemia, calcium channel blockers and off late, administration of tirilazad mesylate, can prevent vasospasm.

21 aminosteroids, anti-oxidants, lipid peroxidase inhibitors, help in prevention of ischemic damage. Intrathecal vasodilators and endothelin inhibitors to prevent vasospasm are in the experimental stage. Intra arterial papaverine, per cutaneous, transluminal, balloon angioplasty, intraventricular nitroprusside and hypervolemia hemodilution and hypertension are all tried for tackling vasospasm. An unexplained leucocytosis and fever can appear in almost all patients.

Prognosis and Outcome

The natural history of aneurysms is its outcome without medical or surgical intervention. The natural history of ruptured and unruptured anterior circulation aneurysms, are different. Unruptured aneurysms with no recent or remote SAH or symptoms related to bleed are diagnosed with screening tests, patients with familial origin and their management is very challenging and confronting to all

neurosurgeons. Rupture in previously undiagnosed aneurysms is a potential complication with 50 - 80% dying with SAH. Treatment is aimed at prevention of rupture, prolonging life, expectancy with consideration to the patient's age, sex, medical and family history. Treatment may be either surgical or endovascular with its own advantages and disadvantages.

Persons affected in the population at a specific time divided by the number of persons in the whole population at the given time, will give the prevalence of aneurysms, which are obtained by autopsy and radiological studies. 12% of patients die before coming into medical attention and in the surgical series, 25% of the patients who come to hospital die and about 50 - 60% recover in several large series. 40% of those patients reaching hospital die. Patients can have severe cognitive and higher cortical dysfunction, only due to SAH. The timing of admission to hospital, the risk of re-bleed, salvage after bleed and other criterion, already alluded, help in achieving a good outcome.

The types of patients, clipping of aneurysms before or after rupture, proper identification of the strategy in management determine the outcome. Results also depend upon the site, size and grade of the aneurysm, duration of bleed, direction of fundus, operative skill, experience and technical expertise, neurological status, timing of surgery, post-operative vasospasm, mass effect, brain stem compression, strokes, institution of Triple- H therapy, brain protection with Sendai Cocktail, pre-operative deficits, Fisher's Grade and severity of SAH. Hunt and Hess Scale, post-operative Glasgow outcome scale, pre-operative GCS and Japanese Coma Scale, requirement for re-

operation due to incomplete clipping of the aneurysmal lumen and requirement for additional procedures like clipping after coiling or coiling after clipping in a great way determines the overall outcome and results of the series. Complications of endo-vascular treatment include problems with re-canalization in 20%, intra procedural rupture in 2%, compaction of the coil in less than 20%, delayed rupture in 1.6% and arterial thromboembolism.

More often, complete coiling is achieved in only 70% of the aneurysms in expert hands and these may also reform and bleed. Heros shows a series of re-canalization in 2 to 37% of aneurysms, more often in large aneurysms. Clipping after coiling is a decision in residual or recurrent aneurysms, post embolization, decided upon by more than two expert neurosurgeons. Defective arterial wall is excluded to ensure anatomical continuity of normal wall. In GDC coils, early vasospasm may make the coil appear compact, but following resolution of spasm, re-canalization can occur and a partial thrombosed may lead to the formation of a rupture point, usually at the neck.

Further endovascular treatment with recent methods like improved coils, stents, balloon remodeling, must be considered before surgery and surgery must be reserved for patients not amenable for re-endovascular management, young patients, accessibility of the aneurysm and the size of the remnant being twice the size of the neck. The North American trial for unruptured and ruptured aneurysms (NATURE) may clear certain doubts and short comings. The cost constraint in endovascular treatment is compensated by saving in hospital stay, staff and earlier return to paid employment.

The size and location of the aneurysm determines morbidity and mortality which is 0% for aneurysms less than 7mm, 6% for aneurysms between 10 and 25 mm, 20% for aneurysms greater than 25 mm. Posteriorly, superiorly projecting aneurysms, clinoidal segment aneurysms and aneurysms in the cavernous ICA have high morbidity and mortality. The location of perforators from the wall of aneurysm, border of the neck or opposite side of the parent artery also determine prognosis. Risk of seizures is lower with coiling and re-bleed lower with clipping.

Recurrence thrombo-embolism, worsening mass effect in endo-vascular and calcified aneurysm, posteriorly projecting dome, high basilar bifurcation, high risk poor grade, have limitations in coiling. Small length of Acom, acute angle of adjacent vessels are difficult to coil. Wide neck, large aneurysms, geometrically complex with incorporated branch artery or perforator, Acom aneurysm, inability to navigate delivery system, partially thrombosed Fuciform or giant aneurysm, blister aneurysms or dissecting aneurysms are difficult to coil.

Conclusion

Team work and multi disciplinary approach is mandatory along with a goal of acquiring the best possible training and delivering the best possible treatment. Incompletely coiled aneurysm transforms a simple aneurysm into a lesion substantially more formidable. Advances in neuro genetics, intra arterial injection of TGFb - One adeno virus, clipping, coiling, new stents, by-pass treatment, combined treatment, fluorescence and / or near infra-red video angiography for intra-operative recognition of incomplete clipping, closes

the gap between speculation and reality and provides vital information, enhancing the efficacy of aneurysmal management. Bio-active coils cause progressive thrombosis and require further evaluation before recommendation.

Deeply situate aneurysms in elderly patients with co-morbid medical complications may require endo-vascular treatment. Minimally invasive surgery in big aneurysms is done to preserve the

natural flow. Artistic combination of endo vascular coiling, combined microsurgical clipping, revascularization for complex surgically incurable aneurysms is required with a favor towards reconstruction of the neck followed by coiling or clipping after an attempted incomplete coiling. Other novel strategies and nuances in the advancement of treatment need to be integrated in the near future.

This article was published first in "Essential Practice of Neurosurgery" 2009, a neurosurgical text-book accepted by the World Federation of Neurosurgical Societies – WFNS, as the official book for teaching neurosurgery. We thank the authors who allowed us to republish the material in this issue of Romanian Neurosurgery.