

## Book Review

### Intracranial Hypertension

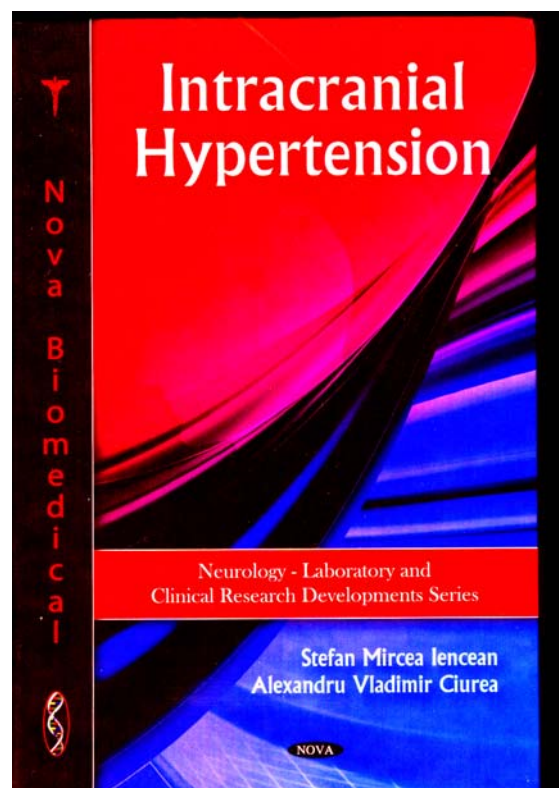
**St.M. Iencean and A.V. Ciurea**

Nova Science Publishers, New York, 2009;  
ISBN: 978-1-60741-862-7

The publication of a Romanian medical monograph in a prestigious American publishing house represents a medical publishing event and recognition of the value of Romanian medicine. The monograph entitled “Intracranial Hypertension”, written by the Romanian neurosurgeons dr. Stefan M. Iencean and prof AV Ciurea, was edited in late October 2009 by Nova Science Publishers, a publishing house in New York.

In the Romanian medical literature the known publications to date are the classic monograph entitled “Intracranial Hypertension” written by prof C Arseni and Al I Constantinescu in 1972, the chapter on intracranial hypertension from “Practical Handbook of Neurosurgery” written by prof Alex Constantinovici and AV Ciurea in 1998 and the paper entitled “Intracranial Hypertension” published by dr Stefan M. Iencean in 2006, based on a synthesis of scientific data, imaging investigations, biochemical investigations and modern electrophysiological investigations.

The monograph “Intracranial Hypertension” written by the two Romanian authors offers the updated knowledge accumulated to date in the field along with the major individual contributions of the authors.



The authors are two well-known Romanian neurosurgeons: dr St.M. Iencean (Iasi) and prof A.V. Ciurea (Bucuresti).

The paper covers the entire theme in 16 chapters, richly illustrated with drawings and original diagrams, all the selected imaging being significant for the clinical situations selected; the bibliography is ample and recent.

The merit of this monograph is that it offers the possibility of a complete and systematic understanding of intracranial hypertension, based on the experience and the important contributions of the two authors.

The monograph is classically structured: it begins with general considerations about intracranial hypertension, elements of anatomy and physiology and fundamental notions of intracranial hypertension, continuing with the pathology, clinical picture, laboratory explorations and the types of intracranial hypertension. The relationship between intracranial pressure and the mechanisms of increased intracranial pressure are thoroughly discussed and followed by a presentation of the current methods for measuring intracranial pressure. Pathogenesis of intracranial hypertension constitutes an important chapter of the monograph and it includes the modifications of the three intracranial components, which contribute separately or together to the development of intracranial hypertension: brain parenchyma, cerebro-spinal fluid and blood circulation.

The appearance of an additional intracranial mass induces mechanical effects of compression, displacements of brain substance and afterwards or at the same time biochemical changes emerge in the vascular wall, in glia and in neurons with the development of the brain edema. The changes in cerebrospinal fluid dynamics and in cerebral blood circulation represent a factor of major instability in the pathogenesis of increased intracranial pressure. The most serious

consequences of increased intracranial pressure are represented by the effects on the pressure infusion in the brain which causes cerebral ischemia and by the pressure differences between cranio-spinal compartments, producing brain herniation.

Presentations of the clinical picture and of decompressed disease symptoms follow, followed then by a chapter about paraclinic explorations which comprises the classic and modern investigations, by selecting the most characteristic imaging situations which present the intracranial hypertension syndrome.

The classification of intracranial hypertension highlights the authors' personal contributions, which have been published in professional journals in the country and abroad: intracranial parenchymatous hypertension, vascular intracranial hypertension, and intracranial hypertension by affecting the cerebro-spinal fluid dynamics idiopathic intracranial hypertension. The main characteristics of each syndrome and the elements of clinical and etiological differentiation related to age and clinical stage are discussed.

The last chapters deal at large with each type of disease, with the presentation of the specific pathology, of the clinical picture, of the paraclinic explorations and of specific treatment. An important subchapter is intracranial pressure monitoring, which permits the trace of intracranial pressure variations, the determination of brain infusion pressure and the assessment of therapeutic efficiency.

Intracranial parenchymatous hypertension is discussed in relation to the mode of onset: acute or gradual onset which constitutes an extremely useful approach for the clinician who must detect this pathology. Cranio-cerebral traumas represent a significant share of acute forms of disease and their discussion is elaborate, with the prominence of the last acquisitions in intracranial pressure monitoring and therapy. Vascular intracranial hypertension is discussed with the three main etiologies: cerebral thrombosis, hypertensive encephalopathy and ischemic cerebro-vascular disease with its diagnosis features, its evolution and treatment. Intracranial hypertension has two etiologic forms when a disorder of CSF dynamics occurs: through the disorders of CSF dynamics, having an obstructive internal hydrocephalus and through the disorders of CSF's resorption. Idiopathic intracranial hypertension is discussed extensively by presenting the possible pathogenic mechanisms whereof the authors had an original contribution.

The evolution and the prognosis of the disease and the treatment of intracranial hypertension are the last chapters related to this disease, with the presentation of therapeutic schemes in cerebral edema, in order to maintain the cerebral blood perfusion to normal values in terms of increased intracranial pressure and in

order to decrease the secretion and the excess of cerebro-spinal fluid. The principles of emergency treatment of intracranial hypertension syndrome and the treatment schedule of acute traumatic intracranial hypertension are also presented.

The last chapter discusses the intracranial hypotension syndrome, which often may have a clinical picture similar to that of intracranial hypertension and which requires recognizing and applying an adequate treatment.

The recognition of the Romanian authors' contribution in classifying some aspects of this pathology which is essential in neurosurgery and neurology was also confirmed by them being chosen to develop the "Intracranial Hypertension" chapter in the international guide "Essential Practice of Neurosurgery" addressed to young neurosurgeons and edited by the World Federation of Neurosurgical Societies.

The monograph published by dr. St M Iencean and prof AV Ciurea is a success in the international medical literature and it reaffirms the value of the Romanian school of neurosurgery, being a reference book of intracranial hypertension.

Prof. Dr. Alexandru Constantinovici  
UMF „Carol Davila” București  
Honorary President of the Romanian  
Society of Neurosurgery