

Medial Temporal Arterio-Venous Malformation Case Report

I.St. Florian^{1,2}, C. Abrudan¹, C. Matei²

¹University of Medicine and Pharmacy “Iuliu Hatieganu “ Cluj- Napoca, Romania, Neurosurgical Department

²Cluj County Clinical Emergency Hospital, Neurosurgical Department

Abstract

We introduce an uncommon case of small arterio-venous malformation (AVM) on a critical location. A young woman with left anterior medial temporal AVM was referred to our department in comatose state. We decided to treat this case by open surgery. Secondary hydrocephalus occurred and a ventriculo-peritoneal shunt was inserted. The postoperative course was with no complications, and the patient was discharged in good state and six months later she resumed her activity. The case is of interest in the light of the decision-making process, and the techniques and surgical skills for the surgery of arterio-venous malformations on this critical location.

Keywords: Arterio-Venous malformations, intraventricular hemorrhage, temporal lobe, microsurgery

Introduction

The surgical treatment of large or critically located arterio-venous malformations (AVMs) of the brain tests the technical skills of even the most accomplished neurosurgeons. Medial temporal AVMs constitute a special group. AVMs of the medial temporal lobe frequently involve the basal ganglia and the thalamus, and for this reason they are commonly judged to be inoperable [4]. Medial temporal AVMs are anterior, midtemporal and posterior or paratrigenal [1,2,3]. Anterior lesions are supplied from the anterior choroidal branches, the anterior temporal branches of the middle and posterior cerebral arteries and

branches of the posterior communicating artery. Venous drainage is usually into the basal vein of Rosenthal, but there might be outflow into the sphenoparietal sinus, medial sylvian vein or the vein of Labbé [4]. In patients who present with intracranial hemorrhage from an AVM, the risk of recurrent hemorrhage and progressive neurologic deficit would argue strongly in favor of surgical intervention in most of the cases.

We present a case of medial temporal AVM treated by open surgery, through pterional approach.

Case report

A previously healthy, 22-year-old woman experienced a sudden onset of headache, nausea and vomiting, in the morning of October 15th 2006 at three o'clock, during sleep. At seven o'clock the attack reoccurred and she lost consciousness. She was admitted in our department on the same day with comatose state, having GCS (Glasgow Coma Scale) 8, right hemiparesis, left oculomotor complete palsy (strabismus, midriasis, ptosis) and meningism.

The admission CT scan showed diffuse subarachnoid, and a more important intraventricular hemorrhage, in the left lateral ventricle, with a left medial temporal lobe hematoma. An underlying small (< 3 cm) AVM was seen on MRI angiography and left carotid angiogram (Figure 1). Its feeding arteries were posterior communicating artery, choroidal artery and posterior cerebral artery. Venous drainage was into the vein of Rosenthal.

In the 3rd day after admission she was taken into the operating room. A standard neuroanesthesia induction with pentobarbital, fentanyl and muscle relaxant was used. Anesthesia was maintained with nitrous oxide, isoflurane and narcotic. Standard physiologic monitoring was performed during surgery. Spinal drainage was instituted and mannitol administered before surgery. The patient was positioned supine with the neck extended and the head turned 30 degrees to the right. The AVM was approached via left pterional craniotomy with microsurgical splitting of the anterior part of the sylvian fissure

(Figure 2). The whole malformation was resected using microsurgery principles. Due to prior intraventricular hemorrhage, we left in place an external ventricular drainage for five days, when CT-scan follow up revealed the resolution of the intraventricular hemorrhage and no hydrocephalus (Figure 3). The postoperative course was uneventful with regained consciousness and the CT-scan follow up showed complete resection of the AVM, and no others lesions. The patient was discharged in very good condition: she was alert, with no neurological deficits except the left oculomotor palsy which has been partly solved, and mild memory disturbances.

6 weeks later the patient experienced a cognitive decline, her memory disturbances worsened, impairment of affection and gait disturbances. A CT-scan examination was obtained which revealed communicating hydrocephalus. She was readmitted in our department, and underwent surgery for a ventriculo-peritoneal drainage. The postoperative course was with no complications and she was discharged with general and neurological status improved. At 6 months follow-up the patient was in a good state presenting a mild degree of ptosis on the left eye, and she resumed her activity, poetry.

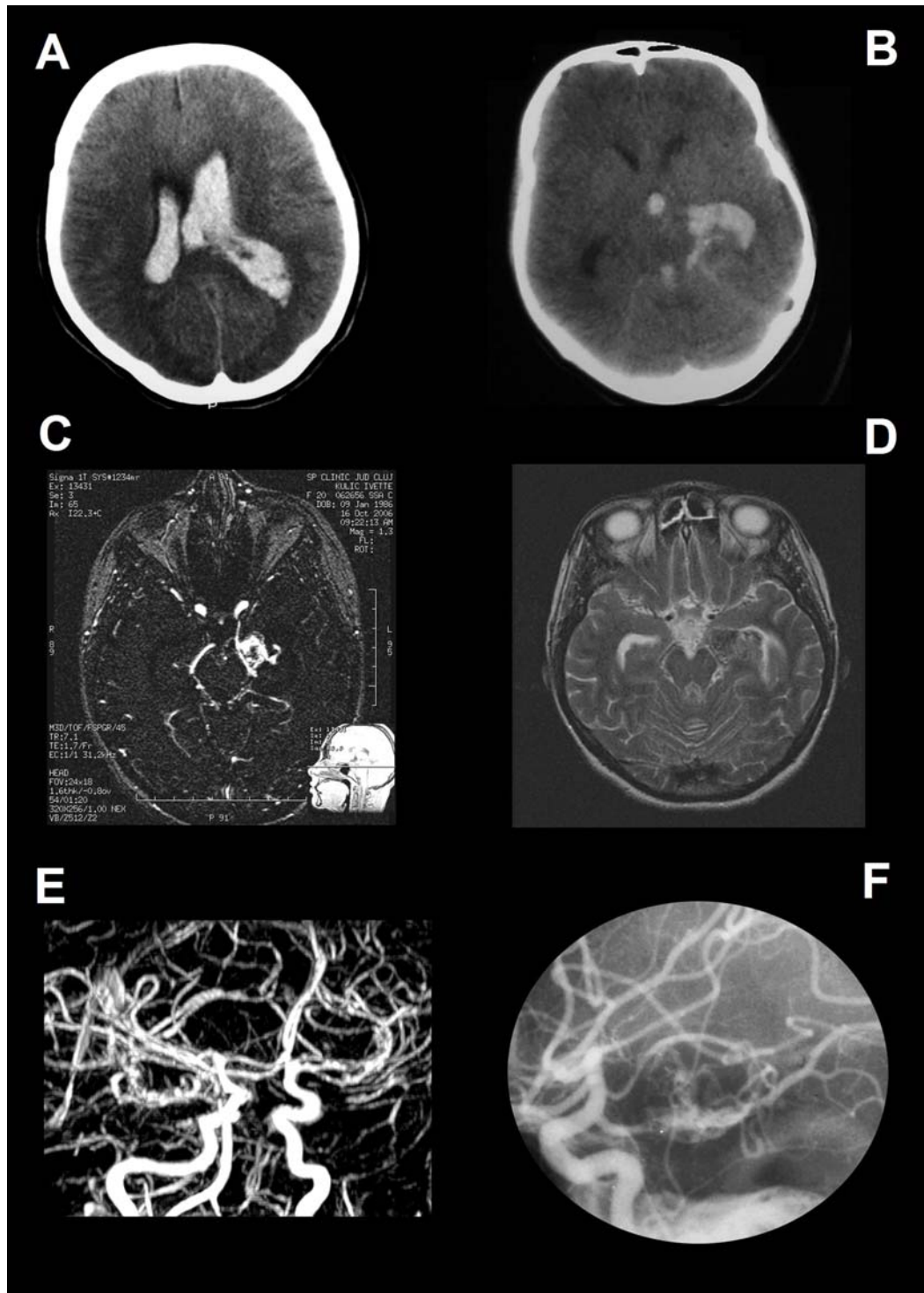


Figure 1 Preoperative imaging study: A, B, preoperative CT-scan which revealed left medial temporal haematoma, intraventricular and subarchnoid hemorrhage; C, D, MRI study and E, angiography MRI, and F, right carotid angiography with small AVM, supplied from posterior communicating artery, choroidal artery and posterior cerebral artery

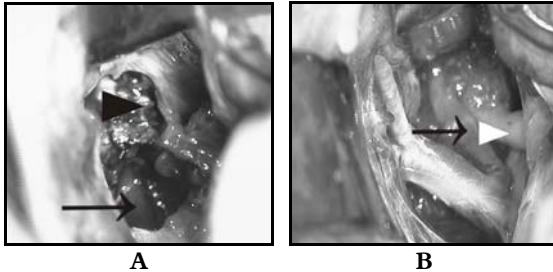


Figure 2 Intraoperative aspects, A, The posterior communicating artery (PCoA) serves as a useful guide towards the malformation, black arrow head AVM, arrow PCoA, B, the AVM is totally resected, white head arrow oculomotor nerve and arrow PCoA

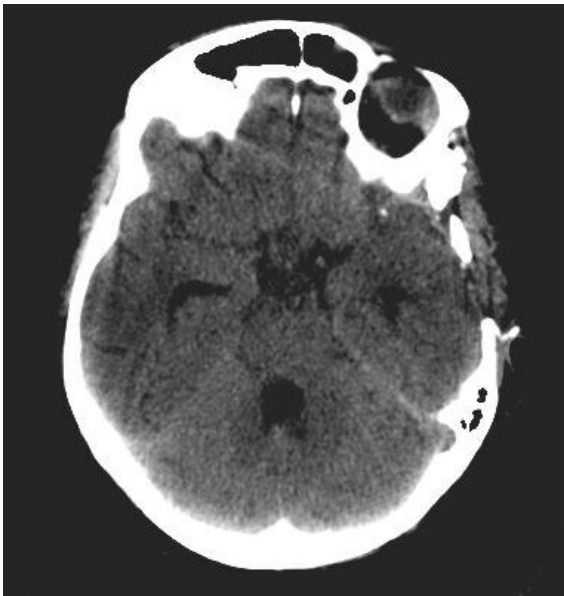


Figure 3 CT scan 3 days follow up revealed the resolution of hemorrhage and no hydrocephalus

Discussion

Cerebral arterio-venous malformations are one of the most difficult challenges for neurosurgeons either from the decision-making process or the techniques and surgical skills for this surgery.

Medial temporal AVM are a special group in the medial hemispheric AVM. In one series of 300 surgically treated AVMs

of the brain, 55 lesions were located in the medial aspect of the hemisphere and seven lesions were located in the anterior medial temporal lobe [3].

The natural history of these lesions is not fully known yet. Moreover, available evidences indicate that patients with AVM, who are left untreated frequently, die prematurely or are left incapacitated. These may occur, because the main presentation of an AVM is with rupture and hemorrhage. The risk of hemorrhage is 4% per year, and the annual mortality rate is 1% [4]. This dismal prognosis encourages the surgery approach of these lesions.

Anterior medial temporal AVMs are supplied from the anterior choroidal arteries, the anterior temporal branches of the middle, and posterior cerebral arteries and branches of the posterior communicating artery. Venous drainage is usually into the basal vein of Rosenthal, but there might outflow into the sphenoparietal sinus, medial sylvian vein or the vein of Labbé.

Treatment planning for AVMs depends on the risk of subsequent hemorrhage, which is related to prior hemorrhage, smaller AVM size, deep venous drainage, and relatively high arterial feeding pressures [2]. All of these were present in our case. We had a comatose young patient with ruptured small medial temporal AVM with intraparenchymatous temporal haematoma and deep venous drainage, so we decided to treat this case by open surgery. Emergent intracerebral haematoma evacuation can be performed

with or without AVM resection. We are advocates of an early surgery, and based on accurate preoperative planning we decided to resect the malformation at the same time. There are surgeons, who suggest that it is preferable to wait several weeks for the associated edema to reduce, for the haematoma to liquefy, and for the brain to regain the autoregulation, because the risk of rebleeding during this time is low [4]. Also, the repeated angiography, after a few weeks, showed a new configuration of the AVM, which was altered by the haematoma and hypertension.

Regarding the size of critical located malformations, stereotactic radiosurgery, microsurgical resection or embolization (if multiple hemorrhages) are the options for small (< 3 cm diameter) arterio-venous malformations [4,5]. Radiation therapy does not represent a first line approach of the AVMs, especially of the ruptured ones [3, 5]. Malformations that are located on the medial aspects of hemispheres are generally not suitable for preoperative embolization therapy. These malformations are supplied by distal branches of the choroidal arteries, posterior communicating arteries, which have a small intraluminal diameter and arise from the parent vessel at right angle. These factors make embolization hazardous and therefore it is not usually indicated for malformations in this location [3].

Surgical resection is the mainstay of definitive treatment and it is the most effective in order to prevent rebleeding. Arterio-venous malformations of the medial temporal lobe are usually resected

through subtemporal-transcortical approaches that provide a trajectory that is perpendicular to the plane of the AVM [1]. The pterional approach and orbitozygomatic approach are also recommended for these lesions. Based on our experience we performed the resection of AVM via pterional approach with microsurgical splitting of the anterior part of the sylvian fissure. This approach allows the visualization of the supraclinoid carotid artery and its branches that lead back to the malformation on the medial side of the temporal lobe [3]. The anterior choroidal artery or posterior communicating artery serves as a useful guide back into choroidal fissure and to the substance of the malformation. Malformations in this location involve the uncus and the amygdala as well as portions of the anterior hippocampal formation. These regions are amenable to resection when involved by the AVM. Arterio-venous malformations of the medial temporal lobe which involve the basal ganglia and the thalamus are commonly judged to be inoperable.

In order to prevent hydrocephalus due to the presence of ventricular and subarchnoid hemorrhage, we operated with spinal drainage, and after surgery we left in place an external ventricular drainage for five days, when CT-scan follow up revealed a normal postoperative aspect. Despite all, after six weeks the patient developed a communicating hydrocephalus, which was treated by ventriculo-peritoneal drainage.

Subarachnoid and intraventricular hemorrhages favor the development of

hydrocephalus, which may occur in 10-15% of patients. This is caused by the scarring of the arachnoid granulations and alterations in CSF [2]. Typically, late hydrocephalus is a communicating type and develops 10 or more days after subarachnoid hemorrhage, and the treatment is ventriculoperitoneal shunt.

Conclusions

Cerebral arterio-venous malformations are one of the challenges for neurosurgeons either from the decision-making process or the techniques and surgical skills for this surgery.

Medial temporal AVM are a special group in the medial hemispheric AVM.

The advantages of surgery are the immediate elimination of the hemorrhage and of the risk for rebleeding, and the improvement in seizure control if the AVM itself is generating seizures.

In our experience pterional approach represents the best way in order to treat

these lesions because allows the visualization of the supraclinoid carotid artery, and its branches that lead back to the malformation on the medial side of the temporal lobe and permits the resection of the uncus and the amygdala as well as portions of the anterior hippocampal formation, when necessary.

References

1. Du Rose, Young WL, Lawton MT, Yasargil MG, Abdulrauf SI, Gonzalez LF, Spetzler RF) Tangential resection of medial temporal lobe arteriovenous malformations with the orbitozygomatic approach *Neurosurgery* 54(3): 645-652, 2004
2. Heros RC Arteriovenous malformations of the medial temporal lobe. Surgical approach and neuroradiological characterization *J Neurosurg* 56(1): 44-52 1982
3. Solomon RA, Stein MB in Wilkins RH and Rengachary SS *Neurosurgery* 2nd Ed. McGraw-Hill Professional Publishing 241: 2448-2454 1995
4. Steinberg GK, Stoodley MA in Schmidek and Sweet *Operative Neurosurgical Techniques* 4th Ed. W.B. Saunders Company 100: 1363-1391 2000
5. Steinberg GK, Fankant JL, Marks MP stereotactic heavy-charged particle Bragg peak radiation for intracranial arteriovenous malformations *N Engl J Med* 323: 345-353 1990