

## Decompressive Craniectomy – from option to standard – Part II

C. Balan<sup>1</sup>, B. Alliez<sup>2</sup>

<sup>1</sup>Neurosurgery, Emergency Hospital “Prof. Dr. N. Oblu” Iasi, Romania

<sup>2</sup>Hopital Nord, CHU Marseille, France

### Abstract

The paper intends an update to the theoretical and practical data on a seldom utilized technique but often considered as last therapeutically option, so the necessity to realize it correctly. In this second part are presented the indications of the technique for each type of pathology, together with the results and latest guideline indications.

**Keywords:** decompressive craniectomy, indications

### Indications

There is actually just one class I indication for decompressive craniectomy - malignant sylvian stroke in people less than 60 old [1], and still there are controversies. Most studies involving decompressive craniectomy are retrospective and the few prospective ones were realized on patients with refractory raised intracranial pressure as salvage therapy – last option available. There are also several suggestions of using profilactic decompressive craniectomies whenever exists a high risk of evolution towards a refractory raised intracranial pressure or when the neurosurgeon's experience suggests this – like acute subdurals hematomas associated with large contusion, subarachnoid hemorrhage or severe meningitis[2,3].

The purpose of this paper is not to argue in favor or not the extending of decompressive craniectomy in different pathologies but to present the authors experience together with a review of the literature, as the second author was one of

the first who pleaded for the importance of knowing the technique and its limitations [4] after 1999, when Guerra re-introduced decompressive craniectomy after several decades of oblivion.

**Traumatic pathology** - decompressive craniectomy has been applied in patients with traumatic brain injury for several years but only within the past 10 years, the modern era of neurointensive care, there have been observational studies. The primary indication for decompressive craniectomy is persistent raised intracranial pressure, which cannot be controlled by other therapeutic measures (hyperventilation, deep sedation, diuretics or CSF withdrawal). After several minutes (and sometimes hours) of raised ICP over 22-25 mm Hg, especially on a contused brain and when medical therapy proved ineffective, a decompressive craniectomy can be tempted.

From Wurzburg [5] who reported a favorable outcome rate of 56% and a mortality rate of 11%, with later de

compressions averaging 68 hours postinjury in 28 patients and have been Guerra [6] who reported a favorable outcome rate of 58% and mortality rate of 19% to noawadays there are over 100 papers on decompressive craniectomy in traumatic refractory raised intracranial pressure.

We distinguish two types of decompressive craniectomies realized for traumatic brain injuries : early decompression, realized when operating in emergency an acute subdural hematoma, with subjacent contusions and when the brain swelling prevents the reposition of the bone flap; late decompression, in patients without surgical masses, usually at 3-7 days after trauma, when ICP raises and becomes refractory to other medical treatments.

On a serie presented by the first author[10], during 5 years, among 937 patients with severe brain injury (GCS < 7), 44 decompressive craniectomies were realized, among which:

- 27 early decompressive craniectomies for acute subdural hematomas or contusions when CT scan suggested a possible consecutive aggravation

- 17 late decompressive craniectomies, for refractory ICP, higher than 30 mm Hg for 30 minutes

The results in term of GOS at one year are presented in Tabel 1.

The high level of deaths among early decompressive craniectomies is explained by the important concomitant brain lesions. The main complications on the whole lot were wound dehiscence or infection (19 cases), ventilated associated pneumonia (18 cases), brain abscesses or empyema (6 cases).

The high level of good outcomes (GOS 4-5) for patients operated late is due to the fact that these late decompressive craniectomies were realized in already stabilized patients, who presented a top in their ICP, refractory to medication – this raised ICP treated, no more problems were encountered and early cranioplasty was realized.

Below are the images of one of our cases : Figure 1a in Day 1, GCS=9; Figure 1b in Day 2, secondary aggravation, GCS= 5, ICP over 50 mm Hg; Figure 1c in Day 17, GCS=12; Figure 1d in Day 104, after cranioplasty with autologous bone.

**Tabel 1**

	Early decompression	Late decompression
GOS 1 – death	14 (51%)	5 (29%)
GOS 2-3	8 (30%)	5 (29%)
GOS 4-5	5 (18%)	7 (41%)
TOTAL	27	17

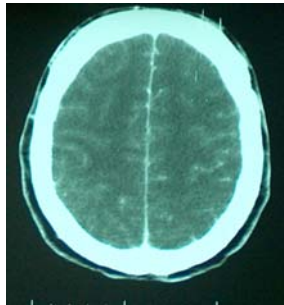


Figure 1 A

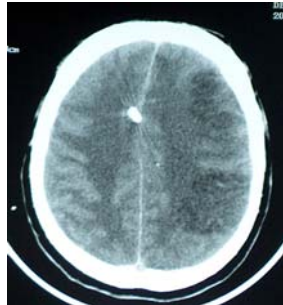

Figure 1 B

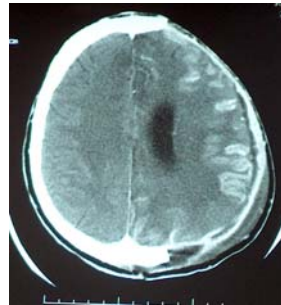


Figure 1 C

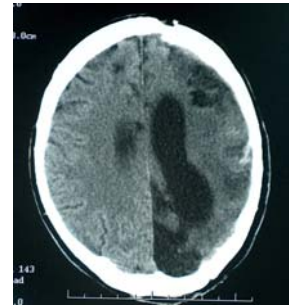


Figure 1 D

Guidelines and data from the literature:

- Guidelines for management of brain injury – 2006 [7] – there is no statistically significant difference between acute subdural hematomas operated with craniotomy with reposition of the bone flap or decompressive craniectomy, reason why further studies are recommended. However, the authors admit that in several papers, patients operated with simple craniotomy were in better neurological status than those operated with decompressive craniectomy.

- Guidelines for management of brain injury of the American Brain Trauma Foundation (2007)[8] – for intraparenchymal traumatic lesions, the decompressive techniques (decompressive craniectomy, temporal lobectomy) are considered as option whenever exists refractory raised intracranial pressure and radiological signs (CT scan) of cerebral herniation. Bifrontal decompressive craniectomy is an option whenever exists diffuse lesions and refractory raised intracranial pressure but no herniation on CT scan if surgery is performed in the first 48 hours. The conclusion is that literature data suggest but not prove that decompressive

procedures represent the best available option.

- Guidelines for management of brain injury of the American Brain Trauma Foundation (2007) for Pediatric patients[8] – there are evident data that decompressive craniectomy in children with refractory intracranial pressure leads to better neurological outcome, shorter hospitalization in ICU, better ICP control. The results were obtained from randomized studies, however due to small cohorts of patients the data are not statistically significant.

- In Europe, the Cochrane DATABASE of systematic reviews in 2006 [9] has concluded that there is no evidence to support the routine use of decompressive craniectomy to reduce unfavorable outcomes in adults with severe traumatic brain injury and medically refractory elevated ICP.

The literature demonstrates a wide range of clinical outcomes, with no clear consensus regarding the indications for surgery. Some of the indications mentioned are ICP above 25-30 mm Hg in adults and 24 mm Hg in children for more than 30 minutes, refractory to medical treatment; cerebral perfusion pressure below 60 mm Hg, age below 50, midline shift over 1 cm whenever there is

no intracranial mass and even the opinion of the neurosurgeon on call. Are excluded patients with GCS 3 or bilateral mydriasis.

There are actually two independent multicenter double blind randomized studies in going on the utilizing of decompressive craniectomy for TBI :

- The RESCUEicp is a multicenter European randomized trial in which decompressive craniectomy is compared with medical management coordinated by the University of Cambridge, UK, and the European Brain Injury Consortium. Patients (600 cases for the main study) with TBI and elevated ICP ( $> 25$  mm Hg) refractory to initial treatment measures are eligible for the study. Patients are randomized to one of two arms: continuation of optimal medical management (including barbiturates) and surgery (decompressive craniectomy). Outcome is assessed using the extended GOS and 36-Item Short Form Health Survey at 6 months posttreatment, with additional surrogate end points (ICP control and duration of stay in the intensive therapy unit). The pilot phase of the study (50 cases) has been completed in 2007 and has demonstrated that randomizing patients with TBI to decompressive craniectomy as opposed to optimal medical management is feasible. Whether this operation is effective and safe remains to be seen.

- The DECRA study, coordinated by the University of Melbourne, has enrolled 153 patients from Australia and New Zealand till October 2009. Refractory ICP in this study was defined as the spontaneous persistent increase in

ICP despite optimal conventional ICU therapies (including intermittent EVD venting) of  $>20$ mm Hg for more than 15 mins (continuously or cumulative over one hour). Patients were randomised to one of two groups: the first group will receive best current management together with an early decompressive craniectomy operation. The second group will receive best conventional therapy alone (which does not include the early DC operation). The study was expected to end at 165 patients in December 2009, patients being evaluated by GOSE at 6 months.

Ischemic stroke – according to European Stroke Organization (2008) and accepted by the Romanian Society of Neurology in 2009, decompressive craniectomy is considered as guideline class I A in the treatment of malignant sylvian stroke.

The main paper in literature to support this opinion was published by Vahedi [1] and resumes the results of three european independent multicenter trials from France, Germany and The Netherlands. Because of their similar design and outcome measures, the steering committees planned a pooled analysis of the data from these trials while they were still ongoing to increase the chances of obtaining sufficient data and to minimize the number of patients involved in individual trials. This pooled analysis included 93 patients younger than 55 to 60 years who underwent decompressive craniectomy within 48 hours from the onset of stroke. The primary outcome measure for the pooled analysis was the proportion of patients with an mRS score of 4 or lower in the surgical and medical

treatment groups at 1 year posttherapy. Survival and an mRS score of 3 or lower were secondary end points. The results have suggested that significantly more patients in the surgical group than in the control group had an mRS score of 4 or lower (75% compared with 24%; pooled absolute risk reduction 51%, 95% CI 34-69), an mRS score  $\leq 3$  (43% compared with 21%; pooled absolute risk reduction 23%, 95% CI 5-41), and survived (78% compared with 29%; pooled absolute risk reduction 50%, 95% CI 33-67). This effect was highly consistent across the three trials and did not change on adjustment for baseline differences. This study represents the best evidence available to date (and possibly ever) on the role of surgical decompression in malignant brain swelling associated with extensive cerebral infarction.

However, despite the good results, the data cannot be translated automatically into the widespread use of decompressive surgery in all eligible patients: first, because the findings of an improved outcome cannot be extrapolated to older patients and those who undergo surgery within the first 48 hours after the onset of stroke; and second, although surgery doubles the number of patients who require minor support (mRS score  $\leq 3$ ), it increases 10-fold the number of patients with a moderately severe disability (mRS score  $\leq 4$ ) that requires almost continuous assistance. This fact must be carefully considered and discussed with the next of kin in each individual case before proceeding to surgery. Moreover, the number of ischemic sylvian strokes in patients under

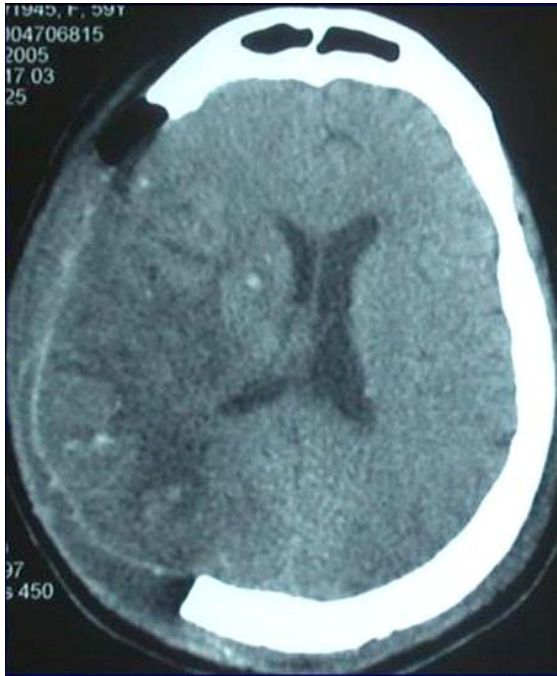
60 years old represents only 3.5-5 % of all ischemic strokes.

As criteria to decompress, the study considered patients under 60 years old, with clinical signs of MCA stroke, radiological signs of malignant stroke (CT scan  $>50\%$  ACM territory or/and MRI territory  $> 145 \text{ cm}^3$ ) in the first 48 hours from the onset of the stroke. Patients having any of: MCA stroke before with mRS 2 or worse, contralateral infarction, hemorrhagic transition of stroke, comorbidity influencing outcome, disturbances of blood coagulation were excluded.

From personal cases: Figure 2a with a MCA stroke and midline shift over 1.5 cm., GCS = 6; Figure 2b, the same patient after decompressive craniectomy, no more shift, GCS = 9, still hemiplegic.

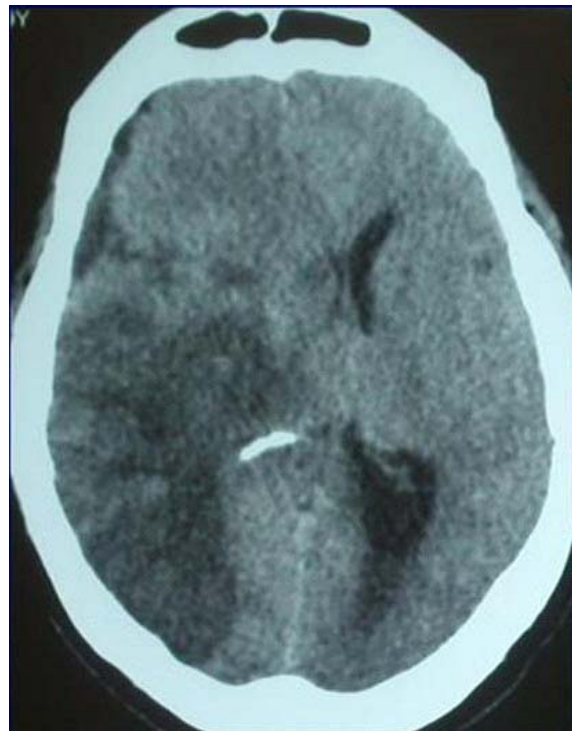

Figure 2 A



**Figure 2 B**

Subarachnoid hemorrhage - in contrast to traumatic brain injuries, there are substantially fewer published studies on the experience of decompressive craniectomy as a treatment for brain edema following SAH. It is already known for more than 15 years that a brain with SAH tolerates lower ICP level than a normal one and that a pressure of 18-20 mm Hg is considered raised after an episode of SAH [13]. Smith et al. [14] proved that even a limited craniectomy, realized by removal of the bone flap, considering that the bone flap for pterional craniectomy is far smaller than the decompressive one for trauma, can lower significantly the ICP after clipping an aneurysm.

Several other studies were realized, among the newest: Schirmer [15] described the results of decompressive craniectomy in the treatment of refractory

elevated ICP in 16 patients with aneurysmal SAH, half treated with endovascular coil embolization and the other half with surgical clip application. Sixty-nine percent of patients survived, and at the follow-up (median 450 days) 64% of them had an mRS score of 0 to 3 and 36% a score of 4 to 5. Early craniectomy performed within 48 hours after SAH was associated with a better outcome. Buschmann and colleagues [16] have reported the results of 38 patients following decompressive hemicraniectomy after early aneurysm clipping. The pooled data from all 38 patients showed a favorable outcome (GOS Scores 4 and 5) in 53% of patients, severe disability in 26% (GOS Score 3), and death in 21%. After 12 months, a good functional outcome was seen in 52% of the cases in Group 1, in 60% in Group 2, in 83% in Group 3, and in 17% in Group 4.

These authors concluded that decompressive craniectomy is a useful adjunctive modality in the management of refractory intracranial hypertension in patients with poor-grade aneurysmal SAH, even in the absence of extensive intraparenchymal hemorrhage. In more than half of the patients with intractable intracranial hypertension after aneurysmal SAH, a good functional outcome could be achieved after decompressive craniectomy. Patients with progressive brain edema but no radiological signs of infarction and those with hematoma may benefit the most; and that the indication for decompressive craniectomy should be set restrictively if secondary infarction is present.

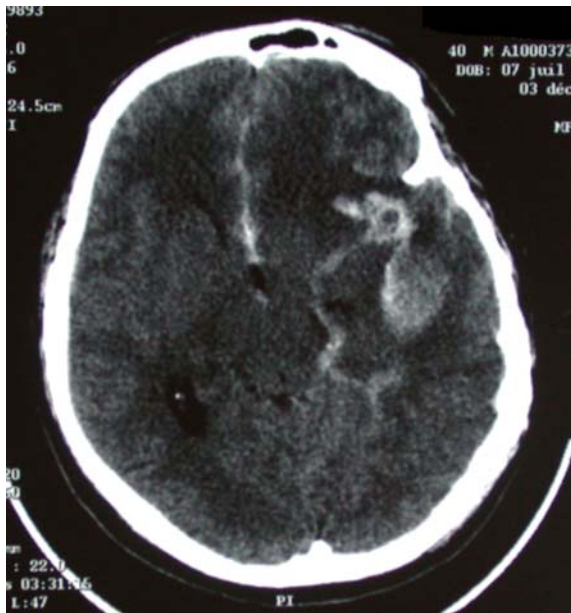


Figure 3 A

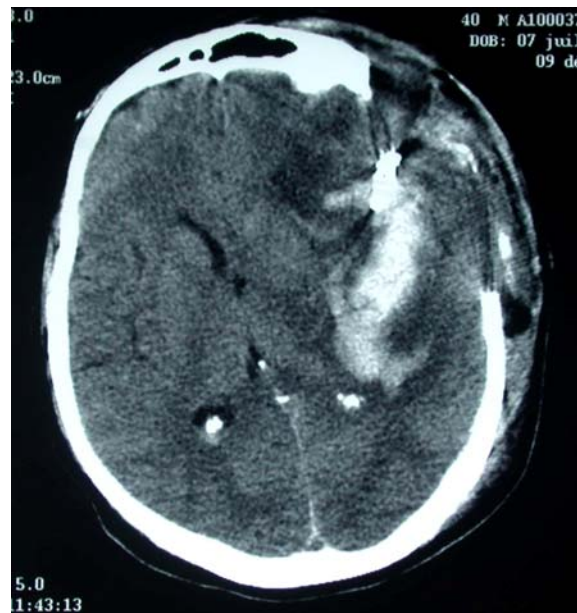


Figure 3 C

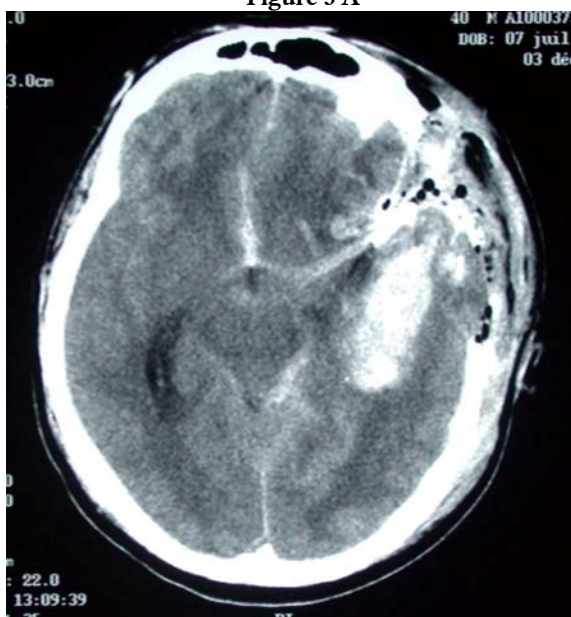


Figure 3 B

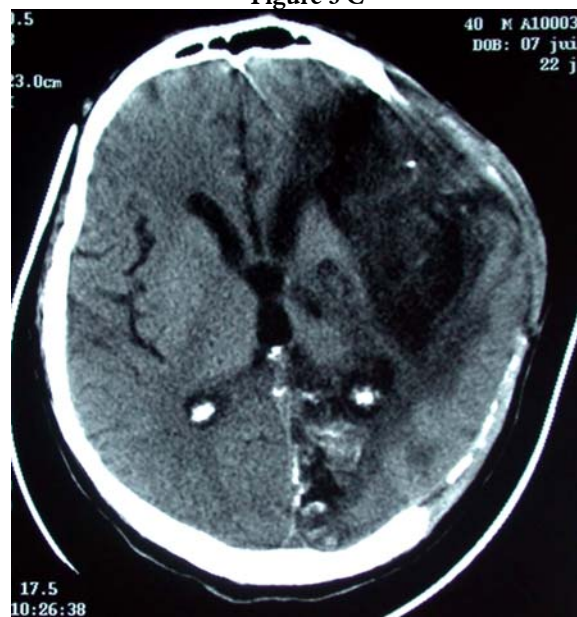

Figure 3 D

Figure 3 A SAH with sylvian hematoma, MCA aneurysm in day 1.

Figure 3 B after surgery, day 2, removal of the bone flap due to edema

Figure 3 C midline shift, brain herniation in day 6 when a real decompression was realized

Figure 3 D day 17 after SAH, important brain herniation but without midline shift

Other indications - decompressive craniectomy has also been applied occasionally in the treatment of brain hemorrhage or predominantly in single cases or small case series of meningitis, acute encephalitis, subdural empyema and cerebral venous and dural sinus thrombosis [17].

## Conclusions

Decompressive craniectomy as a surgical treatment for brain edema has been performed for many years and for several different pathophysiologies, including TBI, SAH, and ischemic stroke. The medical literature contains a wealth of information on decompressive craniectomy, especially observational series from individual centers. The role of this procedure remains unclear, however and randomized studies are expected to provide Class I evidence in treating patients with refractory intracranial hypertension and brain edema.

## References

1. Vahedi K, Hofmeijer J, Juettler E, et al (2007) - Early decompressive surgery in malignant infarction of the middle cerebral artery: a pooled analysis of three randomised controlled trials. *Lancet Neurology* 6 (3): 215-22
2. Skoglund, TS; Eriksson-Ritzen C, Jensen C, Rydenhag B (2006) - Aspects on decompressive craniectomy in patients with traumatic head injuries. *Journal of Neurotrauma* 23 (10): 1502-1059.
3. Schneider, GH; Bardt T, Lanksch WR, Unterberg A (2002). - Decompressive craniectomy following traumatic brain injury: ICP, CPP and neurological outcome. *Acta Neurochirurgica (Supplement)* 81: 77-79
4. Albanese J, Leone M, Alliez JR, Alliez B, et al(2003): Decompressive craniectomy for severe traumatic brain injury: evaluation of the effects at one year. *Crit Care Med* 31: 2535-2538
5. Kunze E, Meixensberger J, Janka M. et al (1998): Decompressive craniectomy in patients with uncontrollable intracranial hypertension. *Acta Neurochir Suppl* 71:16-18, 1998
6. Guerra WK, Gaab MR, Dietz H. et al: Surgical decompression for traumatic brain swelling: indications and results. *J Neurosurg* 90:187-196, 1999
7. Bullock, Ross.; Chesnut, Randall.; Ghajar, Jamshid et al – Surgical management of Acute subdural hematomas – *Neurosurgery Suppl*, vol 58, issue 3, March 2006
8. [www.braintrauma.org](http://www.braintrauma.org)
9. Sahuquillo J, Arikian F - Decompressive craniectomy for the treatment of refractory high intracranial pressure in traumatic brain injury. *Cochrane Database Syst Rev*: CD003983, 2006
10. Balan C, Alliez JR, Albanese J et al – Decompressive craniectomy for severe traumatic brain lesions – results at one year in Proceedings of the 13th World Congress of Neurological Surgery, Medimond, 2005
11. [www.rescueicp.com](http://www.rescueicp.com)
12. [www.decra.org.au/](http://www.decra.org.au/)
13. Fisher CM, Ojemann RG. - Bilateral decompressive craniectomy for worsening coma in acute subarachnoid hemorrhage: observations in support of the procedure. *Surg Neurol.* 1994;41:65–74
14. Smith E, Carter B - Proposed use of DC in poor grade SAH patients with large sylvian hematomas, *Neurosurgery* July 2002
15. Schirmer CM, Hoit DA, Malek AM - Decompressive hemicraniectomy for the treatment of intractable intracranial hypertension after aneurysmal subarachnoid hemorrhage. *Stroke* 38: 987-992, 2007
16. Buschmann U, Yonekawa Y, Fortunati M, - Decompressive hemicraniectomy in patients with subarachnoid hemorrhage and intractable intracranial hypertension. *Acta Neurochir (Wien)* 149:59-65, 2007
17. Hutchinson P, Timofeev I., Kirkpatrick P.- Surgery for brain edema, *Neurosurg. Focus*, vol. 22, May 2007