

## **Endoscopic Endonasal Transsphenoidal Approach in the Management of Sellar and Parasellar Lesions: Indications and Standard Surgical Technique (Part I)**

**Ligia Tataranu<sup>1</sup>, M.R. Gorgan<sup>1</sup>, V. Ciubotaru<sup>1</sup>, Adriana Dediu<sup>1</sup>, B. Ene<sup>1</sup>, D. Paunescu<sup>1</sup>, Anica Dricu<sup>2</sup>, V. Pruna<sup>1</sup>**

<sup>1</sup>Neurosurgical Clinic, "Bagdasar-Arseni" Clinical Emergency Hospital, Bucharest, Romania; <sup>2</sup>University of Medicine and Pharmacy, Craiova, Romania

### **Abstract**

Transsphenoidal approaches have been used for a century for the resection of pituitary and other sellar tumors. In the past decade, however, the endoscopic endonasal transsphenoidal approach has been proposed as a minimally invasive procedure for the treatment of pathologies of the sellar region. This procedure introduces various advantages compared with the transsphenoidal microsurgical approach, such as an improved vision of the surgical field, less traumatism of the nasal structures and reduced complications. Patients' quick recovery, short hospital stays and minimal postoperative discomfort have been observed. More recently, the standard endoscopic endonasal technique has been extended to provide access to parasellar lesions. This expansion carries significant potential for the resection of skull base lesions. In this article, the authors review the indications of the endoscopic endonasal transsphenoidal approach and define the main phases of the standard surgical technique. Preoperative evaluation, equipment, preoperative and postoperative care are presented. Endoscopic endonasal technique is a safe and effective method for removal of most sellar and some parasellar masses, providing more complete lesion excision and reducing complications.

**Keywords:** endoscopy, minimally invasive surgery, parasellar lesion, pituitary tumor, sellar lesion, transsphenoidal surgery

Endoscopes have two advantages relative to operating microscopes: they provide a wide panoramic view of the surgical field through a narrow corridor as well as images of the surrounding anatomy, including various anatomical corners. Endoscopes can be used to assist visualization during conventional microscopic surgery (endoscope-assisted microsurgery), to place an endonasal retractor during microsurgery (endoscopic sphenoidotomy) or as a sole visualizing tool during endoscopic endonasal transsphenoidal approach [1].

When the endoscope is used in transsphenoidal surgery, Jho and Alfieri (2000) recommend first to conduct endoscope-assisted microsurgery, followed by endoscopic sphenoidotomy assisted by a rhinologist, and then to proceed with the endoscopic endonasal transsphenoidal approach [1].

### **Endoscope-assisted transsphenoidal microsurgery**

Transsphenoidal microsurgical procedure can be performed through sublabial approach or endonasal route.

After a retractor is placed through rhinoseptal route, anterior sphenoidotomy is made, and the entire septa inside the sinus are removed, the endoscope is used to provide a panoramic view of the posterior wall of the sphenoidal sinus and to establish anatomical landmarks. Radiological identification can not be used. In tumor resection phase, endoscope's angled lenses provide direct visualization of hidden anatomical corners. Therefore, the endoscope can be introduced intrasellar (to view lateral walls) or suprasellar. The retractor limits the simultaneous use of endoscope and surgical instruments.

The endoscope-assisted microsurgery is efficient especially for macroadenomas with suprasellar or parasellar extension. In these particular cases, the precise localization of the tumor can be estimated and the remnant tumor tissue from the recesses can be identified and removed by using the endoscope guiding. In this way, the resection rate for secreting adenomas is improved; this type of adenoma needs total resection for complete cure. Also, the endoscope provides the view of the walls of the cavernous sinuses and reduces the risk of injury at this level [2, 3].

### **Endoscopic sphenoidotomy for endonasal placement of a transsphenoidal retractor**

Transsphenoidal microsurgical procedure is preceded by an endoscopic sphenoidotomy made by a rhinologist using an endonasal route. Afterwards, a transsphenoidal retractor is placed through endonasal route and the microsurgical

approach can be performed [1]. This technique offers special advantages because endonasal approach and endoscopic sphenoidotomy avoid nasal packing, postoperative discomfort is minimal and patients recover fast.

### **Endoscopic endonasal transsphenoidal approach**

Endoscopic endonasal transsphenoidal approach is performed exclusively under endoscopic visualization. The endoscope provides wide panoramic views, optical zoom-in on surgical targets and visualization of various anatomical corners using its angled lenses. Surgical instruments must be parallel with the endoscope. Paraseptal approach (between middle turbinate and nasal septum) is used through patient's natural nasal air-passage. Unlike conventional approach, the endoscopic approach does not require transsphenoidal retractor, radiological identification, dissection of mucosa of nasal septum and nasal packing. Endoscopic endonasal transsphenoidal approach can be difficult, and it must be performed by surgeons with experience in endoscopic surgery.

Neurosurgeons with no experience in using the endoscope require a learning period (the first 20 to 30 cases) [1, 4]. The endoscope is held in the surgeon's non-dominant hand and the surgical instruments are held in the other hand. The surgical instruments must be inserted parallel with the endoscope through a narrow natural corridor, respecting the anatomy. The surgical technique is improved by using a wide

variety of endoscope holders and specific instruments.

### Indications

The surgical indications for endoscopic endonasal transsphenoidal approach are similar to those for transsphenoidal microsurgery. This technique can be used for intrasellar lesions, intrasellar lesions with symmetric suprasellar extension, or lesions that extend into sphenoidal or cavernous sinus (when a massive tumor resection is needed, usually followed by radiotherapy). Intrasellar lesions with asymmetric or polilobate suprasellar extensions require intracranial approach. Sagittal or lateral extended approach make it possible to treat lesions located in the tuberculum sellae, planum sphenoidale, clivus, or sphenoidal regions.

Endoscopic endonasal transsphenoidal approach is recommended in the treatment of:

- pituitary tumors (adenomas and carcinomas);
- craniopharyngiomas;
- Rathke's cleft cysts;
- germinoma located in the sellar or parasellar region; these tumors represent about 20% of all germ cell intracranial tumors [5]; these tumors can be approached by endoscopic endonasal transsphenoidal approach for decompression of the optic pathways and histological diagnosis [6].
- epidermoid tumors;
- malignant tumors;
- intrasellar arachnoid cysts;
- empty sella;
- clival tumors;

- tuberculum sellae meningiomas or planum sphenoidale meningiomas;

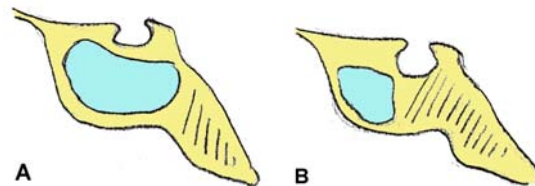
- cerebrospinal fluid sphenoidal fistulas [7];

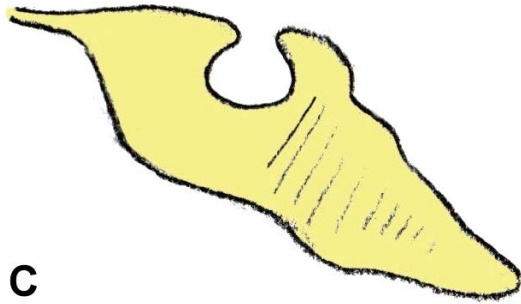
- congenital, iatrogenic or posttraumatic meningoencephalocele of sphenoidal region [6].

Endoscopic endonasal transsphenoidal approach is preferred for recurrent pituitary tumors that have been first treated through conventional transseptal transsphenoidal surgery because it is minimally invasive [8].

Minimally invasive endoscopic endonasal transsphenoidal surgery provides easy and quick recovery; therefore, this procedure is recommended for sellar and parasellar lesions in children. It is essential to keep children's anatomical and functional integrity to ensure their normal growth and nasosphenoidal ventilation [6].

Several factors should be considered when contemplating this type of surgery. First, the amount of pneumatization of the sphenoid body is important. There are three types of adult sphenoid sinuses: the sellar type (86% of cases), which is fully pneumatized, the presellar type (11% of cases), with less pneumatization and the conchal type (3% of cases), without pneumatization, thus limiting access to the sella (Figure 1).





**Figure 1 (A, B, C) Types of pneumatization of the sphenoid body. A – sellar type; B – presellar type; C – conchal type**

Active infection in the sphenoid sinus prevents any transsphenoidal pituitary surgery. If the septum is grossly deviated, a septoplasty may be performed prior to opening the sphenoid. Rare contraindications include carotid arteries that project into the midline [9].

### Preoperative evaluation

Preoperatively, all patients should undergo clinical examination, endocrine testing, ophthalmological (visual field and acuity) and rhinological assessment, and radiological investigations. MRI is the investigation of choice, because it provides better definition of tumors. Gadolinium is given to help identify the tumor, as well as to delineate adjacent vessels, indicating the proximity to the tumor of such parasellar structures such as optic nerves, cavernous sinuses and internal carotid arteries. CT scanning (with bone window, high resolution coronal and axial scans, intravenous contrast and three-dimensional reconstruction) is performed for sellar and parasellar surgery to view nasal cavities and paranasal sinuses. Also, CT scan images are useful to select the approach (right or left), to assess the

pneumatization of the sphenoid, and the position of its septa.

### Equipment

Endoscopic approach, when compared with standard transsphenoidal microsurgical approach, has two distinguishing characteristics that arise from the use of endoscope as the sole optic system and the absence of transsphenoidal retractor [10]. These require proper endoscopic equipment and specifically designed surgical tools.

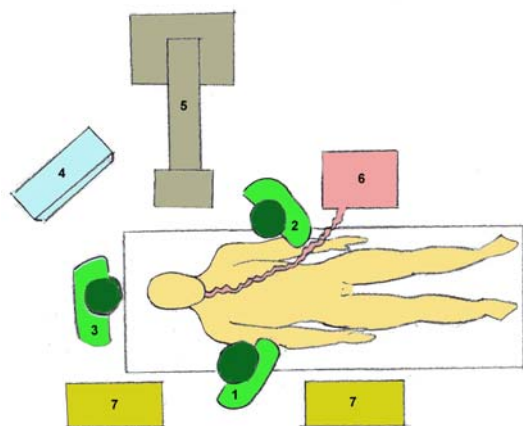
Endoscope must function perfectly and offer good quality images. Commonly used endoscopes are rigid scopes with 4 mm in diameter, 18 or 30 cm in length, equipped with zero, 30 and 45-degree lenses, according to different steps of the surgical operation. Smaller endoscopes that are 2.7mm in diameter can be used, especially in children and in patients with very narrow nostrils. The endoscope must be introduced in a sheath, connected to a cleaning-irrigation system, and controlled by a manual or foot switch. The irrigation system permits cleaning of the distal lens, thus avoiding repeated entrances and exits from the nostril. An endoscope holder is used to provide stability to the endoscope during the sellar phase, thus freeing surgeon's hands and providing a fixed image of the operating field.

The C-arm fluoroscopy is used in particular cases (patients with presellar or conchal-type sphenoid sinuses). The use of the neuronavigation system (conventional or "augmented reality") can be helpful to assist in the identification of the anatomic landmarks, particularly in patients with recurrent tumors [11, 12]. Virtual neuroendoscopic system is used in learning and preoperative planning [13].

Surgical instruments are different from those used in a microsurgical approach, in which the bayonet shape is needed to avoid conflict between surgeon's hands and microscope's lenses. In the endoscopic approach, straight instruments are preferable as they can be inserted close to the endoscope along its axis. Instruments are equipped with differently angled tips such that surgeons can manage all areas that become visible as a result of the wider view afforded by the endoscope.

### Standardized Surgical Technique

Patients with preoperative hypopituitarism receive hormonal replacement therapy before their operation, and a single dose of hydrocortisone (100 mg) is administered at surgery. Prophylactic antibiotics composed of 1g cefazolin or occasionally 1g vancomycin and 80 mg gentamicin (if the patient is allergic to cefazolin) are administered intravenously as a single intraoperative dose [14, 15].



**Figure 2** Surgical setup and relative position of patient and surgeons. 1 – surgeon; 2 – cosurgeon; 3 – scrub nurse; 4 – TV monitor; 5 – C-arm image intensifier; 6 – anesthetic machine; 7 – instrument trays

The operating team and equipment are positioned in an ergonomic setup (Figure 2).

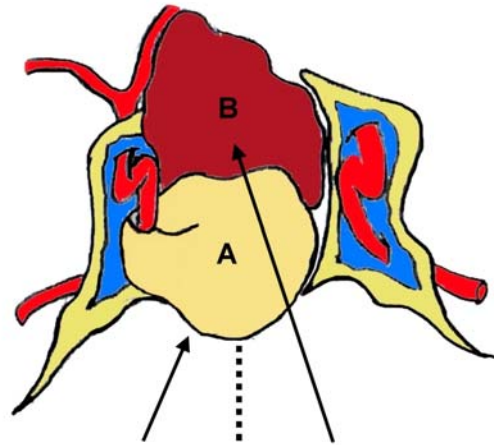
The operation is performed under general anesthesia with orotracheal intubation. Patients are placed supine and their torso is elevated about 10–20 degrees to reduce the venous pressure in the cavernous sinus. Patient's head is put in a Mayfield headrest and turned 10–20 degrees in an horizontal plane toward the surgeon. The inclination of the head in the vertical plane varies as a function of the anatomy of the lesion. If lesions are primarily in the sellar region or the clivus, the head is slightly flexed, whereas in lesions that extend toward the suprasellar region or the planum sphenoidale, the head of the patient is left in a neutral position slightly hyper extended. These variations of the head's inclination are necessary to avoid surgical instruments interfering with patient's thorax. The corneas are protected with ophthalmic ointment, and the eyelids are closed. The operating field (nasal cavities, nose and face) is prepared with 5% providone-iodine solution or 5% chlorhexidine gluconate. If fat graft material is used, abdominal fat is harvested through a 1–2 cm long infraumbilical skin incision. Once the patient is draped aseptically, the endoscope is assembled.

Standard technique includes three phases: nasal, sphenoid and sellar phase [10]. During nasal phase, the endoscope is introduced through the nostril and is advanced until it reaches the sphenoid ostium.

During the sphenoid phase, the nasal septum is separated from the sphenoid rostrum and anterior sphenoidotomy is performed, i.e. the entire septa inside the sphenoid sinus are removed and the anatomical landmarks are exposed. During the sellar phase, the sellar floor is opened, the lesion is removed, the sellar reconstruction is performed and the endoscope is pulled out.

### 1. Nasal phase

The side of the nasal cavity to be used is determined by the width of the nasal cavity and the side of the tumor. Preferably, the wider side of the nasal cavity is used. The anatomy of nasal cavity can be altered by septal deviation, hypertrophy of nasal turbinates, scars or synechias (in recurrent tumors, when the first operation was conventional transseptal transsphenoidal microsurgery). In these situations, the other nostril will be used. Occasionally, partial removal of the middle turbinate is necessary to improve access. Sellar lesions can be approached both ipsilateral or contralateral, depending on the localization and extension of the tumor. Thus, an inferior extension of the tumor (into the sphenoid sinus) or a lateral extension in the anterior inferior part of the cavernous sinus can be efficiently reached by ipsilateral nostril. On the other hand, it is advisable to approach through the contralateral nostril a laterally located microadenoma, an extension in the medial part of the cavernous sinus or an asymmetric suprasellar tumor, because an endonasal approach is a few degrees off midline and would easily lead to the contralateral sella (Figure 3).



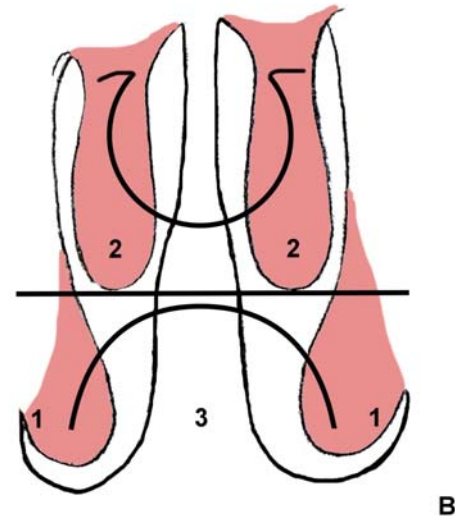
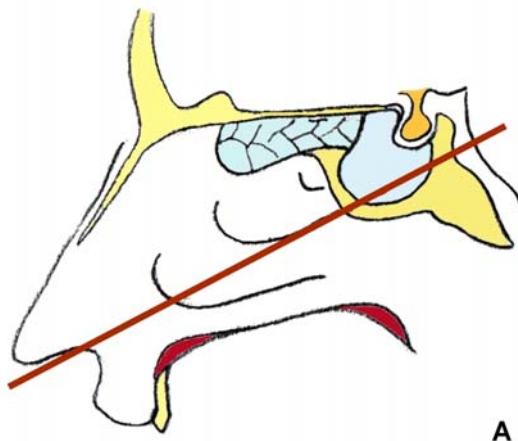
**Figure 3** An inferior extension of the tumor (into the sphenoid sinus) or a lateral extension in the anterior inferior part of the cavernous sinus can be efficiently reached by ipsilateral approach (lesion A). An asymmetric suprasellar extension can be easily removed by contralateral approach (lesion B).

Some authors recommend adequate nasal vasoconstriction prior to surgery to ensure a minimal bleeding from nasal mucosa. The middle turbinate, the anterior wall of the sphenoid and the rostrum are infiltrated with 1% xiline and 1:200 000 adrenaline. Cottonoids soaked in 1:10 000 adrenaline are then placed in the nose both sides [16]. Other authors consider local vasoconstriction unnecessary [14, 17], but recommend correct analgesia and sometimes controlled hypotension [10, 14]. Topical vasoconstriction reduces mucosal bleeding during surgery, but it is usually associated with postoperative bleeding when drugs cease their action [17].

Zero-degree endoscope (4 mm in diameter, 18 cm in length) is introduced through the chosen nostril, tangential to the floor of the nasal cavity. The first structures to be identified are the inferior turbinate laterally and the nasal septum

medially. As the endoscope advances along the floor of the nasal cavity, it reaches the choana (communicating orifice with the nasopharynx). Its medial margin is the vomer, which confirms the midline of the approach, and its roof is shaped by the inferior wall of the sphenoid sinus. Lateral to the choana is the tail of the inferior turbinate. The head of middle turbinate, which is usually close to the nasal septum, can be observed above the inferior turbinate.

The main surgical landmarks are the communicating orifice with the nasopharynx and the inferior margin of the middle turbinate. Sometimes the superior turbinate mimics the middle turbinate. Therefore, anatomical reference to the choana is essential to confirm the middle turbinate. The level of the inferior margin of the middle turbinate is just rostral to the nasopharynx in a vertical axis. The line drawn along the inferior margin of the middle turbinate extends posteriorly to about 1 cm inferior to the floor of the sella [14] (Figure 4).



**Figure 4** The line drawn along the inferior margin of the middle turbinate extends posteriorly to about 1 cm inferior to the floor of the sella. **A** – sagittal section; **B** – coronal section. 1 – inferior turbinate; 2 – middle turbinate; 3 – projection of the choana; 4 – projection of the sella.

The mucus conduit from the frontal sinus, anterior ethmoidal sinus, and maxillary sinus is through the hiatus semilunaris, which is laterally to the middle turbinate. Posteriorly, the sphenothmoidal recess, which is along the lateral margin of the anterior wall of the sphenoidal sinus, is a mucus conduit from the posterior ethmoidal sinus and sphenoidal sinus. During the operation, caution must be used not to damage these mucus pathways to prevent postoperative sinusitis [14, 17].

To enlarge the approach space, cottonoids soaked with isotone saline solution [14], with diluted adrenaline (1:100 000) or with xylometazoline hydrochloride [10] are positioned between the middle turbinate and the nasal septum. The head of the middle turbinate is delicately dislocated laterally.

Then the cotton patties are removed and the endoscope is angled upward along the roof of the choana and the sphenothmoidal recess until it reaches the sphenoid ostium, usually located approximately 1.5 cm above the roof of the choana.

The sphenoid ostium is extremely variable in localization, size and shape. When the ostium is situated laterally, it can be covered by superior or supreme turbinate; in these cases, the superior and/or the supreme turbinate can be lateralized or removed. A CSF leak can occur due to fracture of the lateral lamella or of the cribriform plate, on which these turbinates are inserted. If the sphenoid ostium is not visible and the sphenoid sinus is well pneumatized, an artificial orifice can be made between nasal septum and superior turbinate, at approximately 1.5 cm above the superior margin of the choana.

## 2. Sphenoid phase

Once the sphenoid ostium is identified, coagulation of the mucosa of the anterior wall of the sphenoid sinus is performed. This serves to avoid arterial bleeding originating from septal branches of the sphenopalatine artery. The vomer is the landmark for the midline.

A microdrill or a septal breaker is used to separate the nasal septum from the sphenoid rostrum [17]. Submucosal dissection of anterior wall of contralateral sphenoidal sinus is made, such that the anterior wall is bilaterally exposed. The anterior sphenoidotomy about 1.5-2 cm is made with a microdrill or with Kerrison punches (Figure 5). The sphenoid rostrum is removed in fragments and not

“en bloc”. It is mandatory to remove the anterior wall of the sphenoid widely, especially downward, before reaching the sella; otherwise, the instruments are not able to reach all the areas visible by the endoscope. Caution must be used in the inferolateral direction, where the sphenopalatine artery or its major branches lies, to avoid arterial bleeding. The haemostasis is obtained by coagulation with bipolar forceps. In endoscopic surgery it is essential to have an operating field without bleeding. The mucosa is removed only in the anterior sphenoidotomy zone.

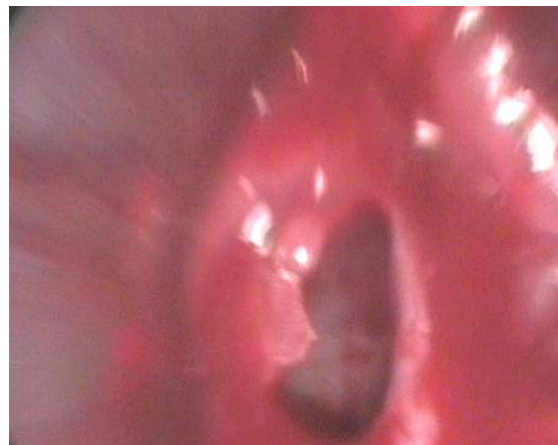

Figure 5 Anterior sphenoidotomy – endoscopic view

When the sellar lesion does not extend into the sphenoidal sinus, there is sufficient space to manoeuvre the endoscope and the instruments. If the sellar lesion invades the sphenoidal sinus, it is necessary to remove about 1 cm from the posterior part of nasal septum. One or more septa can be identified inside the sphenoid sinus. The images of the sphenoid sinus septations are revealed by the preoperative CT scan (in coronal and axial sections). These images are very useful, especially when the septa are implanted on the carotid prominences



and the sphenoid sinus is a presellar type. These septa must be removed as much as possible by cutting bone punches, avoiding detachment of the sphenoid mucosa unless adenomatous infiltration is evident or suspected.

At this moment in the procedure, the landmarks inside the sphenoid sinus are identified (Figure 6, 7). The sellar floor at the centre, the sphenothmoidal planum above it, and the clival indentation below are visible. Lateral to the sellar floor, the bony prominences of the intracavernous carotid artery and the optic nerve can be observed; between them, the optocarotid recess can be found. In 4% of the cases, the internal carotid artery and the optic nerve do not have bone protection [18]. In the presence of a presellar or a conchal sphenoid sinus, there will be a paucity of anatomic landmarks. The neuronavigation system is very useful in these situations.

### 3. Sellar phase

In this phase of the procedure, a longer endoscope (zero-degree angled lens, 4 mm in diameter and 30 cm in length) is used. The endoscope is mounted on the endoscope holder, such that surgeon's both hands are free.

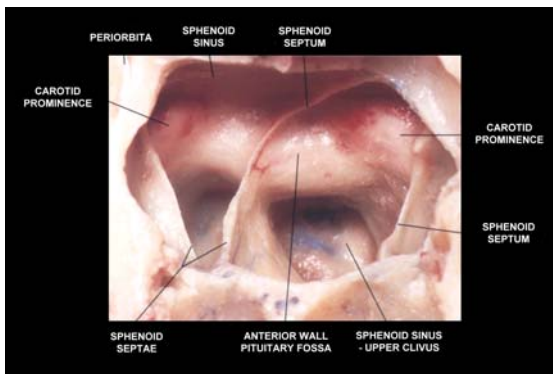


Figure 6 Panoramic view of the posterior wall of the sphenoidal sinus.

The endoscope holder is fixed at a certain distance from sella turcica to allow a comfortable use of the instruments. The opening of the sellar floor is performed with bone punches or a microdrill and must be extended as required by the specific pathological process.

The dura is incised in a midline position, in a linear, rectangular, or cruciate fashion (Figure 8). The superior and the inferior intercavernous sinuses are usually compressed and obliterated in patients with macroadenomas, making the dural incision bloodless; in microadenomas, and especially in Cushing disease, the entire sellar dura may be covered by one or two venous channels, which can bleed during the dural incision. To avoid this, these venous channels are secured and sealed with bipolar coagulation forceps or with small surgical clips placed across them. Sometime, an ectatic carotid artery may be located within the sella.

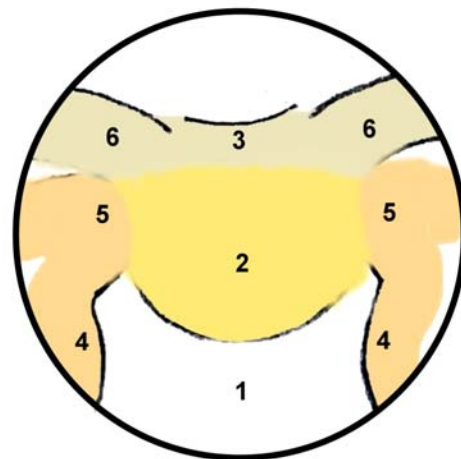
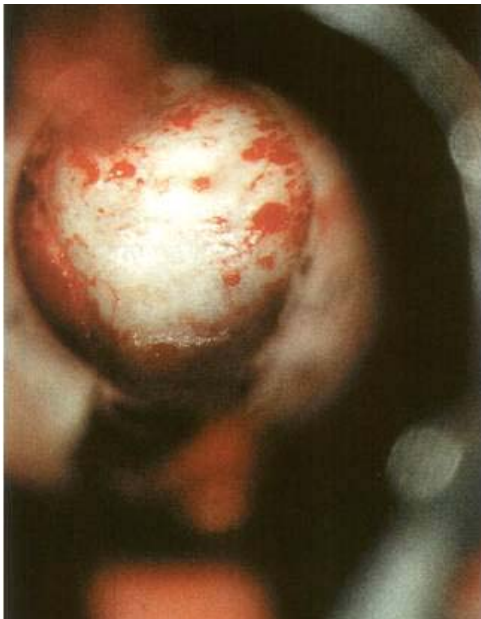


Figure 7 Schematic drawing of the panoramic endoscopic view of the posterior wall of the sphenoidal sinus. 1 – clival indentation; 2 – sella; 3 – tuberculum sella; 4 – bony protuberances covering the carotid artery; 5 – bony protuberances covering the cavernous sinus; 6 – optic protuberances.

The sellar phase of the endoscopic procedure must follow the already well defined rules of the microsurgical transsphenoidal approach.

In cases involving microadenomas, the tumor is removed with a small ring curette from the suspected location suggested by MRI images. While the tumor tissue is curetted out, the thin shell of normal pituitary tissue is shaved along the tumor cavity [17]. In cases of macroadenomas, the inferior part is excised first and then the lateral part of the tumor. An angled 30-degrees or 40-degrees endoscope is advanced into the tumor cavity to see lateral parts and to verify the presence of any tumor remnants that are often imprisoned in the recesses created by the fall of suprasellar cistern.



**Figure 8** Endoscopic view. After the opening of the sellar floor, the dura mater is incised in a midline position and often tumor tissue spills over.

The tumor remnants are removed with curved instruments. When the lesion extends toward the medial wall of the cavernous sinus, its removal can be accomplished under endoscopic control.

The venous bleeding that might occur can be controlled by temporarily positioning haemostatic substances and cottonoids and by gentle compressing the medial wall of cavernous sinus and irrigating for a few minutes. Attention must also be paid to the anterior superior and suprachiasmatic regions that are not situated on the surgical trajectory in the endoscopic approach. Finally, the suprasellar part is progressively removed from the periphery of the diaphragm sella toward the centre; this way is avoided the premature release of the redundant diaphragm, which would obscure visualization of the lateral portions, into the operative field. After tumor's removal, if the descent of the suprasellar portion of the lesion is not observed, it is useful to perform a Valsalva maneuver, which may encourage protrusion of the suprasellar cistern into the sellar cavity. After intracapsular emptying of the tumor, its pseudocapsule can be dissected from the suprasellar cistern. Attention must be taken not to rupture the arachnoid membrane that prevents cerebrospinal fluid (CSF) leak. Vector maneuvering of the surgical instruments during tumor resection should avoid any force that would apply traction to the pituitary stalk. Traction injury to the pituitary stalk carries the risk of postoperative diabetes insipidus. The junction with normal pituitary tissue is identified and preserved.

A sellar reconstruction is performed in selected patients with the purpose of reducing the dead space, creating a protective barrier, and preventing the descent of the chiasm into the sellar cavity. Sellar repair is mainly indicated when the tumor resection cavity is large or a CSF leak occurs intraoperative. Various techniques are used: intradural and/or extradural closure of the sella and packing of the sella with or without

packing of the sphenoid sinus [14, 15, 17, 19-22]. Postoperative, lumbar drainage is used to prevent or to treat a CSF leakage.

At the end of the procedure, haemostasis is obtained, irrigation is performed and the endoscope is removed gradually. Generally, the sphenoid sinus is maintained empty without any foreign materials inside it. The middle turbinate is gently restored in a medial direction and contact with nasal septum is avoided to prevent the formation of synechias. Packing of the nasal cavity for a few hours is not considered necessary, except for instances when a diffuse intraoperative bleeding from the nasal mucosa occurred, as it may happen in some acromegalic patients or in poorly controlled hypertensive patients [10].

Standard endoscopic endonasal transsphenoidal approach uses a paraseptal route. The approach of the sphenoid rostrum is made between nasal septum and lateral luxated middle turbinate. The vomer and the nasal septum are detached from the sphenoid rostrum and moved contralateral. But this approach is very flexible. It can be adapted to different anatomical aspects, and can be used in various sellar and suprasellar lesions. Some changes in the standard technique were made to optimize the surgical resection in minimally invasive conditions [23]. One could use a minimal approach (hemisphenoidotomy), a deep transseptal approach, an extended approach (superior, inferior or lateral) or a bilateral approach.

#### **Postoperative Care**

Postoperative discomfort is minimal and the narcotic analgesics are rarely necessary. Nasal drainage is also minimal. The use of the saline douches three times a day diminishes nasal crusting and prevents synechias. An ointment is also used with antibiotics for local applications

in the nasal cavity three times a day. Patients are kept on a five-day course of oral clarithromycin (1g/day) [14, 17]. Postoperative risk for diabetes insipidus is high, so the patients are observed in a regular hospital room for two days [15]. The electrolytes are measured after the operation and the next morning. Cortisol is also measured the following morning. When the cortisol level is higher than 15 ng/dL, postoperative steroids are unnecessary. Patients with cortisol level less than 15 ng/dL are placed on hydrocortisone (20 mg every morning and 10 mg early night). Patients with Cushing's disease are discharged with dexamethasone (1 to 2 mg/day) [14]. An endocrinological evaluation is necessary several weeks after the surgical procedure.

If patients develop CSF leak postoperatively, this is immediately repaired using an endoscopic technique. Lumbar drainage can be useful.

On postoperative day 15, patients undergo clinical evaluation and after three months clinical and neuroradiologic evaluation (MRI scan with gadolinium). Patients with hormone-secreting microadenomas are followed with interval endocrine testing. Patients with macroadenomas and hormone non-secreting adenomas are followed with interval MRI scan of the brain.

#### **Conclusions**

The endoscopic endonasal transsphenoidal approach has major advantages relative to the conventional microsurgery technique: provides an excellent view of the operating field, is less invasive, reduces the incidence of complications, and decreases the postoperative discomfort, the postoperative hospitalization, as well as the cost of patient treatment [24]. The

adaptability of the endoscopic transsphenoidal approach to different pathological conditions permits the best treatment of the various sellar and parasellar lesions, allowing an adequate surgical procedure (more or less invasive).

**Correspondence to:** Ligia Tataranu, MD, PhD, "Bagdasar-Arseni" Clinical Emergency Hospital, Sos. Berceni 10-12, 041514 Bucharest, Romania

E-mail: medic@neurochirurg.ro;

Phone: +40744-375 000

## References

- Jho HD, Alfieri A, Endoscopic transsphenoidal pituitary surgery: various surgical techniques and recommended steps for procedural transition. *British Journal of Neurosurgery*, 2000. 14(5): p. 432-440.
- Baussart B, Aghakhani N, Portier F, Chanson P, Tadie M, Parker F, Endoscope-assisted microsurgery for invasive endo- and parasellar pituitary macroadenomas: a consecutive retrospective study with 13 patients. *Neurochirurgie*, 2005. 51(5): p. 455-463.
- Ellamushi H, Powell M, Endoscope-assisted transsphenoidal pituitary microsurgery, in *The centre of the skull base. Proceedings of the 4th European Skull Base Society Congress*, Fahlbusch R, Buchfelder M, Editor. 2000, Einhorn-Press Verlag, p. 192-199.
- Kenan K, Ihsan A, Dilek O, Burak C, Gurkan K, Savas C, The learning curve in endoscopic pituitary surgery and our experience. *Neurosurgical Revue*, 2006. 29(4): p. 298-305.
- Jellinger K, Primary intracranial germ cell tumours. *Acta Neuropathol*, 1973. 25: p. 291-306.
- de Divitiis E, Cappabianca P, Gangemi M, Cavallo LM, The role of the endoscopic transsphenoidal approach in pediatric neurosurgery. *Child's Nervous System*, 2000. 16: p. 692-696.
- Kelley TF, Stankiewicz JA, Chow JM, Origitano TC, Shea J, Endoscopic closure of postsurgical anterior cranial fossa cerebrospinal fluid leaks. *Neurosurgery*, 1996. 39: p. 743-746.
- Cappabianca P, Alfieri A, Colao A, Cavallo LM, Fusco M, Peca C, Lombardi G, de Divitiis E, Endoscopic endonasal transsphenoidal surgery in recurrent and residual pituitary adenomas: technical note. *Minimally Invasive Neurosurgery*, 2000. 43: p. 38-43.
- Couldwell WT, Weiss MH, Pituitary macroadenomas, in *Brain Surgery*, Apuzzo MLJ, Editor. 1993, Churchill Livingstone: New York. p. 295-310.
- Cappabianca P, Cavallo LM, De Divitiis E, Endoscopic endonasal transsphenoidal surgery. *Neurosurgery*, 2004. 55(4): p. 933-941.
- Kawamata T, I.H., Shibasaki T, Hori T, Endoscopic augmented reality navigation system for endonasal transsphenoidal surgery to treat pituitary tumors: technical note. *Neurosurgery*, 2002. 50(6): p. 1393-1397.
- Lasio G, Ferroli P, Felisati G, Broggi G, Image-guided endoscopic transnasal removal of recurrent pituitary adenomas. *Neurosurgery*, 2002. 51(1): p. 132-137.
- Wolfsberger S, F.M., Donat M, Neubauer A, Buhler K, Wegenkittl R, Czech T, Hainfellner JA, Knosp E, Virtual endoscopy is a useful device for training and preoperative planning of transsphenoidal endoscopic pituitary surgery. *Minimally Invasive Neurosurgery*, 2004. 47: p. 214-220.
- Jho HD, Endoscopic transsphenoidal tumor surgery. *Operative Techniques in Neurosurgery*, 2002. 5(4): p. 218-225.
- Jho HD, Carrau RL, Endoscopic endonasal transsphenoidal surgery: experience with 50 patients. *Journal of Neurosurgery*, 1997. 87: p. 44-51.
- Pell MF, Atlas MD, Biggs ND, Endoscopic pituitary tumor removal, in *Operative Neurosurgery*, Kaye AH, Black PM, Editor. 2000, Churchill Livingstone: London. p. 715-722.
- Jho HD, Alfieri A, Endoscopic endonasal pituitary surgery: evolution of surgical technique and equipment in 150 operations. *Minimally Invasive Neurosurgery*, 2001. 44: p. 1-12.
- Rhoton AL, Harris FS, Renn WH, Microsurgical anatomy of the sella region and cavernous sinus. *Clinical Neurosurgery*, 1977. 24: p. 54-85.
- Cappabianca P, Cavallo LM, Mariniello G, de Divitiis O, Romero ACB, de Divitiis E, Easy sellar reconstruction in endoscopic endonasal transsphenoidal surgery with polyester-silicone dural substitute and fibrin glue: technical note. *Neurosurgery*, 2001. 49(2): p. 473-476.
- Cappabianca P, Cavallo LM, Valente v, Romano I, D'Enza AI, Esposito F, de Divitiis E, Sellar repair with fibrin sealant and collagen fleece after endoscopic endonasal transsphenoidal surgery. *Surgical Neurology*, 2004. 62(3): p. 227-233.
- Cappabianca P, C.L., Esposito F, Valente V, de Divitiis E, Sellar repair in endoscopic endonasal transsphenoidal surgery: results of 170 cases. *Neurosurgery*, 2002. 51(6): p. 1365-1371.
- Kubo S, Hasegawa H, Inui T, Tominaga S, Yoshimine T, Suture knot on the repair splint: a simple method to facilitate reconstruction of the sella turcica during endonasal endoscopic transsphenoidal surgery. Technical note. *Journal of Neurosurgery*, 2005. 102(5): p. 938-939.
- de Divitiis E, Cappabianca P, Cavallo LM, Endoscopic transsphenoidal approach: adaptability of the procedure to different sellar lesions. *Neurosurgery*, 2002. 51(3): p. 699-707.
- Cappabianca P, Alfieri A, Colao A, Ferone D, Lombardi G, de Divitiis E, Endoscopic endonasal transsphenoidal approach: an additional reason in support of surgery in the management of pituitary lesions. *Skull Base Surg*, 1999. 9: p. 109-117.