

## **Unruptured Arteriovenous Malformations of Brain An overview**

**Rohan Shetty, Yoko Kato, Takeya Watabe, Daikichi Oguri, Junpei Oda,  
Sadato Akiyo, Motoharu Hayakawa, Hirotoishi Sano**

Department of Neurosurgery  
Fujita Health University Hospital  
Dengakugakubo, Aichi-ken  
Japan -4701192  
Email:shettyrohanadi@yahoo.co.in

### **Abstract**

Arteriovenous malformations are congenital lesions that occur most commonly in the supratentorial region. These space-occupying vascular lesions consist of multiple arteries and veins, connecting as a fistula without an intervening normal capillary bed. Typically, AVM's are single lesions, except when associated with hereditary hemorrhagic telangiectasia. The histology includes clusters of normal or dilated arteries and abnormal veins with calcification and occasionally some prior haemorrhage.

**Keywords: grading, hemorrhage, re haemorrhage, seizures, unruptured arteriovenous malformation**

### **Introduction**

Arteriovenous malformations (AVM) of the brain are congenital vascular lesions that account for approximately 2%- 3% of all hemorrhagic strokes[1]. Despite the relative rarity of the disease (with an estimated current detection rate of approximately 1/100 000 person-years) AVMs pose a significant neurological problem because patients are mostly young and otherwise healthy. Moreover, the availability of noninvasive imaging has rapidly increased the detection of incidental AVM's. The complex cerebrovascular anatomy of AVM's makes them a challenge to treat, and the treatment itself carries significant risks.

To evaluate the possible benefit of a risky treatment, one needs to understand the natural history and prognosis of the disease. The complexity of AVM's makes them a rather heterogeneous group of lesions in terms of various factors possibly affecting the risk of rupture and subsequent hemorrhagic stroke. Over the past several decades, several groups have contributed to our knowledge of the haemorrhage risk associated with untreated AVM's. However, the development of therapeutic strategies has made it increasingly rare that a large proportion of patients would be followed conservatively.

### Clinical Presentation

The most common presentation in unruptured AVM's is focal or generalized seizures, which occur in 25% of patients. Other presentations include headache in 15% of patients, which may mimic migraine, focal neurologic deficit, and pulsatile tinnitus. Rarely, a deficit may be caused by a "steal" phenomenon of blood through the fistula, which deprives some surrounding neurons of required blood. The lesions are distinctly uncommon in children; presentations include congestive heart failure and large head due to hydrocephalus.

Headache not due to hemorrhage is the presenting symptom in 7% to 48% of patients [11]. No distinctive type, frequency, persistence, or severity occurs. Earlier speculations have proved unfounded for a pattern differentiated from classical or common migraine, or that recurrent unilateral headache reflects an underlying AVM [12]. Response to medication has not been systematically studied, and although some

reports state improvement in headache [13], proof is lacking that patients under optimal medical headache management require invasive treatment of their symptoms. Some reference to focal neurologic deficits without signs of underlying hemorrhage has been reported in 1% to 40%, with this large range reflecting non uniformity of definitions. Only a few patients (4% to 8%) have well documented progressing neurologic deficits [11]. Once considered common, progressing syndromes were thought

to be caused by "stealing" (ie, cerebral artery hypotension leading to ischemia in

brain tissue adjacent to the lesion) [14,15]. Arteriovenous malformations sometimes induce remarkable degrees of cerebral arterial hypotension, but evidence is lacking for a causal link with symptoms[11]. As of today, no definite information exists that may warrant invasive AVM treatment on the assumption of a clinical relevant intracranial steal caused by an unruptured AVM [16]. Venous hypertension or mass effect of the nidus offers alternative explanations for progressing focal neurologic deficits [17].

The natural history of unruptured AVM's seems more favorable than for those discovered after initial haemorrhage. The average risk of bleeding from an unruptured AVM (1.2% per year) seems to be about 5 times lower as compared with already ruptured malformations (5.6% per year). The bleeding risk seems to be particularly low in the most frequent subgroup of patients harbouring lobar AVMs with superficial venous drainage (0.9%peryear). Finally, although some instances of AVM rupture may indeed be disastrous, there seems to be a far lower morbidity and mortality than after intracerebral bleeding from other causes.

Haemorrhage: Peak age for haemorrhage is between age of 15 -20 yrs with a mortality of 10% & a morbidity of 30 -50 % from each bleed. Haemorrhage was related to AVM size with small AVM's presenting more often with bleed than do large ones. Larger AVM's more often presented with seizures merely because of involvement of the cortex. So conclusion is that small AVM's are more

lethal than larger ones. Among patients who present with haemorrhage, the risk of recurrent haemorrhage is elevated early; the risk during the first year is between 6% and 17% and then decreases to a baseline level by the third year. After a second haemorrhage, the risk of another recurrent haemorrhage maybe even higher during the first year, up to 25%. Clinical and imaging features at the time of initial diagnosis of an AVM may predict future haemorrhage risk. From a clinical standpoint, prior haemorrhage is a strong predictor of haemorrhage. On imaging, small AVM diameter or small volume may be predictive, but this has not been noted consistently. The venous drainage system may be particularly important, with deep venous drainage a potential predictor of haemorrhage. Impaired venous drainage and a single draining vein also have been predictive of hemorrhage. In the arterial system of the periventricular or intraventricular area, the risk of haemorrhage may be increased by the presence of very distal aneurysms on the small feeding arteries (the so-called intranidal aneurysms), the presence of

multiple aneurysms, and arterial supply via middle cerebral artery perforators.

The presence of any non-nidal aneurysms also may increase the risk of haemorrhage.

Developments in the field of genetic research and biomarkers, with the goal of identifying patients with increased AVM hemorrhage risk, are ongoing. Initial results show associations of the tumor necrosis factor (TNF)- $\alpha$ -238 AG genotype [35], the interleukin (IL)-6-174GG genotype with high expression of IL-6 protein in brain AVM tissue [36], and an abnormal balance of matrix metalloproteinase (MMP)-9 and tissue inhibitors of metalloproteinases (TIMP) in the AVM with increased probability of AVM hemorrhage [37]. Whether mechanisms involved will be helpful in the decision process of AVM treatment remains unsettled

**Rebleeding:** Rebleeding rate in the first year after haemorrhage was 6% in one series and 18% in another series. In another large series ( ) the annual rate was 4% regardless of type of presentation.

Rebleeding rate declined at 2% per year after 10 years.

#### Life Time Risk of Haemorrhage

Age at Presentation	Estimated Years of Life	1% Annual Risk	2 % Annual Risk	3% Annual Risk
0	76	53	78	90
15	62	46	71	85
25	52	41	65	79
35	43	35	58	73
45	34	29	50	64
55	25	22	40	53
65	18	16	30	42
75	11	10	20	28
85	6	5.8	11	17

Seizures: Seizures not caused by hemorrhage are the mode of initial presentation in 16% to 53% of cases. Grand mal attacks occur in 27% to 35%, with the remainder being partial or partial complex seizures [51]. Few reports document seizure frequency, but response to antiepileptic medication appears satisfactory [52]. Patients with intractable seizures under conservative management do exist but data on their frequency are scarce. Improvement of seizures in over 50% of these patients after stereotactic radiotherapy was

reported in a small recent series [53].

The younger the patient at the time of diagnosis, higher the risk of developing convulsions.

20 years risk

Age 10-19 ---- 44% risk

Age 20-29 ----31% risk

Age 30-60 ----6% risk

No AVM found incidentally or presenting with neurological deficits developed seizures.

AVM'S and Aneurysms: Fifty eight percent of patients with AVM's have aneurysms. 75% of aneurysms are located on the major feeding artery. Aneurysms also may form within the nidus or on the draining veins.

Categories of aneurysms associated with AVM's:

Type	Aneurysm Location
1	Proximal on ipsilateral major feeding artery
1 A	Proximal on major artery related but contralateral to AVM
11	Distal on superficial feeding artery
111	Proximal or distal on deep feeding artery (bizarre )
1V	On artery unrelated to AVM

### Investigations

Unenhanced Computed Tomography has relatively low sensitivity, with calcification and hypointensity

May be visualised; however, with the use of contrast enhancement, the arteriovenous system may be seen. Computed Tomographic Angiography [CTA] provides better vascular detail than magnetic resonance angiography [MRA]. Magnetic resonance imaging [MRI] is more sensitive, with findings such as flow voids and hemosiderin deposition on T1-weighted and T2weighted imaging. Magnetic resonance angiography (MRA) can provide additional information regarding relation of AVM to surrounding cerebral structures. Additional information can be obtained with the use of functional MRI, to identify eloquent brain tissue, and diffusion-tensor imaging to identify different important white matter tracts. Angiography remains the standard by which to evaluate the architecture of the AVM, including presence or absence of associated aneurysms, presence or absence of venous outflow obstruction, and pattern of venous drainage. Three dimensional MRA and three dimensional angiography may provide additional detail to guide interventional treatment. Grading:

#### Spetzler - Martin AVM Grading System [20]

Graded Feature	Points
Size	
Small (< 3 cms )	1
Medium (3-6 cms)	2
Large (>6 cms )	3
Eloquence of adjacent brain	
Non eloquent	0
Eloquent	1
Patten of venous drainage	
Superficial only	0
Deep	1

A separate grade 6 is reserved for untreatable lesions, (by any means) resection of these would almost unavoidably be associated with disabling deficit or death.

### **Discussion**

Patients harbouring brain AVM's are at a life long risk for haemorrhagic stroke, the natural history is poorly understood. Natural history & predictive features of haemorrhage was studied at Toronto western hospital On 678 consecutive patients & were followed for 1931.7 patient years [50]. The rate of haemorrhage over long term follow up was recorded.

The impact of baseline clinical & radiographic features & partial treatment on time to haemorrhage were analyzed using survival analysis. neurologic outcome after haemorrhage was assessed using Glasgow outcome score. Haemorrhage risk was 4.61% per year for entire cohort, 7.8 % per year for brain AVM's with haemorrhagic presentation 4.61 % for brain AVM's with seizure presentation, 3.99 % for patients not harbouring aneurysms, 6.93 % for patients harbouring aneurysms, 5.42 % for patients with deep venous drainage. Haemorrhagic presentation was significant independent predictor of future haemorrhage.. Haemorrhage risk was unchanged in patient who underwent partial arteriovenous embolisation. So they concluded that brain AVM's presenting with haemorrhage, deep venous drainage, or associated aneurysms had twofold likelihood of future haemorrhage. So aggressive short term

management ie; total embolisation / microsurgery was suggested for patients harbouring high risk lesions & therapeutic approaches with longer obliteration times targeted at patients harbouring low risk natural history of haemorrhage.

In a study conducted between July 1997 & 2003, 73 consecutive patients with grade IV & grade V AVM's were evaluated prospectively at Barrow neurosurgical institute [32]. Treatment recommendations were classified as complete treatment, partial treatment & no treatment. Retrospectively haemorrhage rates associated with these treatment groups were also calculated. In the prospective portion of the study [intention to treat analysis ], no treatment of AVM's was recommended for 75 % of patients and partial treatment for 10 % of patients. Aneurysms associated with an AVM were obliterated by surgery or endovascular treatment in 10 % patients & complete surgical removal of AVM for 5% of the patients. The overall haemorrhage rate for grade IV & grade V AVM's was 1.5% per year. The annual risk of haemorrhage was 10.4 % among patients who previously received incomplete treatment compared with patients without previous treatment. Hence they concluded that haemorrhage risk was comparatively less [1.5 % ] for grade IV & grade V AVM's than for grade I to grade III AVM's. So authors recommended no treatment be given for grade IV & grade V AVM's. Partial treatment was discouraged for the fact that it worsened the natural history of an AVM. The authors did not support palliative treatment of AVM except in specific circumstances of arterial

or intranidal aneurysms or progressive neurological deficits related to vascular steal. Complete treatment was recommended for patients with progressive neurological deficits caused by haemorrhage of the AVM. Relatively low combined morbidity & mortality rates for grade IV & grade V AVM's of 17 % & 22 % respectively was reported.

Mahesh.V.Jayaraman et al[41] studied on 61 patients retrospectively with grade IV & grade V AVM's. They reviewed the demographic, angiographic features, presenting symptoms & time of all haemorrhage events before or after treatment initiation. The annual pre-treatment haemorrhage rate of 10.4 % was higher for all patients with 13.9% for patients with haemorrhagic presentation and 7.3% for patients with non haemorrhagic presentation. Post treatment haemorrhage rates were 6.1% per year for all patients, 5.6% for patients presenting with haemorrhage and 6.4% in patients with non haemorrhagic presentation. Based on this data they concluded that grade IV and grade V AVM's warranted treatment and initiation of treatment did not increase the risk of haemorrhage. Initiation of treatment in haemorrhagic group lowered the risk of re haemorrhage to levels with those of non haemorrhagic presentation. [Patients with grade IV and grade V AVM's with prior haemorrhage are at a higher risk of recurrent haemorrhage]

Risk factors for subsequent haemorrhage in patients with cerebral arteriovenous malformations was studied by S.Yamada et al[38] on 305 consecutive patients with AVM's between 1983

&2005. Patients were followed up until the first haemorrhage, start of any treatment or end of 2005. Possible risk factors that were investigated included age at initial diagnosis, sex, type of initial presentation, size and location of AVM, nidus and venous drainage pattern. They reported an annual bleeding rate in haemorrhagic group was 6.8% after haemorrhage and the rate decreased in 5 years to 1.72 %. In the non haemorrhagic group

Annual bleeding rate of 3.12 % was reported. Patients presenting with headache annual bleeding rate of 6.48% was reported and for asymptomatic presentation annual bleeding rate was 6.44%. Conversely patients presenting with seizures had an annual bleeding rate of 2.20 % and with patients with neurological deficits had a bleeding rate of 1.73 %. A significant three fold increase of rebleeding was reported for children, female, and deep seated AVM patients. The increased risk was highest among this group in the first year after initial haemorrhage and there after gradually reduced.

Ian. g. Fleetwood et al[33] from Loma Linda university studied on cohort of 96 patients retrospectively with the AVM's in the basal ganglia and thalamus with respect to tendency of the lesions to bleed between the time of detection and their eventual successful management. Mean age at diagnosis was 22.7 years and 51% were male patients. Intracranial haemorrhage was the event leading to clinical detection in 71.9 % of patients and 85.5% of these were left with hemiparesis. After diagnosis twenty five

patients had bled a total of 49 times. The risk of haemorrhage after detection of an AVM of basal ganglia or thalamus was 9.8% per patient per year. Hence they concluded that rate of haemorrhage in patients with AVM's of thalamus and basal ganglia are much higher at 9.8% compared to avms in other locations [2-4% per ]year.They also concluded that risk of incurring a neurological deficit with each haemorrhagic event was high hence treatment was recommended for these patients.

At the university of Toronto AVM study group assessed patients with large and deep AVM's for their risk of future haemorrhage since 1989 and concluded that patients with AVM's large size and deep location in the brain were the most important and significant factors associated with higher risk of future hemorrhagic events [31].

Long-term follow-up study was done in an unselected, consecutive patient population with AVM's admitted to the Department of Neurosurgery at Helsinki University Central Hospital between 1942 and 2005[50]. Patients with untreated AVM's were followed from admission until death, occurrence of AVM rupture, initiation of treatment, or until the end of 2005. Patients with at least 1 month of follow-up were included in further analysis. Annual and cumulative incidence rates of AVM rupture as well as several potential risk factors for rupture were analyzed. Two hundred and thirty eight patients with a mean follow-up period of 13.5 years were included (range, 1 month–53.1 years). The average annual risk of hemorrhage

from AVMs was 2.4%. The risk was highest during the first 5 years after diagnosis, decreasing thereafter. Risk factors predicting subsequent AVM hemorrhage in univariate analysis were young age, previous rupture, deep and infratentorial locations, and exclusively deep venous drainage. Previous rupture, large AVM size, and infratentorial and deep locations were independent risk factors according to multivariate models.

Jae H Choi et al[42]; studied on morbidity from spontaneous haemorrhage of untreated brain Arteriovenous malformation. In a group of 241 consecutive AVM patients from prospective Columbia AVM data bank Initially presenting with haemorrhage in comparison to 84 non –AVM patients with intracerebral haemorrhage from Northern Manhattan Study [NOMAS ] served as control group, it was concluded that Haemorrhage either at initial presentation or during follow up of untreated AVM's carried lower morbidity than intracranial hemorrhages from other causes.

Retrospective evaluation of outcomes in 46 unruptured AVM's & rate for bleeding during the follow up period was done by Uno masaki et al[28]. In 18 of 22 patients in grade I & II AVM's were surgically excised and the outcome was good. Six of 9 patients in grade IV & V were conservatively treated. For patients in grade III various treatments were performed according to the location of the AVM, and their outcomes were favourable. Rate of surgical complication was 15.3 % in 26 unruptured AVM's. Based on this data they concluded to

aggressively treat patients with grade I & grade II.[uno masaki et.al]

Crawford P M et al[7] studied on unoperated AVM's with a mean follow up of 10.4 years. They concluded That there was a 42% risk of haemorrhage, 18% risk of epilepsy & 27% risk of neurological deficits by 20 years after diagnosis in unoperated patients.

**Conclusion**

The behaviour of brain arteriovenous malformations (AVMs) remains difficult to predict. Host, environmental, and gene susceptibility factors may influence the clinical manifestation. The complication with the most significant clinical sequelae is intracranial haemorrhage.

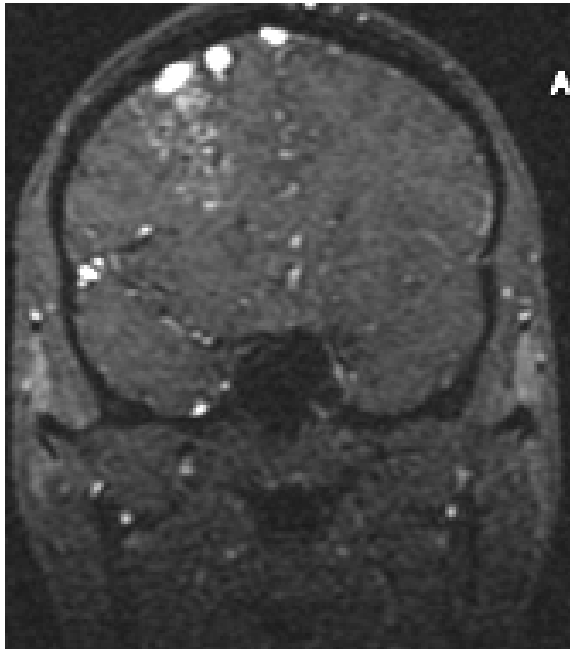


Figure 1 A

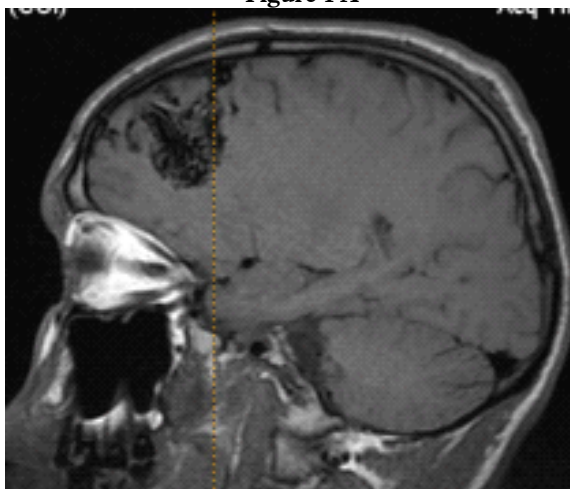


Figure 1 B

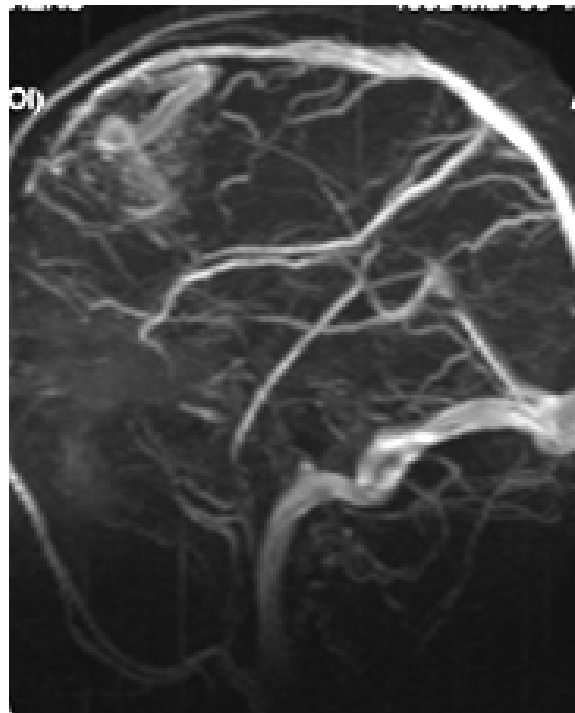


Figure 1 C

Figure 1 MRI and angiography of a patient with of unruptured right frontal arteriovenous malformation (from Emergency Hospital “Prof Dr N Oblu” Iasi, Romania, Dr N Dobrin’s collection)

Slowly accumulating data suggest that once the process of bleeding starts, the lesion appears to become destabilized and susceptible to more bleeding [23,24]. Therefore, the indication for treatment of ruptured AVM's is generally not under dispute. Unruptured AVM's Whatever the treatment technique, the crude



proportion of treatment-associated morbidity usually ranges around 10% in the most recent reports, but this seems acceptable given the persistent risk of potentially devastating bleeding from an untreated AVM. When it comes to unruptured brain AVM's, however, the long-assumed benefit of interventional therapy seems to have become less clear. Current natural history data from the Columbia AVM Database, the UCSF AVM Study project, and the Scottish Intracranial Vascular Malformation Study suggest the annual risk of spontaneous haemorrhage may be as low as 1% for unruptured AVM's [25,26]. In addition, the growing availability of MR imaging has led to a substantial increase in the incidental detection of unruptured malformations ranging between 54% and 62% of all diagnosed AVM's in modern population-based data-sets [25,26]. In the light of these figures, neurovascular teams face the clinical dilemma of how to balance the inherent risk of intervention against the potentially low haemorrhage rates in patients harbouring an unruptured brain AVM[5] These figures raise concern that invasive treatment may be connected with an unfavourable benefit vs. risk ratio to the degree that some have become reluctant to recommend interventional therapy for many patients presenting with an unruptured AVM. Evidence-based guidelines give non intervention as one option in AVM management [27]. Although current clinical practice favours intervention in most patients, some clinicians understandably prefer to undertake intervention in specific

subgroups of patients who are likely to benefit from the intervention. Besides haemorrhagic presentation, predictors of AVM haemorrhage during natural history follow-up include increasing age, deep brain location, associated aneurysms, and exclusive deep venous drainage [5,10]. By contrast, the risk of spontaneous haemorrhage may drop below 1% per year in AVM's without these risk factors [24]. These characteristics may guide the neurovascular team during case assessment and patient counselling, but the fact that the same factors not only increase the natural history risk but also the hazard of intervention, clearly adds to the complexity. Careful explanation and sufficient time is given to patients as be the need, because they are often otherwise healthy young adults who are actively involved in their working and family life.

Although data from randomised trials to guide the choice of treatment are lacking, surgical resection, radiosurgery, embolisation, or a combination of these is appropriate for AVM's that are grade I to III. The choice of treatment will depend on the specific features of the lesion, with consideration of the, age of the patient, presence or absence of bleeding and associated aneurysm, diameter and location of associated aneurysms, and pattern of venous drainage. Grade I and grade II surgery is recommended and consideration of endovascular embolisation followed by microsurgery is recommended for grade III [27]. Consideration of radio surgery is recommended for lesions that may be associated with an increased risk of surgical complications, owing to their

anatomical location or feeding vessel anatomy, in particular for lesions in the eloquent area. Grade IV and grade V lesions palliate treatment is suggested for lesions with intranidal or arterial aneurysms or progressive neurological deficits related to vascular steal[32]. Complete treatment is recommended for patients with progressive neurological deficits caused by haemorrhage of the AVM. [Because of the risks of treatment, Grade IV and Grade V lesions are generally not treated. American stroke association recommendation-2001].

Lacking randomized studies on AVM treatment, there is considerable uncertainty in the existing clinical literature on indications for invasive treatment in these patients. The best way to address the issue is a randomized clinical trial. The currently launched A Randomized Trial of Unruptured Brain AVMs (ARUBA) is a randomized, multicenter, international trial comparing outcome of invasive AVM treatment with conservative management in patients with unbled AVM's.

ARUBA is investigating whether treatment for consenting adults aged  $\geq 18$  years, with an unruptured brain AVM that is potentially treatable, over a minimum follow up period of five years, based on outcome assessments by treating physicians. We will have to wait for fresh data from this study for enhancing our knowledge on management of unruptured AVM's for serving mankind.

## References

1. Brown RD jr MD, Kelly.D.Fleming MD. Natural history & management of intracranial vascular malformations Mayo clinic proc Feb 2005;80[2]; 269-281
2. McCormick WF. Pathology of vascular malformations of the brain. In: Wilson CB, Stein BM, eds. Intracranial Arteriovenous Malformations. Baltimore, Md: Williams & Wilkins; 1984:44-63.
3. Brown RD Jr, Wiebers DO, Torner JC, O'Fallon WM. Incidence and prevalence of intracranial vascular malformations in Olmsted County, Minnesota, 1965 to 1992. *Neurology*. 1996;46:949-952.
4. Kucharczyk W, Lemme-Pleghos L, Uske A, Brant-Zawadzki M, Doooms G, Norman D. Intracranial vascular malformations: MR and CT imaging. *Radiology*. 1985;156:383-389.
5. Brown RD Jr, Wiebers DO, Forbes G, et al. The natural history of unruptured intracranial arteriovenous malformations. *J Neurosurg*. 1988;68: 352-357.
6. Wilkins RH. Natural history of intracranial vascular malformations: a review. *Neurosurgery*. 1985;16:421-430.
7. Crawford PM, West CR, Chadwick DW, Shaw MD. Arteriovenous malformations of the brain: natural history in unoperated patients. *J Neurol Neurosurg Psychiatry*. 1986;49:1-10.
8. Graf CJ, Perret GE, Torner JC. Bleeding from cerebral arteriovenous malformations as part of their natural history. *J Neurosurg*. 1983;58:331-337.
9. Ondra SL, Troupp H, George ED, Schwab K. The natural history of symptomatic arteriovenous malformations of the brain: a 24-year follow-up assessment. *J Neurosurg*. 1990;73:387-391.
10. Mast H, Young WL, Koennecke HC, et al. Risk of spontaneous haemorrhage after diagnosis of cerebral arteriovenous malformation. *Lancet*. 1997;350:1065-1068.
11. Kondziolka D, McLaughlin MR, Kestle JR. Simple risk predictions for arteriovenous malformation hemorrhage. *Neurosurgery*. 1995;37:851-855.
12. Forster DM, Steiner L, Hakanson S. Arteriovenous malformations of the brain: a long-term clinical study. *J Neurosurg*. 1972;37:562-570.
13. Hartmann A, Mast H, Mohr JP, et al. Morbidity of intracranial hemorrhage in patients with cerebral arteriovenous malformation. *Stroke*. 1998;29:93
14. Miyasaka Y, Yada K, Ohwada T, Kitahara T, Kurata A, Irikura K. An analysis of the venous drainage system as a factor in hemorrhage from arteriovenous malformations. *J Neurosurg*. 1992;76:239-243.
15. Kader A, Young WL, Pile-Spellman J, et al. The influence of hemodynamic and anatomic factors on hemorrhage from cerebral arteriovenous malformations. *Neurosurgery*. 1994;34:801-80

16. Batjer H, Samson D. Arteriovenous malformations of the posterior fossa: clinical presentation, diagnostic evaluation, and surgical treatment. *J Neurosurg.* 1986;64:849-856.
17. Drake CG. Cerebral arteriovenous malformations: considerations for and experience with surgical treatment in 166 cases. *Clin Neurosurg.* 1979;26:145-208.
18. Heros RC, Korosue K, Diebold PM. Surgical excision of cerebral arteriovenous malformations: late results. *Neurosurgery.* 1990;26:570-577.
19. Sundt TM Jr, Piepgras DG, Stevens LN. Surgery for supratentorial arteriovenous malformations. *Clin Neurosurg.* 1991;37:49-115.
20. Spetzler RF, Martin NA. A proposed grading system for arteriovenous malformations. *J Neurosurg.* 1986;65:476-483.
21. Hamilton MG, Spetzler RF. The prospective application of a grading system for arteriovenous malformations. *Neurosurgery.* 1994;34:2-6.
22. McLaughlin MR, Kondziolka D, Flickinger JC, Lunsford S, Lunsford LD. The prospective natural history of cerebral venous malformations. *Neurosurgery.* 1998;43:195-200.
23. Graf CJ, Perret GE, Torner JC (1983) Bleeding from cerebral arteriovenous malformations as part of their natural history. *J Neurosurg* 58:331-337
24. Stapf C, Mast H, Sciacca RR et al (2006) Predictors of hemorrhage in patients with untreated brain arteriovenous malformation. *Neurology* 66:1350-1355
25. Al-Shahi R, Bhattacharya JJ, Currie DG et al (2003) Prospective, population-based detection of intracranial vascular malformations in adults: the Scottish Intracranial Vascular Malformation Study (SIVMS). *Stroke* 34:1163-1169
26. Stapf C, Mast H, Sciacca RR et al (2003) The New York Islands AVM Study: design, study progress, and initial results. *Stroke* 34: e29-33
27. Ogilvy CS, Stieg PE, Awad I et al (2001) Recommendations for the management of intracranial arteriovenous malformations: a statement for healthcare professionals from a special writing group of the Stroke Council, American Stroke Association. *Circulation* 103:264
28. Uno masaki. et al *journal of surgery for cerebral stroke* vol 34 (3) 157-162 2006
29. Stiver, Shirley I. *Neurosurgery* vol 46(14);811-819 april 2000
30. Harbaugh, Kumberly S et al. *Neurosurgery* vol34 (4) 1994.
31. Stefani M A, Porter PJ, et al Large and deepbrain Arteriovenous malformations are associated with risk of future haemorrhage. *Stroke* 2002;33:1220-1224.
32. Han PP, Ponce FA Spetzler RF. Intention to treat analysis of Spetzler -Martin grade IV- and V Arteriovenous malformations: Natural history and treatment paradigm. *J Neurosurgery* 2003;98: 3-7
33. Fleetwood IG, Marcellus ML et al. Deep arteriovenous malformations of the basal ganglia and thalamus: natural history. *J Neurosurgery* 2003 ;98 :747-750
34. Mohr JP, Stapf C, Sciacca RR, et al.: Treatment outcome versus natural history risk in patients with unruptured brain arteriovenous malformation [abstract]. *Neurology* 2004
35. Achrol AS, Pawlikowska L, McCulloch CE, et al.: Tumor necrosis factor-alpha-238G>A promoter polymorphism is associated with increased risk of new hemorrhage in the natural course of patients with brain Arteriovenous malformations. *Stroke* 2006, 37:231-234.
36. Chen Y, Pawlikowska L, Yao JS, et al.: Interleukin-6 involvement in brain arteriovenous malformations. *Ann Neurol* 2006, 59:72-80.
37. Hashimoto T, Wen G, Lawton MT, et al.: Abnormal expression of matrix metalloproteinases and tissue inhibitors of metalloproteinases in brain Arteriovenous malformations. *Stroke* 2003, 34:925-931
38. Yamada S, Takagi Y et al Risk factors for subsequent haemorrhage in patients with cerebral Arteriovenous malformations *J Neurosurgery* 2007;107:965-972
39. Han PP, Spetzler R F et al, Intention to treat analysis of Spetzler -Martin grade IV & grade V AVM *J Neurosurgery* 2003 ;98: 3-7
40. Hartman A, Mast H, Stapf et al Treatment of AVM of brain. *Curr Neurol Rep* 2007;7:28-34
41. Jayaraman M V, Marcellus ML, et al Haemorrhage rate in Spetzler Martin grade IV - grade V Arteriovenous malformation: is treatment justified *Stroke* 2007 ;38:325-329.
42. Choi J H Mast H, et al clinical outcome after first & recurrent haemorrhage in patients with untreated brain Arteriovenous malformations. *Stroke* 2006 ;37:1243-1247.
43. Mansmann U, Meisel J, Brock M, et al.: Factors associated with intracranial hemorrhage cases of cerebral Arteriovenous malformation. *Neurosurgery* 2000, 46:272-279.
44. Osipov A, Koennecke HC, Hartmann A, et al.: Seizures in cerebral arteriovenous malformations. Type, clinical course, and medical management. *Intervent Neuroradiol* 1997, 3:37-41.
45. Mast H, Mohr JP, Osipov A, et al.: 'Steal' is an unestablished mechanism for the clinical presentation of cerebral arteriovenous malformations. *Stroke* 1995, 26:1215-1220.

46. Turjman F, Massoud, TF, Vineula F et al Correlation of angioarchitectural features of cerebral Arteriovenous malformations with clinical presentation of haemorrhage. *Neurosurgery*, 1995; 37:856-60.
47. Robert M Friedlander Arteriovenous malformations of the brain *N eng journal of med* 356;26:2704- 2711.
48. Leodante da Costa, M Christopher Wallace et al The natural history & predictive features of haemorrhage of brain arteriovenous malformations. *Stroke* 2009; 40:100-105
49. Marco. A. Stefani, Philip. J. Porter et al Natural history & predictive features of haemorrhage of brain Arteriovenous malformations *Stroke* 2002; 33:1220-1224.
50. J. Hernesniemi et al Natural history of brain Arteriovenous malformations. *Neurosurgery*. vol 63;5: nov 2008.
51. Hofmeister C, Stapf C, Hartmann A, et al.: Demographic, morphological, and clinical characteristics of 1289 patients with brain arteriovenous malformation. *Stroke* 2000 31:1307-1310
52. Osipov A, Koennecke HC, Hartmann A, et al.: Seizures in cerebral arteriovenous malformations. Type, clinical course, and medical management. *Intervent Neuroradiol* 1997, 3:37-41.
53. Schauble B, Cascino GD, Pollock BE, et al.: Seizure outcomes after stereotactic radiosurgery for cerebral Arteriovenous malformations. *Neurology* 2004, 63:683-687.