

ROMANIAN
NEUROSURGERY

Vol. XXXVI | No. 2 June 2022

Multimodal treatment of glomus jugular
tumours. Case series and literature
review

F. Stoica,
G. Popescu,
Francesca Paslaru,
Anamaria Gheorghiu,
A.C. Paslaru,
M. Apostol,
M.C. Zaharia,
R.M. Gorgan



Multimodal treatment of glomus jugular tumours. Case series and literature review

F. Stoica¹, G. Popescu¹, Francesca Paslaru¹, Anamaria Gheorghiu¹,
A.C. Paslaru^{2,3}, M. Apostol¹, M.C. Zaharia¹, R. M. Gorgan^{1,2}

¹ 4th Neurosurgical Department, "Bagdasar Arseni" Clinical
Emergency Hospital, Bucharest, ROMANIA

² "Carol Davila" University of Medicine and Pharmacy, Bucharest,
ROMANIA

³ Department of Genetics, "Dr Victor Gomoiu" Children's Clinical
Hospital, Bucharest, ROMANIA

ABSTRACT

Glomus jugulare tumours are extremely rare, slow-growing, hypervascular tumours that arise within the jugular foramen of the temporal bone and frequently involve the lower cranial nerves. We performed a retrospective study for patients treated between January 2005 and December 2019, reviewing clinical and radiological data for 91 cases of glomus jugulare tumours. Data were available for 91 patients presenting with 96 tumours. Surgery was 1st intention of treatment for 13 cases, the endovascular approach was 1st intention for 6 cases and GKRS was primarily performed in 72 cases. Combined treatment options were used in 19 cases. The median age at the time of treatment was of 57 years. The tumour volume varied between 0.5 and 73.4 cm³ with a median value of 8.3 cm³. For the cases treated with GKRS, the peripheral dose ranged between 8 and 35 Gy on the 35% to 65% isodose, with a median of 14 Gy on the 45% isodose. The average follow-up was 38 months with a maximum of 94 and consisted of contrast-enhanced MRI every six months in the first year after the procedure and every 1 to 2 years afterwards. The overall tumour control rate was 95.6% using multimodal treatment options for glomus jugulare tumours. Multimodal treatment for glomus jugulare tumours offers the patient the chance for the best possible outcome and long-term survivability. An individual treatment approach for this kind of very rare head and neck tumour (0,6% of all head and neck tumours) is recommended to choose the best risk-versus-benefit treatment option.

BACKGROUND

Glomus jugulare tumor is a benign neuroendocrine tumor that arises from the jugular foramen. This tumor characterized by a slow-growing pattern. Paragangliomas, also known as chemodectomas represent benign tumors with the origin from neural crest derivatives also known as the paraganglia^{[1],[2],[3]}. These tumors are highly vascularised. They can receive blood supply from both from the external carotid artery and internal carotid artery. The localization of these tumours can widely

Keywords

tumour,
glomus,
jugular



Corresponding author:
G. Popescu

4th Neurosurgical Department,
"Bagdasar Arseni" Clinical
Emergency Hospital, Bucharest,
Romania

george_popescu39@yahoo.com

Copyright and usage. This is an Open Access article, distributed under the terms of the Creative Commons Attribution Non-Commercial No Derivatives License (<https://creativecommons.org/licenses/by-nc-nd/4.0/>) which permits non-commercial re-use, distribution, and reproduction in any medium, provided the original work is unaltered and is properly cited. The written permission of the Romanian Society of Neurosurgery must be obtained for commercial re-use or in order to create a derivative work.

ISSN online 2344-4959
© Romanian Society of
Neurosurgery



First published
June 2022 by
London Academic Publishing
www.lapub.co.uk

vary, from carotid bifurcation to the auricular branch of the vagus nerve. The most frequent localization is the carotid body, accounting for almost half of the tumors [5], [6] whereas glomus jugulare tumors represent 24% of them [6]. Even though they are benign tumors, the symptomatology can be the cause of the mass effect [2].

Usually, these tumors are diagnosed in the fourth to sixth decade of life, with a moderate female predilection. Most of the glomus jugulare tumors are isolated lesions but around 20% of them present hereditary components [4]. The inherited tumors are usually bilateral and the onset of the symptoms is reported to be earlier than the onset symptomatology of the sporadic tumors. The reported malignancy of these tumors is less than 5% [2].

Around 25% of the paragangliomas remain silent and are incidentally discovered. The symptoms caused by these tumors depend on their location. Lower cranial nerves impairment is reported in more than 10% of patients [8]. The most common neurological deficits reported are tongue deviation, hoarseness, facial palsy, dysphagia, and shoulder weakness [2],[7],[8]. Additionally, patterns of cranial nerve palsies were described and these include [12]:

- Vernet syndrome that represents motor paralysis of cranial nerves IX, X and XI; [9]
- Collet- Sicard syndrome described as the palsy of cranial nerves IX,X,XI and XII; [10]
- Horner syndrome - oculosympathetic palsy. [11]

Due to its slow-growing pattern and the complex anatomy of the skull base and neck, observation of the patient is considered a good treatment alternative. In more than 60% of the cases, tumor volume remains stable or decrease in size [14]. However, if the tumor tends to be symptomatic, surgical excision or stereotactic radiosurgery will be take into account.

CASE SERIES

We performed a retrospective study for patients treated between January 2005 and December 2019, reviewing clinical and radiological data for 91 cases of glomus jugulare tumors. Data were available for 91 patients presenting with 96 tumors.

Surgery was the treatment of choice for 13 cases, endovascular embolization was performed as first intention treatment for 6 cases and GKRS was primarily performed in 72 cases.

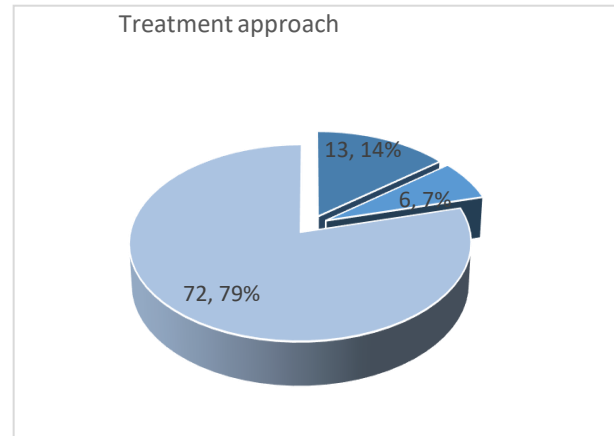


Figure 1. Distribution of the treatment option

Combined treatment options were used in 19 cases (1 surgery with GKRS, 18 endovascular with GKRS). 44 glomus jugulare tumors were identified on the right side, and 47 on the left side. In the study group, we had 23 male patients and 63 female patients. 11 patients were in the 15-39 age group while 80 patients were older than 40 yrs. The median age at the time of treatment was of 57 years. The tumor volume varied between 0.5 and 73.4 cm³ with a median value of 8.3 cm.

For the cases treated with GKRS, the peripheral dose ranged between 8 and 20 Gy on the 35% to 65% isodose, with a median of 14 Gy on the 45% isodose. The average follow-up was 38 months with a maximum of 94 and consisted of contrast-enhanced MRI every six months in the first year after the procedure and every 1 to 2 years afterward. Overall tumor control rate was 95.6% using multimodal treatment options for glomus jugulare tumors.

Table 1. Most common comorbidities

COMORBIDITY
Lower cranial nerves deficits
Dizziness
Tinnitus
Hearing impairment
Hemorrhages
Hydrocephalus
Hemiparesis

Comorbidities were noted in 37 patients (40.6%) and consisted of lower cranial nerves deficits (26.4%), dizziness, tinnitus, partial or complete hearing loss in 21.9% of cases, 2 hemorrhages, 2 secondary hydrocephalus, and 1 hemiparesis. 23 patients (24.3%) presented recurrences: 13 after surgery, 6 after embolization, and 4 after GKRS. However, the mortality rate was 0.

CASE 1

The first case is represented by a female patient of 53 years old, whose symptoms are vertigo, hearing loss, and pulsating tinnitus. Soon it is discovered the typical aspect of "salt and pepper" for a glomus tumor with temporal localization, millimetric extracranial extension into jugular vein lumen and damage to the structures of the inner ear. 9 years after GKRS, a cerebral MRI was performed, which showed that the irradiated tumor volume has been reduced in circumferential dimensions, with a homogeneous intake of contrast substance ("densified" appearance due to sclerosis and obliteration of intratumoral blood vessels) without adverse reactions due to irradiation. No new neurological deficits were recorded after GKRS.

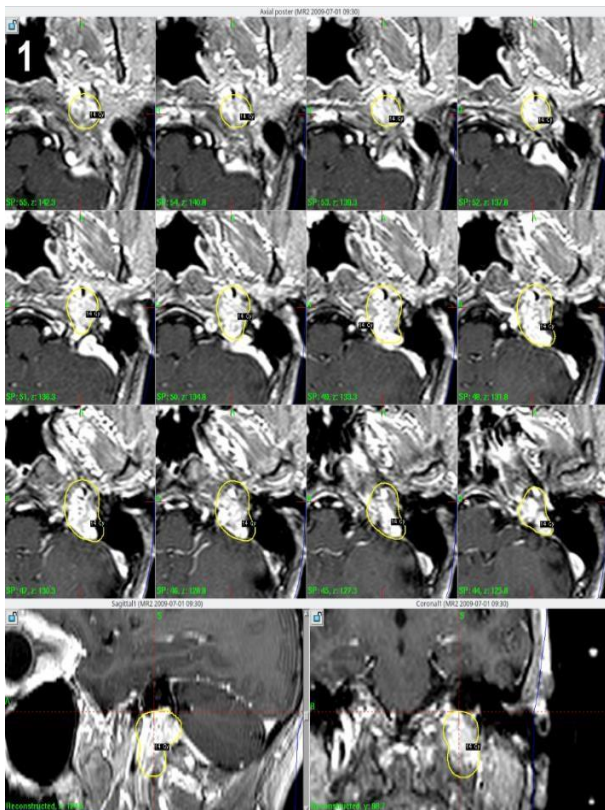


Figure 2. Preoperative aspect of the tumour

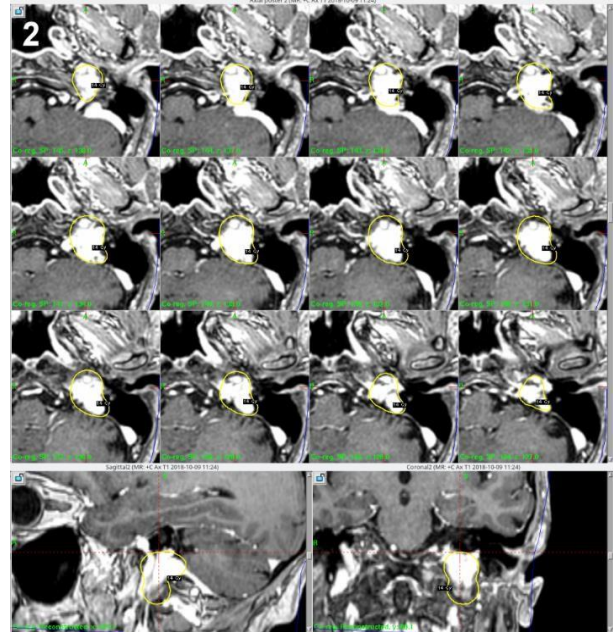


Figure 3. Postoperative aspect after Gamma Knife Radiosurgery

CASE 2

The second case is represented by a 62 years old female patient, whose symptoms onset with injury to multiple cranial nerves (VII, VIII, IX, XI, XII). The diagnosis was represented by a large glomus tumor with an important intracranial component with a mass effect on the brainstem.

A cerebral MRI was performed 4 years post GKRS, showing a marked reduction in the size of the irradiated tumor, especially in the intracranial component, with a significant decrease in the mass effect, without perilesional reactive edema.

No new neurological deficits were recorded. 18 months after irradiation, a complete remission of facial paresis has been noticed and other cranial nerves neurological status remained stationary.

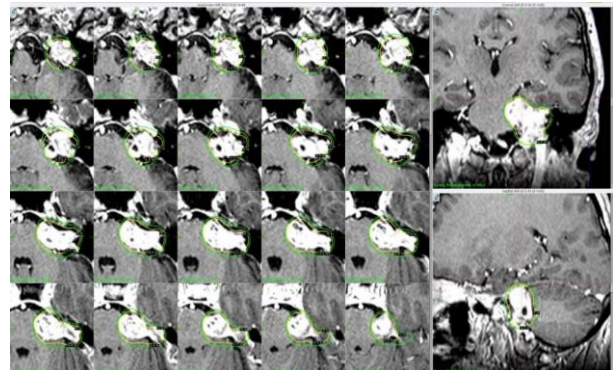


Figure 4. Preoperative aspect of the tumour




Figure 5. Postoperative aspect after Gamma Knife Radiosurgery

CASE 3

For the third case, we have a 35 years old male patient, who presented with glomus tumor located in the temporal bone, onset with hearing disorders (hearing loss and pulsating tinnitus).

6 years after GKRS, a periodic follow-up MRI has been performed. the inferior recurrence in the lumen of the jugular vein was identified outside the irradiation field with a volume of 4.6 cm³, asymptomatic. The decision is made in order to irradiate the recurrence with 14 Gy on 47% isodose.

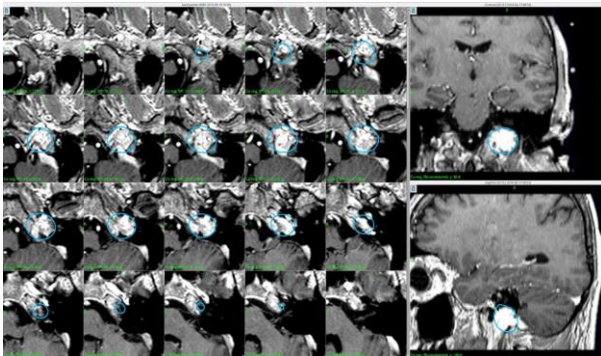


Figure 6. Preoperative aspect before Gamma Knife Radiosurgery

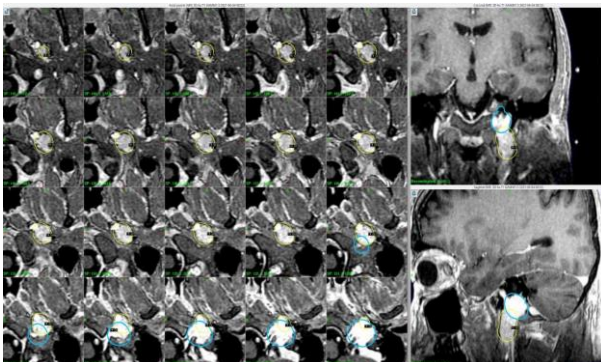


Figure 7. The recurrence aspect, 6 years after GKRS

DISCUSSIONS

The best treatment option for glomus jugulare tumors is yet to be debated. Due to their localization, surgical treatment does not represent the gold standard because of the complex anatomy of the region, high rates of morbidity, subtotal resection, and the alternative behavior of the tumors that could be very aggressive in some cases. In 2003, Roberto Pareschi et al [15] described their experience in the surgical treatment of glomus jugulare tumors. 42 patients with glomus jugulare tumors were identified, 3 of them previously undergone surgery for this pathology, and 3 patients presented bilateral temporal lesions. The otoscopic evaluation revealed in 80% of the patients the typical red middle ear mass. 70% of the cases had no preoperative cranial nerve deficit. 37 seven patients were elected for surgical intervention. In 33 cases, infratemporal fossa approaches were used and in 4 cases, conservative jugulopetrosectomy was performed, in order to preserve the facial nerve. In 20% of the cases, cranial nerves IX and X were injured. No recurrence after total resection was reported. An extensive dissection of the posterolateral skull base is required for surgery of glomus jugulare tumors [15]. Even though cranial nerve preservation is an extremely important goal in the surgical approach, in 22% of the cases facial nerve is sacrificed [15]. The authors concluded that the focus should drift away from total resection to increasing the quality of life of the patient, a philosophy that our clinic shares. Only 14% percent of our cases were surgically treated, in order to avoid the decrease in the quality of patient's life.

Endovascular treatment is an alternative treatment approach for patients with glomus jugulare tumors. In 2017, Kocur et al [17] presented their experience and the outcome of embolization in 3 cases of glomus jugulare tumors. They described the technical difficulty of achieving complete obliteration of the glomus jugulare tumors and concluded that increased risk of revascularization is not beneficial compared to the diminished clinical symptoms. In our clinic, only 6 endovascular treatments were performed.

A promising approach for this pathology is represented by radiosurgery. Due to the high degree of accuracy, rapid radiation dose falloff at the periphery of the target tumor, and their high precision, radiosurgery became a popular treatment

choice. In their meta-analysis, Guss et al [13] included 19 studies, compounding 335 glomus jugulare patients. They reported a reduced or unchanged tumoral volume after radiosurgery, sustained by imagistic findings. Clinical control was reported as improved or unchanged after radiosurgery in 95% of the cases. The authors emphasized the effectiveness of this treatment option. In our clinic, 72 patients benefited from radiosurgery.

CONCLUSIONS

Multimodal treatment for glomus jugulare tumors offers the patient the chance for the best possible outcome and long-term survivability. Individual treatment approach for this kind of very rare head and neck tumor (0,6% of all head and neck tumors) is recommended to choose the best risk-versus-benefit treatment option. GKRS in these kinds of tumors seems to be the option of choice, considering that in our experience, has the lowest comorbidity, recurrence rate and mortality.

REFERENCES

1. Fussey JM, Kemeny AA, Sankar S, Rejali D. Successful management of a catecholamine- secreting glomus jugulare tumor with radiosurgery alone. *J Neurol Surg B Skull Base*. 2013 Dec;74(6):399-402.
2. Ramina R, Maniglia JJ, Fernandes YB, Paschoal JR, Pfeilsticker LN, Neto MC, Borges G. Jugular foramen tumors: diagnosis and treatment. *Neurosurg Focus*. 2004 Aug 15;17(2):E5.
3. Petropoulos AE, Luetje CM, Camarata PJ, Whittaker CK, Lee G, Baysal BE. Genetic analysis in the diagnosis of familial paragangliomas. *Laryngoscope*. 2000 Jul;110(7):1225-9.
4. Semaan MT, Megerian CA. Current assessment and management of glomus tumors. *Curr Opin Otolaryngol Head Neck Surg*. 2008 Oct;16(5):420-6.
5. Tokgöz SA, Saylam G, Bayir Ö, Keseroğlu K, Toptaş G, Çadallı Tatar E, Akın İ, Korkmaz MH. Glomus tumors of the head and neck: thirteen years' institutional experience and management. *Acta Otolaryngol*. 2019 Oct;139(10):930-933.
6. Singh S, Madan R, Singh MK, Thakar A, Sharma SC. Head-and-neck paragangliomas: An overview of 54 cases operated at a tertiary care center. *South Asian J Cancer*. 2019 Oct- Dec;8(4):237-240.
7. Wanna GB, Sweeney AD, Haynes DS, Carlson ML. Contemporary management of jugular paragangliomas. *Otolaryngol Clin North Am*. 2015 Apr;48(2):331-41.
8. Jackson CG, Harris PF, Glasscock ME, Fritsch M, Dimitrov E, Johnson GD, Poe DS. Diagnosis and management of paragangliomas of the skull base. *Am J Surg*. 1990 Apr;159(4):389-93.
9. Monteiro, F., Oliveira, P., Peneda, J. and Condé, A., 2019. Vernet syndrome: intracranial extension of a slow-growing mass. *BMJ Case Reports CP*, 12(5), p.e228039.
10. Neo S, Lee KE. Collet-Sicard syndrome: a rare but important presentation of internal jugular vein thrombosis. *Practical Neurology*. 2017 Feb 1;17(1):63-5.
11. Spector GJ, Druck NS, Gado M. Neurologic manifestations of glomus tumors in the head and neck. *Archives of Neurology*. 1976 Apr 1;33(4):270-4.
12. Spector GJ, Gado M, Ciralsky R, Ogura JH, Maisel RH. Neurologic implications of glomus tumors in the head and neck. *The Laryngoscope*. 1975 Aug;85(8):1387-95.
13. Guss ZD, Batra S, Limb CJ, Li G, Sughrue ME, Redmond K, Rigamonti D, Parsa AT, Chang S, Kleinberg L, Lim M. Radiosurgery of glomus jugulare tumors: a meta-analysis. *International Journal of Radiation Oncology* Biology* Physics*. 2011 Nov 15;81(4):e497-502.
14. Prasad SC, Mimoune HA, D'Orazio F, Medina M, Bacciu A, Mariani-Costantini R, Piazza P, Sanna M. The role of wait-and-scan and the efficacy of radiotherapy in the treatment of temporal bone paragangliomas. *Otol Neurotol*. 2014 Jun;35(5):922-31.
15. Pareschi R, Righini S, Destito D, Raucci AF, Colombo S. Surgery of glomus jugulare tumors. *Skull Base*. 2003 Aug;13(03):149-58.
16. Kocur D, Ślusarczyk W, Przybyłko N, Hofman M, Jamróz T, Suszyński K, Baron J, Kwiek S. Endovascular approach to glomus jugulare tumors. *Polish journal of radiology*. 2017;82:322.