

ROMANIAN
NEUROSURGERY

Vol. XXXV | No. 2 June 2021

The use of corticosteroids in
autoimmune encephalitis.
Basic and clinical considerations

Bryan Lester Nahar-González,
Ivan David Lozada-Martinez,
Yandris Arevalo-Martínez,
Loraine Quintana-Pajaro,
Silvia Prada-Soto,
Teresa Pacheco-Hernandez,
William Florez-Perdomo,
Yelson Alejandro Picón-Jaimes,
Luis Rafael Moscote-Salazar



The use of corticosteroids in autoimmune encephalitis. Basic and clinical considerations

B.L. Nahar-González¹, I.D. Lozada-Martinez^{2,3,4}, Y. Arevalo-Martínez⁵, L. Quintana-Pajaro^{3,5}, S. Prada-Soto⁶, T. Pacheco-Hernandez², W. Florez-Perdomo³, Y.A. Picón-Jaimes⁷, L.R. Moscote-Salazar^{2,3,4}

¹ Medical and Surgical Research Center, New Jersey, USA

² Medical and Surgical Research Center, University of Cartagena, COLOMBIA

³ Colombian Clinical Research Group in Neurocritical Care, University of Cartagena, COLOMBIA

⁴ Latin American Council of Neurocritical Care, Cartagena, COLOMBIA

⁵ Center for Biomedical Research, University of Cartagena, COLOMBIA

⁶ Medical and Surgical Research Center, Atlanta, USA

⁷ Medical and Surgical Research Center, Valencian International University, CHILE

ABSTRACT

Autoimmune encephalitis (AE) is a brain inflammation caused by autoantibodies that target proteins, intracellular and extracellular antigens, triggering damage in the CNS; AE is classified in various syndromes caused by various antibodies, It is a diagnosis of exclusion. Therefore, it has to be differentiated from multiple causes that could unleash encephalitis. However, its treatment is based primarily on immunotherapy, where corticosteroids as immunosuppressive agents, play a key role in the treatment along with other agents.

INTRODUCTION

The immune system, under certain pathophysiological conditions, is capable of producing antibodies against cells, tissues, or organs, triggering known autoimmune diseases [1]. These reactions are often expressed in the central nervous system, for example, autoimmune encephalitis (AD), which is a brain inflammation due to the presence of freely circulating autoantibodies that affect nerve cells [2]. The advent of technologies that have allowed the detection of antibody subtypes, has modified the classification of autoimmune encephalitis, substantially improving the diagnosis, management, and prognosis of these patients [1,2]. However, one of the current challenges consists of

Keywords
encephalitis.
autoimmunity.
autoantibodies.
corticosteroids



Corresponding author:
Ivan David Lozada-Martínez

Medical and Surgical Research
Center, University of Cartagena,
Colombia

ilozadam@unicartagena.edu.co

Copyright and usage. This is an Open Access article, distributed under the terms of the Creative Commons Attribution Non-Commercial No Derivatives License (<https://creativecommons.org/licenses/by-nc-nd/4.0/>) which permits non-commercial re-use, distribution, and reproduction in any medium, provided the original work is unaltered and is properly cited. The written permission of the Romanian Society of Neurosurgery must be obtained for commercial re-use or in order to create a derivative work.

ISSN online 2344-4959
© Romanian Society of
Neurosurgery



First published
June 2021 by
London Academic Publishing
www.lapub.co.uk

as in early diagnosis and management in low-level hospital institutions, which do not have laboratories or specialized equipment that facilitate this type of exam, so the approach in these cases is general, frequently with the isolated use of corticosteroids [3]. Based on the above, the objective of this manuscript is to present evidence on the role of corticosteroids in the treatment of autoimmune encephalitis, highlighting basic and clinical aspects that translate their understanding and usefulness.

PATHOGENESIS OF AUTOIMMUNE ENCEPHALITIS

AD is brain inflammation produced by the action of autoantibodies directed against cell surface proteins, intracellular and intracellular antigens [2,4]. Various processes such as paraneoplastic syndromes, molecular mimicry, vaccines, or failure of immune tolerance, might trigger the production of autoantibodies against specific antigens that cause disease [1,4]. For this reason, the identification of autoantibodies constitutes a fundamental step to understand the pathophysiological mechanism of autoimmune encephalitis, its complete understanding will allow choosing the appropriate diagnostic tests and treatment [1,4].

Autoimmune encephalitis is classified taking into account the pathophysiological mechanism that produces it (Figure 1). For this reason, the pathogenesis will be addressed, considering grouping antibodies according to the location of their antigens [5-7].

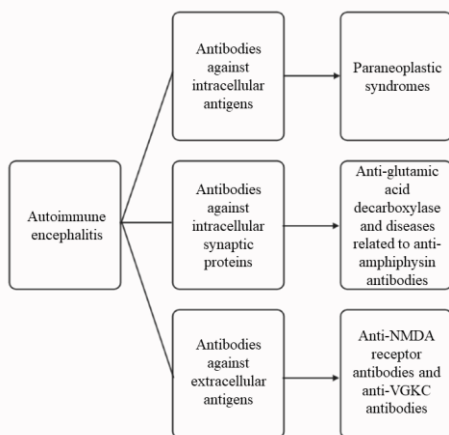


Figure 1. Autoimmune encephalitis classification according to the pathogenetic mechanism [2,4,6,7].

Paraneoplastic syndromes, in which antibodies "Anti-Hu" are directed against intracellular antigens,

primarily tissue such as temporal lobe, cerebellum, brainstem, dorsal roots, and autonomic nervous system [8-9]. In other autoimmune systemic syndromes such as Systemic Lupus Erythematosus, where there are antibodies against phosphorylated ribosomal P proteins, neurological and/or psychiatric manifestations may occur, such as psychosis, with a positive correlation between antibody levels and severity of symptoms [10,11].

The binding of antibodies to antigens, whether at the intracellular or extracellular level, causes alteration of synaptic interactions and prevents the expression of these receptors; if this happens for a long time, irreversible damage to the central nervous system could be generated [12].

CLINICAL MANIFESTATIONS

AD has a wide clinical spectrum in which they can be found from the typical encephalitis with involvement of the limbic system, to complex neuropsychiatric symptoms. These symptoms are related to the type of antibody and the antigen to which it is directed (Table 1) [1,2,5].

Antigen	Manifestations
NMDA	Psychosis, dystonia, chorea, epilepsy, cognitive impairment, dysautonomia
AMPA	Psychosis, limbic encephalitis, aggressiveness, hallucinations, sleep disorders
GAD 65	Stiff Man syndrome, DM1, cerebellitis
ANNA 1	Cerebellitis
GABA	Psychosis, epilepsy
Caspr2	Neuromyotonia, muscle spasm, fasciculations, insomnia, hallucinations

Table 1. Clinical manifestations related to the type of antigen [2,5].

Symptoms despite being variables, in most adolescents and adults evolve in stages, initially, the symptoms may appear similar to a viral infection in which headache and fever are the most common. Later, between days and weeks, neuropsychiatric

symptoms are triggered. These may include psychosis, euphoria, aggression, inappropriate sexual behaviors, fear, panic attacks, and compulsive behaviors, cognitive impairment, seizures (predominantly in pediatric patients) [13], sleep disturbances, developmental and language regression, catatonia, gait instability, and autonomic instability [14,15].

SUBTYPES OF AUTOIMMUNE ENCEPHALITIS

Depending on the presence of specific autoantibodies directed against synaptic and neuronal cell surface antigens [2], the following encephalitis subtypes occur:

Antibodies against intracellular antigens

Anti-Hu encephalitis (ANNA-1)

In Anti-Hu encephalitis (ANNA-1), many patients present with sensory neuropathy, cerebellar degeneration, encephalitis, or encephalomyelitis. Interestingly, this condition is closely related to small cell lung cancer [5]. Other patients with Anti-Hu present with a pattern of encephalitis with greater involvement of the brainstem [16-18] or limbic system [8,18,19].

Antibodies against intracellular synaptic proteins

Anti-GAD65 encephalitis

In Anti-GAD65 encephalitis (glutamic acid decarboxylase 65 kd), the antibody targets the enzyme required for the synthesis of the neurotransmitter GABA [5,20,21]. It is clinically associated with type 1 diabetes mellitus, cerebellar ataxia, Stiff Man syndrome [22,23] and limbic encephalitis [2,8,18,19]. In the paraneoplastic setting, it is related to paraneoplastic cerebellar degeneration [5].

Antibodies against extracellular antigens

Anti-NMDAr encephalitis

Anti-NMDAr (N-methyl-D-aspartate receptor) encephalitis represents 20% of autoimmune encephalitis, being the most frequent [2]. It begins with fever, nausea and diarrhea, 2 weeks later psychiatric and / or neurological symptoms begin, progressing rapidly with a tendency to severity, reaching a comatose phase [14,24,25]. Its classic manifestations are: psychosis, agitation, dyskinesias, sleep disorders, mutism, encephalopathy,

faciobrachial seizures, dysautonomia, and cognitive impairment [25].

Anti-LGI1 encephalitis

Anti-LGI1 encephalitis (glioma-inactivated leucine-1) is responsible for most cases of encephalitis attributed to VGKC1 antibodies, its most frequent symptoms are myoclonus, seizures, hyponatremia, limbic encephalitis and fascio-brachial dystonic seizures [26-28].

Anti-Caspr2 encephalitis

Anti-Caspr2 encephalitis is associated with Morvan syndrome and Isaacs syndrome. It may present with confusion and personality change [5,29].

Seronegative Autoimmune Encephalitis

A subgroup of patients, due to their clinical manifestations, presents suspicion of autoimmunity, but the antibody detection test is negative, their main symptoms are of a psychiatric nature, including perceptual alterations, catatonia and agitation [1].

DIAGNOSTIC APPROACH

The diagnosis of AD is made based on the clinical characteristics, so it should be suspected in any adult or child with the previously mentioned manifestations. Usually, the diagnosis is accompanied by magnetic resonance imaging, electroencephalography, functional neuro imaging, analysis of systemic tumors, and detection of antibodies.

In Magnetic Resonance, the EA may appear as a completely normal image to an abnormal increase in contrast in the cortical or subcortical area of the brain parenchyma. Positron emission tomography, although not performed routinely, can report an increase in frontal-occipital metabolism. This latter finding is related to longstanding [1,2,3,30] disease.

The most frequently observed changes in cerebrospinal fluid (CSF) are predominantly lymphocytic pleocytosis or oligoclonal bands in the CSF. Another diagnostic tool is the EEG. In this study, a low frequency of disordered activity can be observed, but epileptogenic activity is rarely evidenced. A unique finding, known as a delta brush, is related to prolonged disease [31].

Another useful tool is the detection of autoantibodies in both blood and CSF. One of the most frequent antibodies isolated is the IgG anti-

NMDAR antibody [15]. It should be emphasized that the detection of antibodies in CSF has greater sensitivity and specificity than serum detection [32]. In certain cases, the anti-NMDAR type IgA and IgM may be isolated, but these do not have diagnostic value, however, they are associated with chronic diseases such as schizophrenia [33,34].

In the setting of advanced encephalitis, antibodies tend to remain elevated in CSF, while their titers may be low in serum due to treatment [30,35,36]. The differential diagnosis of AD includes a broad category of psychiatric disorders such as psychosis or schizophrenia (the most common), malignant catatonia, or viral encephalitis. Although not very common, cases of autoimmune encephalitis associated with COVID-19 have been reported [37-39].

PILLARS OF AUTOIMMUNE ENCEPHALITIS THERAPY

There are 2 primary goals in AD therapy: reducing inflammation and slowing the development of the disease, which in turn improves symptoms in patients [1]. A cornerstone of treatment is the early use of immunotherapy when there is a high clinical suspicion of AE, even when the presence of neoplasia or the presence of antibodies has not been identified [40]. However, antibody identification is crucial and that leads to a specific treatment. If there is the presence of tumors, resection This is an important part of treatment [2,3,6].

Immunotherapy

Immunotherapy in AD includes general immunosuppressive agents and others that target phases of pathogenesis [6].

There are 3 lines of treatment; a first-line consisting of steroids, intravenous (IV) immunoglobulin and plasmapheresis (PLEX), a second containing Rituximab and cyclophosphamide, and an alternative therapy that includes agents such as azathioprine, mycophenolate mofetil [1,3,6,41, 42], which are steroid-sparing agents used for maintenance, and tocilizumab for refractory cases [6]. It is important to keep in mind that AE associated with neoplasms has a faster course and is irreversible; in other words, it is difficult for patients to recover even when treatment is started early [43].

In the event of clinical suspicion of AD, empirical treatment should be instituted as quickly as possible,

even before the results of antibody tests [40], and may include steroids and/or IV immunoglobulins [5], and if the first-line therapy fails, we should start the second line as quickly as possible. The response to first-line therapy [6] can be observed approximately 2 weeks after starting treatment, so this is the time to take into account for changing therapy, if necessary. However, a significant number of patients with AD will respond to first-line therapy and will have a good outcome within 1–2 weeks after initiation of therapy [3]. Table 2 describes the therapeutic lines available for the management of AD.

Therapy	Therapeutic target	Posology	
		Children	Adults
First line therapy			
Corticosteroids Methylprednisolone (solumedrol) [5]	Cytokines, deplete T cells	30 mg / kg up to 1000 mg IV over 3 to 5 days	1 gram per day for 3-5 days
IV immunoglobuline	Antibodies and autoimmune mediators	2 g / kg over 2 days, followed by weekly dose for the next 4 weeks**	0.4 g / kg / day for 5 days
Plasmapheresis	Antibodies and autoimmune mediators		1 session every 2 days for 5-7 days
Second line therapy			
Rituximab	CD20 + B cells and short-lived plasma cells		375 mg / m ² IV infusion weekly for 4 weeks
Cyclophosphamide	Lymphocytes (alters DNA crosslinking)		750 mg / m ² IV monthly *** for 3-6 months [3,6]
Alternative therapy			
Azathioprine	Lymphocytes (blocks nucleotide synthesis)		Initially 1-1.5 mg / kg once daily or divided twice daily, target 2-3 mg / kg / day

Mycophenolate	Lymphocytes (inhibits IMP dehydrogenase)		Initially 500mg twice daily, target 1000mg twice daily
Tocilizumab	Cytokines		Initially 4 mg/kg, followed by an increase of 8 mg/kg per month based on clinical response
IL-2 (aldesleucina)	Cytokines		1.5 million IU / day, 4 subcutaneous injections 3 weeks apart each other

** If a synaptic antibody/cell surface disorder is detected, administer IVIG, plasmapheresis, and/or steroids. If a synaptic / cell surface antibody is determined and significant symptoms are shown, provide first-line therapy if not provided [5].

** In severe cases, it is given more frequently with the first 2-3 cycles given every 2 weeks [1]

*** Until improvement is observed [5].

Table 2. Therapeutic lines for autoimmune encephalitis [1,5,6].

Symptomatic treatment

It is composed of sedative drugs, to induce and maintain sleep; drugs to manage agitation and emotional instability such as benzodiazepines, clonidine, antiepileptics, choral hydrate, or others, which usually offer benefits [3]. Treatment in the presence of seizures must be carried out aggressively with antiepileptics. The majority of patients do not require long-term seizure treatment [44].

CORTICOSTEROIDS AND ITS MECHANISM OF ACTION IN ENCEPHALITIS

Corticosteroids are the most important first-line agents in AD therapy [3,6], being beneficial in multiple autoimmune disorders [5,6]. Although there is no strong evidence for the superiority of corticosteroids over other therapies, they are the first treatment option, followed by intravenous immunoglobulins and PLEX [6].

Mechanism of action

Corticosteroids are a group of drugs with anti-inflammatory characteristics that act on intracellular glucocorticoid receptors [6], interrupting the

transcription of multiple pro-inflammatory genes [6,7] that are activated in chronic inflammatory diseases [7] and that encode cytokines, chemokines, adhesion molecules, inflammatory enzymes, receptors, and proteins [6,7]. They influence almost all cytokines, thus depleting T cells, inhibiting Th1 differentiation, macrophage dysfunction, and eosinophil apoptosis [6]. In high concentrations, they have activity on the synthesis of anti-inflammatory proteins and induce post-transcriptional or post-genomic effects [6,7].

Advantages

They penetrate the brain, an advantage it has over other drugs such as Rituximab, which does not cross the blood-brain barrier (BBB) [6], so they are given as empirical therapy in suspected AD [45]. In addition, they modulate the BBB [3] restoring its integrity and controlling cerebral edema [6].

Goldenholz et al [45] state that corticosteroids as a low-cost therapy could play a role in treatment algorithms for suspected AD cases [45]. Similarly, Prasad et al [46] that in AD a good response to steroids has been shown even when no confirmed serology suggests an autoimmune basis [46].

Disadvantages

Steroids have low specificity on antibody-mediated immune processes, so their efficacy has been debated in AD since they slightly decrease the number of circulating B cells, not contributing much to antibody titers; in addition, they have been associated with systemic side effects [6]. It should be noted that side effects are more frequent with the use of oral steroids than with intravenous [1]. Corticosteroids can also cause or increase the psychiatric symptoms associated with AD, and some clinical studies even suggest neurotoxic and neurodegenerative effects of corticosteroids after chronic exposure [6].

Management

Steroids are administered IV or orally, the former being delivered as "pulse doses" (Table 2). This therapy is not standard and there are no clear treatment regimens [1]. Nosadini et al [47] carried out a systematic review on immune therapy in AD, with the aim of generating evidence on the use, type of treatment and efficacy, finding that as first-line

therapy, it is used in the majority of cases (more than 50% of patients with AD) [47].

CONCLUSION

Autoimmune encephalitis is a syndrome whose pathogenesis involves different immunological pathways against neuronal surface antigens, for which immunotherapy with various immunosuppressive agents has been proposed as treatment; with a relatively accepted answer. Corticosteroids are consolidated as first-line agents in the treatment of AD, however, better quality studies are needed to demonstrate their superiority over other therapies, and thus identify the safest and most effective system.

REFERENCES

- Mooneyham GLC, Gallentine W, Van Mater H. Evaluation and Management of Autoimmune Encephalitis: A Clinical Overview for the Practicing Child Psychiatrist. *Child Adolesc Psychiatr Clin N Am*. 2018; 27(1):37–52.
- Bost C, Pascual O, Honnorat J. Autoimmune encephalitis in psychiatric institutions: Current perspectives. *Neuropsychiatr Dis Treat*. 2016; 12:2775–87.
- Dale RC, Gorman MP, Lim M. Autoimmune encephalitis in children: Clinical phenomenology, therapeutics, and emerging challenges. *Curr Opin Neurol*. 2017; 30(3):334–44.
- Fukata M, Yokoi N, Fukata Y. Neurobiology of autoimmune encephalitis. *Curr Opin Neurobiol*. 2018; 48:1–8.
- Lancaster E. The Diagnosis and Treatment of Autoimmune Encephalitis. *J Clin Neurol*. 2016; 12(1):1–13.
- González Torre JA, Cruz-Gómez AJ, Belenguer A, Sanchis-Segura C, Ávila C, Forn C. Hippocampal dysfunction is associated with memory impairment in multiple sclerosis: A volumetric and functional connectivity study. *Mult Scler J*. 2017; 23(14):1854–63.
- Barnes PJ. How corticosteroids control inflammation: Quintiles Prize Lecture 2005. *Br J Pharmacol*. 2006; 148(3):245–54.
- Gultekin SH, Rosenfeld MR, Voltz R, Eichen J, Posner JB, Dalmau J. Paraneoplastic limbic encephalitis: neurological symptoms, immunological findings and tumour association in 50 patients. *Brain*. 2000; 123 (Pt 7):1481–94.
- Sillevis Smitt P, Grefkens J, de Leeuw B, van den Bent M, van Putten W, Hooijkaas H, et al. Survival and outcome in 73 anti-Hu positive patients with paraneoplastic encephalomyelitis/sensory neuronopathy. *J Neurol*. 2002; 249(6):745–53.
- Bonfa E, Elkon KB. Clinical and serologic associations of the antiribosomal P protein antibody. *Arthritis Rheum*. 1986; 29(8):981–5.
- Koffler D, Miller TE, Lahita RG. Studies on the specificity and clinical correlation of antiribosomal antibodies in systemic lupus erythematosus sera. *Arthritis Rheum*. 1979; 22(5):463–70.
- Tanaka K. Recent update on autoimmune encephalitis/encephalopathy. *Clin Exp Neuroimmunol*. 2015; 6(1):70–82.
- Wright S, Vincent A. Pediatric autoimmune epileptic encephalopathies. *J Child Neurol* 2017; 32(4):418–28.
- Dalmau J, Tüzün E, Wu HY, Masjuan J, Rossi JE, Voloschin A, et al. Paraneoplastic anti-N-methyl-D-aspartate receptor encephalitis associated with ovarian teratoma. *Ann Neurol*. 2007; 61(1):25–36.
- Prüss H, Dalmau J, Harms L, Höltje M, Ahnert-Hilger G, Borowski K, et al. Retrospective analysis of NMDA receptor antibodies in encephalitis of unknown origin. *Neurology*. 2010; 75(19):1735–9.
- Dalmau J, Graus F, Rosenblum MK, Posner JB. Anti-Hu-associated paraneoplastic encephalomyelitis/sensory neuronopathy. A clinical study of 71 patients. *Medicine (Baltimore)*. 1992; 71(2):59–72.
- Saiz A, Bruna J, Stourac P, Vigliani MC, Giometto B, Grisold W, et al. Anti-Hu-associated brainstem encephalitis. *J Neurol Neurosurg Psychiatry*. 2009; 80(4):404–7.
- Voltz R, Gultekin SH, Rosenfeld MR, Gerstner E, Eichen J, Posner JB, et al. A serologic marker of paraneoplastic limbic and brain-stem encephalitis in patients with testicular cancer. *N Engl J Med*. 1999; 340(23):1788–95.
- Lawn ND, Westmoreland BF, Kiely MJ, Lennon VA, Vernino S. Clinical, magnetic resonance imaging, and electroencephalographic findings in paraneoplastic limbic encephalitis. *Mayo Clin Proc*. 2003; 78(11):1363–8.
- Kim J, Namchuk M, Bugawan T, Fu Q, Jaffe M, Shi Y, et al. Higher autoantibody levels and recognition of a linear NH2-terminal epitope in the autoantigen GAD65, distinguish stiff-man syndrome from insulin-dependent diabetes mellitus. *J Exp Med*. 1994; 180(2):595–606.
- Dalakas MC. Stiff person syndrome: advances in pathogenesis and therapeutic interventions. *Curr Treat Options Neurol*. 2009; 11(2):102–10.
- Manto MU, Laute MA, Aguera M, Rogemond V, Pandolfo M, Honnorat J. Effects of anti-glutamic acid decarboxylase antibodies associated with neurological diseases. *Ann Neurol*. 2007; 61(6):544–51.
- Alexopoulos H, Dalakas MC. A critical update on the immunopathogenesis of Stiff Person Syndrome. *Eur J Clin Invest*. 2010; 40(11):1018–25.
- Dalmau J, Gleichman AJ, Hughes EG, Rossi JE, Peng X, Lai M, et al. Anti-NMDA-receptor encephalitis: case series and analysis of the effects of antibodies. *Lancet Neurol*. 2008; 7(12):1091–8.
- Florange-Ryan N, Dalmau J. Update on anti-N-methyl-D-aspartate receptor encephalitis in children and adolescents. *Curr Opin Pediatr*. 2010; 22(6):739–44.
- Irani SR, Michell AW, Lang B, Pettingill P, Waters P, Johnson MR, et al. Faciobrachial dystonic seizures precede Lgi1 antibody limbic encephalitis. *Ann Neurol*.

- 2011; 69(5):892-900.
27. Sen A, Wang J, Laue-Gizzi H, Lee T, Ghougassian D, Somerville ER. Pathognomonic seizures in limbic encephalitis associated with anti-LGI1 antibodies. *Lancet*. 2014; 383(9933):2018.
 28. Thompson J, Bi M, Murchison AG, Makuch M, Bien CG, Chu K, et al. Faciobrachial Dystonic Seizures Study Group. The importance of early immunotherapy in patients with faciobrachial dystonic seizures. *Brain*. 2018; 141(2):348-356.
 29. López-Chiriboga AS, Klein C, Zekeridou A, McKeon A, Dubey D, Flanagan EP, et al. LGI1 and CASPR2 neurological autoimmunity in children. *Ann Neurol*. 2018; 84(3):473-480.
 30. Florance NR, Davis RL, Lam C, Szperka C, Zhou L, Ahmad S, et al. Anti-N-methyl-D-aspartate receptor (NMDAR) encephalitis in children and adolescents. *Ann Neurol*. 2009; 66(1):11-8.
 31. Schmitt SE, Pargeon K, Frechette ES, Hirsch LJ, Dalmau J, Friedman D. Extreme delta brush: a unique EEG pattern in adults with anti-NMDA receptor encephalitis. *Neurology*. 2012; 79(11):1094-100.
 32. Gresa-Arribas N, Titulaer MJ, Torrents A, Aguilar E, McCracken L, Leypoldt F, et al. Antibody titres at diagnosis and during follow-up of anti-NMDA receptor encephalitis: a retrospective study. *Lancet Neurol*. 2014; 13(2):167-77.
 33. Dahm L, Ott C, Steiner J, Stepniak B, Teegen B, Saschenbrecker S, et al. Seroprevalence of autoantibodies against brain antigens in health and disease. *Ann Neurol*. 2014; 76(1):82-94.
 34. Hara M, Martinez-Hernandez E, Ariño H, Armangué T, Spatola M, Petit-Pedrol M, et al. Clinical and pathogenic significance of IgG, IgA, and IgM antibodies against the NMDA receptor. *Neurology*. 2018; 90(16):e1386-e1394.
 35. Okamoto S, Hirano T, Takahashi Y, Yamashita T, Uyama E, Uchino M. Paraneoplastic limbic encephalitis caused by ovarian teratoma with autoantibodies to glutamate receptor. *Intern Med*. 2007; 46(13):1019-22.
 36. Seki M, Suzuki S, Iizuka T, Shimizu T, Nihei Y, Suzuki N, et al. Neurological response to early removal of ovarian teratoma in anti-NMDAR encephalitis. *J Neurol Neurosurg Psychiatry*. 2008; 79(3):324-6.
 37. Monti G, Giovannini G, Marudi A, Bedin R, Melegari A, Simone AM, et al. Anti-NMDA receptor encephalitis presenting as new onset refractory status epilepticus in COVID-19. *Seizure*. 2020; 81:18-20.
 38. Burr T, Barton C, Doll E, Lakhota A, Sweeney M. N-Methyl-D-Aspartate Receptor Encephalitis Associated With COVID-19 Infection in a Toddler. *Pediatr Neurol*. 2021; 114:75-76.
 39. Panariello A, Bassetti R, Radice A, Rossotti R, Puoti M, Corradin M, et al. Anti-NMDA receptor encephalitis in a psychiatric Covid-19 patient: A case report. *Brain Behav Immun*. 2020; 87:179-181.
 40. Graus F, Titulaer MJ, Balu R, Benseler S, Bien CG, Cellucci T, et al. A clinical approach to diagnosis of autoimmune encephalitis. *Lancet Neurol*. 2016; 15(4):391-404.
 41. Shin YW, Lee ST, Park KI, Jung KH, Jung KY, Lee SK, et al. Treatment strategies for autoimmune encephalitis. *Ther Adv Neurol Disord*. 2017; 11:1756285617722347.
 42. Vernino S, O'Neill BP, Marks RS, O'Fallon JR, Kimmel DW. Immunomodulatory treatment trial for paraneoplastic neurological disorders. *Neuro Oncol*. 2004; 6(1):55-62.
 43. Vedeler CA, Antoine JC, Giometto B, Graus F, Grisold W, Hart IK, et al. Paraneoplastic Neurological Syndrome Euronetwork. Management of paraneoplastic neurological syndromes: report of an EFNS Task Force. *Eur J Neurol*. 2006; 13(7):682-90.
 44. Dalmau J, Lancaster E, Martinez-Hernandez E, Rosenfeld MR, Balice-Gordon R. Clinical experience and laboratory investigations in patients with anti-NMDAR encephalitis. *Lancet Neurol*. 2011; 10(1):63-74.
 45. Goldenholz DM, Wong VS, Bateman LM, Apperson M, Oskarsson B, Akhtar S, et al. Treatment of γ -aminobutyric acid B receptor-antibody autoimmune encephalitis with oral corticosteroids. *Arch Neurol*. 2012; 69(8):1061-3.
 46. Prasad P, Bhargava A, Khichar S, Gupta VK. Clinical spectrum of autoimmune encephalitis: Case series from Western Rajasthan. *J Clin Diagnostic Res*. 2017; 11(11):OR01-OR04.
 47. Nosadini M, Mohammad SS, Ramanathan S, Brilot F, Dale RC. Immune therapy in autoimmune encephalitis: a systematic review. *Expert Rev Neurother*. 2015; 15(12):1391-419.