



Communicating spinal epidural thoracic arachnoid cyst en-bloc resection. A case report

M. Al-Zekri, F. Aichaoui, I. Assoumane, A. Khelifa,
W. Bennabi, A. Morsli

Department of Neurosurgery, CHU Bab El Oued, Algiers, ALGERIA

ABSTRACT

Background: Spinal extradural arachnoid cyst is an uncommon, expanding lesion which may communicate with the subarachnoid space, The etiology still remains unclear, but the most accepted explanation is the existence of areas of weakness in the spinal dura, Spinal arachnoid cysts are usually in the thoracic spine, and they may cause symptoms due to spinal cord compression.

Case Presentation: Patient is a 54-years-old female who presented with progressive back pain and motor deficit, Magnetic resonance imaging (MRI) study revealed an extradural cyst extending from T2 to T4 isointense with the cerebrospinal fluid (CSF) on all sequences and did not enhance on T1-weighted post-contrast MRI. Patient underwent T2-T4 laminectomy, en-bloc resection of the lesion was achieved and the histopathological examination objectified an arachnoid cyst.

Conclusion: Spinal extradural arachnoid cyst can cause neurologic deficit and the mainstay of treatment in patients with neurological symptoms is surgical removal of the cyst together with ligation of the communicating pedicle and closure of the dural defect.

INTRODUCTION

Arachnoid cysts are benign lesions located in the brain or spinal cord; usually found incidentally during radiological exploration (1), Spinal arachnoid cysts result in a collection of cerebrospinal fluid that can occur in a perineural, extradural, intradural, or intra-extradural site (2). Spinal arachnoid cysts are a rare cause of spinal cord compression. spinal arachnoid cysts may be associated with other neural tube defects such as spina bifida occulta and diastematomyelia (2).

MRI is the diagnostic procedure of choice as it is noninvasive and can demonstrate the nature of cyst, size, and the anatomic relationship with the spinal cord. Surgical treatment is required when neurological symptoms develop due to cyst induced spinal cord or nerve root compression (4). Here we reported our experience on the management of a 54 years old female who presented a communicating spinal epidural thoracic arachnoid Cyst.

Keywords
spinal cord,
arachnoid cyst,
laminectomy,
resection



Corresponding author:
M. Al-Zekri

Department of Neurosurgery, CHU
Bab El Oued, Algiers, Algeria

muneeralzekri30@yahoo.com

Copyright and usage. This is an Open Access article, distributed under the terms of the Creative Commons Attribution Non-Commercial No Derivatives License (<https://creativecommons.org/licenses/by-nc-nd/4.0/>) which permits non-commercial re-use, distribution, and reproduction in any medium, provided the original work is unaltered and is properly cited.

The written permission of the Romanian Society of Neurosurgery must be obtained for commercial re-use or in order to create a derivative work.

ISSN online 2344-4959
© Romanian Society of
Neurosurgery



First published
December 2019 by
London Academic Publishing
www.lapub.co.uk

CASE REPORT

We reported here a case of a 54 years old female without past medical or surgical history complaining with progressive back pain, and paresthesia in lower limbs which has been initiated from 9 years worsening in the last 3 months with weakness of lower extremities. Clinical examination at admission revealed a paraparesia 4/5. There was no history of recent traumatism.

The spinal MRI showed a thoracic extradural arachnoid cyst from lower edge of T2 to lower edge of T4 and cervical spinal canal stenosis, the cyst is hyper intense signal in T2-weighted, hypo intense signal in T1-weighted and did not enhance on T1-weighted post-contrast (Figure 1 and Figure 2).

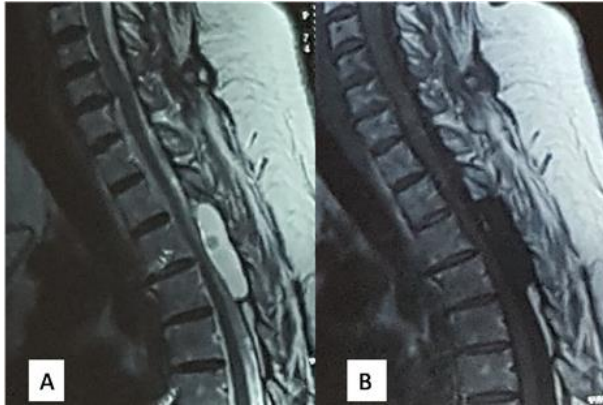


Figure 1. Pre-operative spinal MRI shows a cystic lesion extending from lower edge of T2 to lower edge of T4 with hyper intense signal on T2-weighted MRI accompanied by a central hypo intense signal (A), hypo intense signal on T1-weighted MRI (B).

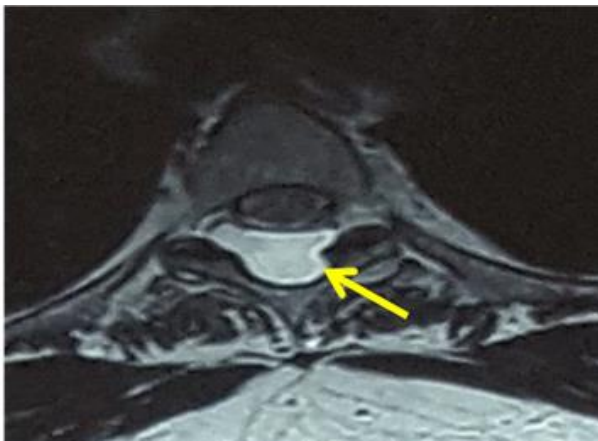


Figure 2. T2-weighted MR imaging sequences showing arachnoid cyst with high signal intensity at T2 to T4 level.

We operated the patient under general anesthesia in

prone position. We performed a midline incision followed by laminectomy (T2-T3-T4), after exposure of the lesion and identification of its superior and inferior poles, we began the soft dissection of the lower pole lesion towards the superior pole, then we identified the communication between the cyst and the subarachnoid spaces through a dural defect, after total excision en bloc we close the dural defect with a muscular patch (Figure 3).

Postoperative histologic findings were compatible with the presence of an arachnoid cyst with fibrous cyst wall-like tissue. Back pain in the patient and paraparesis were gradually improved.

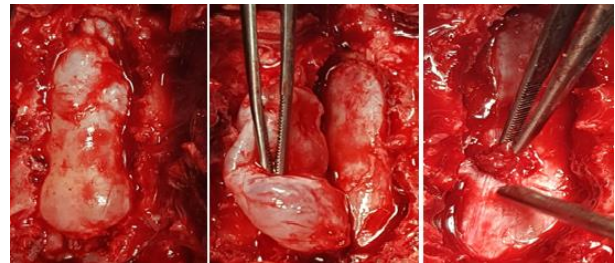


Figure 3. Intra-operative view. (a): Following laminectomy and visualization of the cyst (yellow star); (b): En-bloc resection of the lesion and visualization of the dura (blue star); (c) Ligation of the communicating pedicle and closure of the dural defect (yellow arrow).

DISCUSSION

Arachnoid cysts are benign developmental cysts that occur in the craniospinal axis in relation to the arachnoid membrane. We report a case of extradural arachnoid cyst, for many authors the spinal arachnoid cysts may be intradural or extradural and are composed of normal or slightly thickened arachnoid (6)

A spinal extradural arachnoid cyst is a rare disease, accounting for approximately 1% to 3% of spinal tumors (5, 8). They can be idiopathic or acquired, usually intradural, but can also rarely be extradural, primary spinal arachnoid cysts present in the thoracic spine in 80%, Secondary arachnoid cysts are usually due to trauma, hemorrhage, inflammation, surgery, or lumbar puncture (8).

Spinal extradural arachnoid cysts are most commonly found in the middle or lower thoracic spine, and less frequently found in the lumbar region, although they can be detected at any lesion of the spine (1, 3, 4, and 5). The case we report is in the most frequent site. These lesions are more common in men (sex ratio 2/1) and occurs in the

second decade of life. These lesions may be associated with vertebral anomalies, neural tube defects and syringomyelia (1, 2, 3, 5, and 6).

Various hypotheses have been proposed to explain why spinal arachnoid cysts form: 1- proliferation or loculation of arachnoid trabeculae in the septum posticum; 2- a fault in the expansion of the arachnoid trabecula and 3- the formation of arachnoid diverticuli in weak areas of the spinal dura mater (5).

Spinal extradural arachnoid cysts are usually asymptomatic; they can compress the spinal cord and give a neurological deficit; the medullary compression mechanism is still unclear but many authors have speculated that these cysts act as a unidirectional valve that let fluid in but not out.(1,3). The most common presenting symptoms are pain, paresthesia, intermittent claudication, and variable degrees of spastic weakness (3,4,6) like our patient who experiment back pain, paresthesia and paraparesia.

The differential diagnoses include: tarlov or perineural cyst, ganglion cyst, synovial cyst, epidermoid cysts, cystic neoplasms, parasitic cysts meningeal diverticula next to the nerve roots, meningocele, dermoid cyst, cysticercosis and hydatid cysts (1,5).

We use the spinal MRI to get the diagnosis , this investigation showed a thoracic extradural arachnoid cyst from lower edge of T2 to lower edge of T4 and cervical spinal canal stenosis, the cyst is hyper intense signal in T2-weighted, hypo intense signal in T1-weighted and did not enhance on T1-weighted post-contrast. Many authors reported signs of that lesion on other investigations tools. Radiographs of the spine usually show bone erosion with widening of the canal, erosion of pedicles, foraminal enlargement, and scalloping of the vertebral bodies or the sacrum (3).

CT can be helpful to identify a cyst complicated by internal hemorrhage as the quickest and most readily available neuroimaging test. However, an MRI is the most useful tool to diagnose a Spinal extradural arachnoid cyst. Radiological studies report that a Spinal extradural arachnoid cyst appears with low signal intensity on a T1-weighted image and with high signal intensity on a T2-WI, similar to cerebro-spinal fluid. Fluid attenuated inversion recovery sequences (FLAIR) sequences are also useful to confirm the similarity of the cyst fluid

to CSF. Diffusion weighted imaging is essential to differentiate arachnoid cysts, in particular from epidermoid cysts which can sometimes have a similar appearance (7). The management of these cysts can vary according to the patient's symptoms. There are many surgical options reported in the literature: bone decompression, subtotal or total resection of the cyst, drainage and marsupialisation of the cyst. In asymptomatic patients, conservative management with subsequent clinical observation is recommended (4, 5). The goal of surgical treatment is not only neural decompression but also the prevention of cyst refilling. For symptomatic extradural spinal arachnoid cysts the preferred treatment is surgical removal of the cyst together with ligation of the communicating pedicle and closure of the dural defect (3, 4). In the reported case we achieved the identification of the communication between the cyst and the subarachnoid spaces through a dural defect and after total excision en bloc we close the dural defect with a muscular patch.

CONCLUSION

Spinal extradural arachnoid cyst is a rare lesion, it is typically asymptomatic but sometimes can cause spinal cord or nerve root compression and may present with myelopathy. The etiology, pathogenesis and treatment of the spinal extradural arachnoid cysts have not been well established. To treat a spinal extradural arachnoid cyst, diverse surgical techniques have been introduced. However, there is no consensus regarding the most reasonable treatment.

REFERENCES

1. Afsoun Seddighi, Amir Nikouei, Amir Saied Seddighi, Mohammad Asadpour, Noushin Masoudian, Afshin Samaei, Shohada Tajrish: A Case Report Extradural Thoracic Arachnoid Cyst En-Bloc Resection and Follow-Up Comprehensive Neurosurgical Center of Excellence, Shahid Beheshti University of Medical Sciences, Tehran, Iran.
2. Dahlgren, Ryan M.; Baron, Eli M.; and Vaccaro, Alexander R., "Pathophysiology, diagnosis, and treatment of spinal meningoceles and arachnoid cysts" (2007). Department of Orthopaedic Surgery Faculty Papers. Paper 4. <https://jdc.jefferson.edu/orthofp/4>
3. Ertan ERGUN; Alp Özgün BÖRCEK; Berker CEMİL; Fikret DOĞULU; M. Kemali BAYKANER Should We Operate all

- Extradural Spinal Arachnoid Cysts? Report of a Case Turkish Neurosurgery 2008, Vol: 18, No: 1, 52-55.
4. JAMES K. LIU, M.D., CHAD D. COLE, M.D., PETER KAN, M.D., AND MEIC H. SCHMIDT, M.D. Spinal extradural arachnoid cysts: clinical, radiological, and surgical features Department of Neurological Surgery, Oregon Health & Science University, Portland, Oregon; and Department of Neurosurgery, University of Utah School of Medicine, Salt Lake City, Utah Neurosurg Focus 22 (2):E6, 2007.
 5. Quillo-Olvera J, Quillo-Reséndiz J, Gutiérrez-Partida C-F, Rodríguez-García M. Quiste aracnoideo extradural spinal: reporte de un caso y revisión de la literatura. Cir Cir. 2017;85:544--548.
 6. Guru Raj Aithala, MD, Laszlo Sztrihai, MD, Iradj Amirlak, MD, Kunjapanicker Devadas, MD, and Ingrid Ohlsson, MD: Spinal Arachnoid Cyst With Weakness in the Limbs and Abdominal Pain.
 7. Logan C, Asadi H, Kok HK, Looby S, O'Hare A, et al. 2016. Arachnoid Cysts - Common and Uncommon Clinical Presentations and Radiological Features. J Neuroimaging Psychiatry Neurol 1(2): 79-84.
 8. Lim K, Nouri M, Haffar A and Mazagri R. An Unusual, Acute Presentation of Thoracic Spinal Arachnoid Cyst. SM J Neurol Disord Stroke. 2018; 4(1): 1016.