



The supraorbital keyhole approach for clipping of anterior circulation ruptured aneurysms

Mostafa M. Nabeeh
Ashraf A. Ezz-El Din

Neurosurgery Department, Mansoura University, EGYPT

ABSTRACT

Introduction. The supraorbital approach has been demonstrated to be useful, particularly in minimization of brain retraction and exposure to air, decreases blood loss, surgical trauma, operative time and infection rates. While its shortcomings include difficult control of frontal air sinus, narrower surgical view and limited exposure of sylvian fissure.

Patients and methods. We retrospectively reviewed the files of patients who underwent clipping of anterior circulation aneurysms through the supraorbital keyhole approach at Neurosurgery Department, Mansoura University between Jan 2014 and May 2016.

Results. Twenty-five consecutive patients harbouring aneurysm at anterior circulation underwent clipping through the supraorbital keyhole approach, sixteen A-com artery aneurysms and nine cases of ICA aneurysms Table 1 show the location of aneurysms. Eleven patients were males, and 14 were females. The ages ranged from 44 to 69 with a mean age of 61.9 years. All patients were presented with subarachnoid haemorrhage due to rupture of aneurysms in anterior circulation The Hunt and Hess grade was (1.50 ± 0.65) and Fisher grade was (1.67 ± 0.45) . The average operative time was 3.32 ± 1.14 hours. Follow-up ranged from 1 to 16 months with a mean of 7 months

Conclusion. Surgical clipping of some selected aneurysms of anterior circulation can be operated through minimally invasive supraorbital approach which minimize the dissection and retraction of the brain, reduce operative time and blood loss with small incision and good cosmetic results.

INTRODUCTION

Conventional approaches to anterior skull base lesions including anterior circulation aneurysms highly developed since the large skin incision and fronto-temporal craniotomy described by Dandy to the less invasive pterional approach suggested by Yasargil [25] till the minimally invasive eye brow incision with supraorbital keyhole craniotomy [15, 20, 21, 24].

The pterional approach is popular and widely accepted among neurosurgeon; it provides wide central exposure, direct access to whole length of sylvian fissure, adequate visualization of anterior and

Keywords

supraorbital approach,
ruptured aneurysm,
keyhole concept



Corresponding author:
Mostafa M Nabeeh

Lecturer of Neurosurgery and
Deputy Director of Emergency
Hospital Mansoura University,
Egypt

sasamah2001@yahoo.com

Copyright and usage. This is an Open Access article, distributed under the terms of the Creative Commons Attribution Non-Commercial No Derivatives License (<https://creativecommons.org/licenses/by-nc-nd/4.0/>) which permits non-commercial re-use, distribution, and reproduction in any medium, provided the original work is unaltered and is properly cited.

The written permission of the Romanian Society of Neurosurgery must be obtained for commercial re-use or in order to create a derivative work.

ISSN online 2344-4959
© Romanian Society of
Neurosurgery



First published
December 2019 by
London Academic Publishing
www.lapub.co.uk

posterior circulation. However, pterional approach has disadvantages like longer operative time, blood loss, brain exposure, damage to frontal branch of facial nerve with subsequent facial asymmetry, temporalis wasting and interference with mandibular function [2, 9, 10, 11].

The supraorbital approach was early described and applied to a pituitary tumor by Frazier in 1913[12], then it has been described for multiple types of intracranial pathologies including Tumors excision, infection drainage, Fractures and Aneurysms clipping [4, 6, 20, 21].

Jane et al, described the supraorbital approach for clipping of anterior circulation aneurysms for the first time in 1982[15]. The approach was refined and popularized by Axel Perneczky, the pioneer in the development of keyhole concept [24,21].

The supraorbital approach has been demonstrated to be useful, particularly in minimization of brain retraction and exposure to air, decreases blood loss, surgical trauma, operative time and infection rates. While its shortcomings include difficult control of frontal air sinus, narrower surgical view and limited exposure of sylvian fissure [14, 16, 19, 22].

Complications related to the supraorbital approach may include cosmetic problems like visible scar or bone defects, damage to supraorbital nerve with frontal hypoesthesia, lost eyebrow elevation and CSF rhinorrhea [3, 5, 6].

MATERIALS AND METHODS

In this report, we represent our experience in clipping of anterior circulation ruptured aneurysms through the supraorbital keyhole approach.

We retrospectively reviewed the files of patients who underwent clipping of anterior circulation aneurysms through the supraorbital keyhole approach at Neurosurgery Department, Mansoura University between Jan 2014 and May 2016.

Only patients presented by subarachnoid hemorrhage due to ruptured aneurysm of anterior circulation and their aneurysms have clipped through supra orbital approach were included in this study. Demographic data, Hunt and Hess grades, Fisher grade, consciousness, aneurysm location, size, craniotomy size, operative time, blood loss, operative details, early post-operative follow up CT and CTA before discharge, clinical and surgical

complications and data from follow up visits were reviewed.

OPERATIVE TECHNIQUE

A lumbar drain was used in all cases. The patients were placed in a supine position with the head fixed in a Mayfield head holder, the neck extended and turned about 20° to the contralateral side .The skin incision placed in forehead crease extended from lateral edge of the supraorbital notch to the superior temporal line .Then fascia and frontalis muscle were incised in the line of the skin incision and retracted up .A free 3×2 cm bone flap using a fine craniotome as basal as we can. In case the sinus was opened we extended the incision laterally to expose temporalis fascia which used with a pericranial graft to control frontal air sinus after cauterization and stripping of mucosa and adequate disinfection, and packing with gelfoam soaked with bovodin. After adequate exposure, the dura was opened in transverse fashion, the lumbar drain opened, the frontal lobe falls backward aided by the effect of gravity and with minimal retraction the circle of Willis was identified, proximal control then clipping of the aneurysm. The incision above the eyebrow was sewn with a subcutaneous dissolving stitch. Figure (1 a-d)

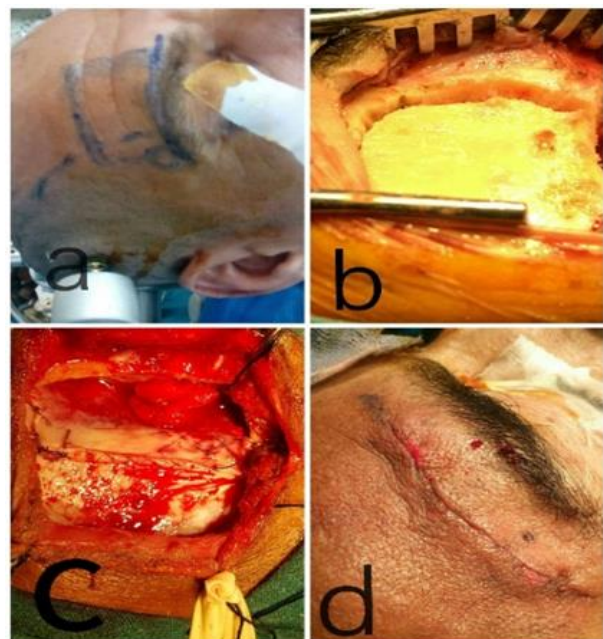


FIGURE 1. Operative technique - a) patient's head fixed to mayfield fixator marking of skin incision and bone flap; b) microneurosurgery; c) closure of dura; d) closure of skin incision.

RESULTS

Twenty-five consecutive patients harboring

aneurysm at anterior circulation underwent clipping through the supraorbital keyhole approach, sixteen A-com artery aneurysms and nine cases of ICA aneurysms Table 1 show the location of aneurysms. Eleven patients were males, and 14 were females. The ages ranged from 44 to 69 with a mean age of 61.9 years. All patients were presented with subarachnoid hemorrhage due to rupture of aneurysms in anterior circulation The Hunt and Hess grade was (1.50 ± 0.65) and Fisher grade was (1.67 ± 0.45) . The average operative time was 3.32 ± 1.14 hours. Follow-up ranged from 1 to 16 months with a mean of 7 months

TABLE 1. Location of Treated Aneurysms

Location	Number
Anterior communicating	16
Anterior cerebral	4
Posterior communicating	3
Ophthalmic	1
Bifurcation	1

Visualization and orientation of aneurysm neck was feasible through mini craniotomy in 24 cases (96%) in whom successful aneurysm clipping was possible. (Figure 2, 3 and 4) In one patient, early aneurysm rupture obscures the field and procedure aborted after bleeding control then the patient was re-operated later through inter-hemispheric approach. Table 2 summarizes the operative findings.

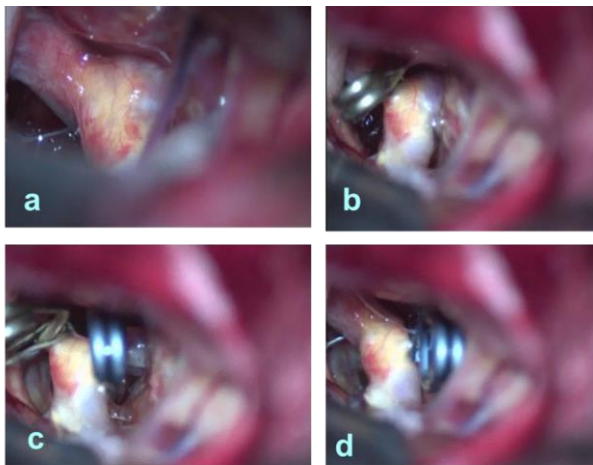


FIGURE 2. Case of Posterior communicating segment aneurysm a- aneurysm identification b- temporary clip application C- application of permanent clip d- removal of temporary clip and dissection of dome.

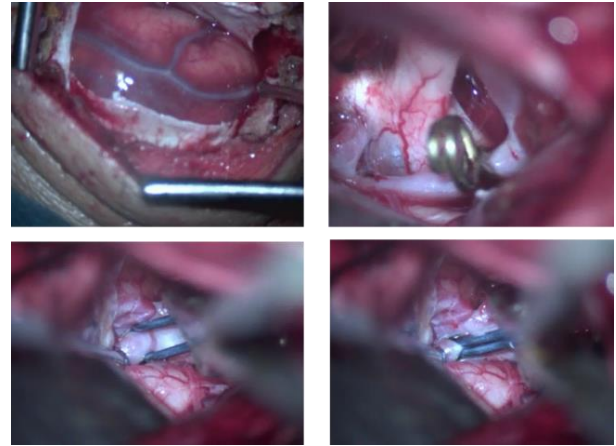


FIGURE 3. Case of anterior communicating artery aneurysm a-opening of dura and SAH and brain selling is identified b-temporary clip application c&d- application of permanent clip.

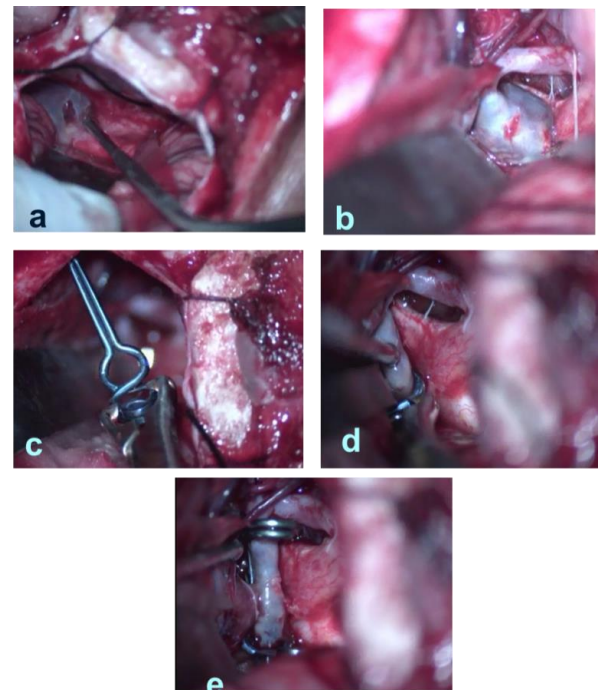


FIGURE 4. Case of large anterior communicating artery aneurysm: a) opening of dura and SAH and brain selling is identified; b) identification of aneurysm with wide neck; c) Right angle fenestrated clip for reconstruction of anterior communicating artery; d) application of the first permanent clip; e) application of another fenestrated clip to reconstruct A.com artery.

Intra operative rupture Occurred in two cases (8%); one carotid bifurcation aneurysm controlled by a temporary clip over proximal internal carotid artery. Another one ugly large multi lobulated A.com aneurysm ruptured very early during frontal retraction. The dominant Left anterior cerebral

couldn't be controlled from the right supraorbital approach. This patient was planned for clipping through this approach according CT angiogram only while DSA revealed the complicated configuration of aneurysm. Patient planned later for inter-hemispheric approach the aneurysm was clipped after the A1 segment of Left anterior cerebral artery was proximally controlled before dissection of the aneurysm neck.

TABLE 2. Operative findings

Total number	25
Number clipped	24
Mean operation time	190 minutes
Estimated Blood loss	50-300 (100ml)
Size of aneurysm	7±3 mm
Size of craniotomy	3±1.7 × 2±1.2 mm
Lumbar drain	25
Gyrus rectus subpial resection	4
Post-operative hospitalization stay	2-18 (7) days

TABLE 3. Post-operative CT and CTA findings

CTA residual neck	0
radiological vasospasm	6/25(24%)
CT brain	
Hemorrhage	1/25(4%)
Br contusion	2/25(8%)
Oedema	3/25(12%)
Infarction	3/25(12%)

Frontal air sinus was breached in 2 cases (8%) securing of sinus was done in both cases, one of those two cases was 60 years old patient developed CSF rhinorrhea which needed reoperation the basal dura was successfully repaired with fascia lata graft.

CT brain and CTA routinely have done for all patients, table 3 summarize the of post-operative radiological findings.

9 patients (36%) suffered transient periorbital ecchymosis and oedema that resolved few days later. Three patients (12%) showed post-operative transient deficit which improved later. Two patients died in this study one patient died due to symptomatic vasospasm and another patient died before discharge from hospital after postoperative pneumonia.

23 patients were Clinically followed-up for duration ranged from 3 to 30 months, 82.3% (19/23) of patients attained a favorable outcome (Glasgow Outcome Scale IV or V), no re-bleeding was noted.

As regard cosmetic outcome, the survived 23 patients were questioned for their subjective satisfaction about the esthetic outcome of their surgical incision on 3 months follow up visit. Figure 5. Nineteen patients (82.6%) were happy and satisfied about cosmetic outcome, while 4 patients were not satisfied; one female patient complained frontal hypoesthesia with denervation pain and itching lead to hyperpigmentation of forehead and alopecia behind hair line, Figure 6. another patient complained depression of forehead with loss of forehead elevation and 2 patients were worry about hyper pigmented scar.

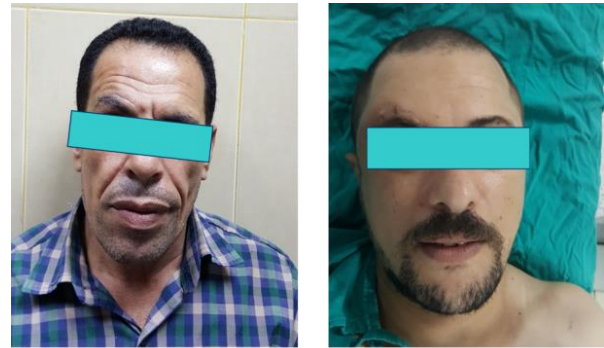

FIGURE 5. Early and late cosmetic outcome

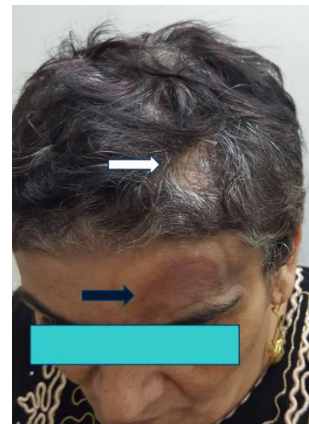

FIGURE 6.

Hyperpigmentation (blue arrow) and alopecia (white arrow) after injury of supraorbital nerve and denervation pain and itching.

DISCUSSION

The endovascular coiling for management of ruptured intracranial aneurysms are less invasive than surgical clipping and this made a challenge for surgical approaches to be less traumatizing,

otherwise, it won't be accepted by many patients as alternative option [1, 8, 13, 18].

Surgical clipping of aneurysm provides visualization of vasculature and perforators, permanent secure of aneurysm, cleaning blood from subarachnoid spaces which decreases incidence of vasospasm and hydrocephalus, however, the International Subarachnoid Aneurysm Trial (ISAT) study comparing both modalities showed marginal superiority for endovascular techniques for management of ruptured aneurysm [18]. One explanation for these results is the application of standard approaches so the approach related morbidity down the outcome of surgical cases [18].

Supraorbital approach uses a smaller bone flap than others standard microsurgical approaches and minimize brain exposure, retraction, and traumatization, and possibly improve cosmetic results due to small incision, avoiding the injury of the frontal branches of facial nerve or the temporalis muscle and not interfere with mandibular function [7, 12, 17].

In this study we reported feasibility of clipping of ruptured anterior circulation aneurysms using the keyhole supraorbital craniotomy which proved by good results.

Our results of clipping 96% of aneurysms and 82.3% of patients attained favorable outcome support others conclusions [3, 5, 7, 16] that the supraorbital approach can be performed reliably and safely to clip ruptured anterior circulation aneurysms. However the fact that we spare the approach for certain selected aneurysms doesn't support its use for all anterior circulation aneurysms. The minimally invasive nature of this approach with less trauma, operative time and blood loss is suitable for relatively small aneurysms with simple configuration, and should be on the armamentarium of vascular neurosurgeon to be provided as option for some patients.

Narrower surgical view and limited exposure, unfamiliar view of anatomy especially of sylvian fissure which appeared laterally in the operative field. This make this approach not universe for all cases and not standard approach like pterional, but should be served for cases when the size and extent of exposure is enough for safe proximal control of parent vessel, appropriate dissection of the aneurysm neck and secure clip application [14, 16]

We faced intraoperative early rupture of aneurysm in 2 cases (8%) in one patient we couldn't clip the aneurysm a situation realized later and after doing DSA to be related to planning and selection of the aneurysm. Madhugiri et al [17] in a systematic review of Intraoperative Rupture Rates in suprabrow and pterional approaches, they analyzed a total number of 3039 ruptured aneurysms, 2848 aneurysms in the pterional group and 191 in the suprabrow group and they found the rate of intraoperative rupture is higher in suprabrow patients than pterional group 19.37% and 13.8% respectively.

Chalhouni et al [5] reported higher rate of intraoperative aneurysm rupture in the supraorbital group compared to pterional (10.6% vs 2.5%) they explained it as the lesser degrees of proximal control and the narrow available space for dissection and maneuverability of instruments, and advocated the supraorbital keyhole approach to be performed by neurosurgeons who have gained sufficient experience with the technique.

Exposure of frontal air sinus in 2 cases with persistent post-operative CSF rhinorrhea in spite that we have planed the craniotomy on preoperative CT bone window for assessment of the pneumatization of the frontal air sinus. We didn't consider the supraorbital approach if there is large sinus that extends beyond the expected line of supraorbital nerve. The incidence of CSF rhinorrhea after supra orbital approach in the literature is ranged between 0% and 9.1%. Thaher et al. studied 350 patients of supraorbital keyhole craniotomy and reported 25.1% radiographic breaching of the frontal sinus and 2.3% developed CSF rhinorrhea postoperatively [23].

In their report of 139 patients Van Lindert et al performed a supraorbital craniotomy for aneurysm clipping, craniotomy size was 2-3.5 cm in width and 1.5-2 cm in height. They reported no frontal sinus exposure and emphasized the importance of measurement of the frontal sinus on pre-operative images [24]. Kim et al made wider craniotomy (4.5cm) and report one sinus exposure in their 10 approaches [16].

The two cases of mortality were of high Hunt-Hess and Fisher grads, and we think their checkered post-operative course was related to their clinical condition and ICU stay rather than to be related to the approach used for clipping.

We routinely used lumbar drain inserted before

positioning of patient which opened after opening of dura for CSF drainage which facilitate relaxation of the frontal lobe, we think it is of extremely important step because all of our patients presented by aneurysm rupture and brain swelling is expected and blood in subarachnoid spaces made opening of cisterns and drainage of CSF of limited value. However some report operating on ruptured aneurysm as early as 2 days through keyhole approach and found slow CSF drainage from cistern is feasible [20]. Others drain cerebrospinal fluid by intraoperative ventriculostomy at Paine's point [6, 14, 16].

The small sample size, retrospective design of this study and selection of certain aneurysm size type and location are limitations of this report but we reported our experience of clipping the ruptured anterior circulation aneurysms through this approach. Despite few comparative studies comparing the approach to conventional ones still we need large size randomized blind trial to compare minimally invasive approaches to conventional open approach and to endovascular technique.

CONCLUSIONS

Surgical clipping of some selected aneurysms of anterior circulation can be operated through minimally invasive supraorbital approach which minimize the dissection and retraction of the brain, reduce operative time and blood loss with small incision and good cosmetic results.

AUTHORS CONTRIBUTIONS

This work was carried out in collaboration between the two authors. Authors, designed the study, Author, Mostafa M. Nabeeh wrote the protocol, managed the literature research, Author Ashraf Ezz ElDin revised the final manuscript. All surgical procedures were carried out by the same surgical team including the two authors. All authors read and approved the final manuscript.

ABBREVIATIONS

CT: Computerized Tomography.
CTA: Computerized Tomography angiogram.
DSA: Digital Subtraction Angiogram.
CSF: Cerebrospinal Fluid.
A. com: Anterior communicating artery
P. com: Posterior communicating artery

REFERENCES

1. Ausman JI: ISAT study: is coiling better than clipping? *Surg Neurol* 2003, 59:162-165.
2. Aydin IH, Takci E, Kadioglu HH, et al.: Pitfalls in the pterional approach to the parasellar area (review). *Minim Invasive Neurosurg* 1995, 38:146-52.
3. Beseoglu K, Lodes S, Stummer W, Steiger HJ, Hanggi D. The transorbital keyhole approach: early and long-term outcome analysis of approach-related morbidity and cosmetic results. Technical note. *J Neurosurg*. 2011, 114(3):852-856.
4. Bhatore HS: Transciliary supraorbital keyhole approach in the management of aneurysms of anterior circulation: Operative nuances. *Neurol India* 2009 Sep-Oct, 57(5):599-606.
5. Chalouhi N, Jabbour P, Ibrahim I, Starke RM, Younes P, El Hage G, Samaha E. Surgical treatment of ruptured anterior circulation aneurysms: comparison of pterional and supraorbital keyhole approaches. *Neurosurgery*. 2013 Mar, 72(3):437-41
6. Chen H.-C. and Tzaan W.-C: Microsurgical supraorbital keyhole approach to the anterior cranial base. *Journal of Clinical Neuroscience* 2010, 17 1510-1514
7. Czirjak S, Szeifert GT: Surgical experience with frontolateral keyhole craniotomy through a superciliary skin incision. *Neurosurgery*. 2001, 48(1):145-149; discussion 149-150.
8. Diringer MN: To clip or to coil acutely ruptured intracranial aneurysms: update on the debate. *Curr Opin Crit Care* 11:121-125, 2005.
9. Figueiredo EG, Deshmukh P, Nakaji P, et al.: The minipterional craniotomy: technical description and anatomic assessment. *Neurosurgery* 2007, 61:256-64
10. Figueiredo EG, Deshmukh P, Zabramski JM, et al.: The pterional-transylvian approach: an analytical study. *Neurosurgery* 2008, 62:1361-7.
11. Figueiredo EG, Welling LC, Preul MC, Sakaya GR, Neville I, et al.: Surgical experience of minipterional craniotomy with 102 ruptured and unruptured anterior circulation aneurysms. *Journal of Clinical Neuroscience* 2016, (27) 34-39
12. Fischer G, Stadie A, Reisch R, et al.: The keyhole concept in aneurysm surgery: results of the past 20 years. *Neurosurgery*. 2011, 68(1 suppl operative):45-51; discussion 51.
13. Flett LM, Chandler CS, Giddings D, Gholkar A: Aneurysmal subarachnoid hemorrhage: management strategies and clinical outcomes in a regional neuroscience center. *AJNR Am J Neuroradiol* 2005, 26:367-372,
14. Jallo GI, Bognár L: Eyebrow surgery: the supraciliary craniotomy: technical note. *Neurosurgery* 2006, 59 (1 Suppl):157-158.
15. Jane JA, Park TS, Pobereskin LH, Winn HR, Butler AB: The supraorbital approach: technical note. *Neurosurgery*. 1982, 11(4):537-542.
16. Kim Y, Yoo C J, Park CW, Kim MJ, Choi DH, Kim YJ, Park K: Modified Supraorbital Keyhole Approach to Anterior

- Circulation Aneurysms. *J cerebrovasc Endovasc Neurosurg*. 2016, 18(1)5-11
17. Madhugiri VS1, Ambekar S, Pandey P, Guthikonda B, Bollam P, Brown B, Ahmed O, Sonig A, Sharma M, Nanda A: The pterional and suprabrow approaches for aneurysm surgery: a systematic review of intraoperative rupture rates in 9488 aneurysms. *World Neurosurg*. 2013 Dec, 80(6):806-7.
 18. Molyneux A, Kerr R, Stratton I, Sanderock P, Clarke M, Shrimpton J, Holman R; ISAT Collaborative Group: International Subarachnoid Aneurysm Trial (ISAT) of neurosurgical clipping versus endovascular coiling in 2143 patients with ruptured intracranial aneurysms: a randomized trial. *Lancet* 2002, 360:1267-1274.
 19. Ormond DR, Hadjipanayis CG. The supraorbital keyhole craniotomy through an eyebrow incision: Its origins and evolution. *Minim Invasive Surg* 2013, 296469.
 20. Paladino J, Pirker N, Stimac D, et al.: Eyebrow keyhole approach in vascular neurosurgery. *Minim Invasive Neurosurg* 1998,41:200-3.
 21. Reisch R, Perneczky A, Filippi R: Surgical technique of the supraorbital key-hole craniotomy. *Surg Neurol*. 2003, 59(3):223-227.
 22. Schick U, Hassler W: The supraorbital approach—a minimally invasive approach to the superior orbit. *Acta Neurochir (Wien)* 2009, 151:605-611.
 23. Thaher F, Hopf N, Hickmann AK, Kurucz P, Bittl M, Henkes H, Feigl G: Supraorbital Keyhole Approach to the Skull Base: Evaluation of Complications Related to CSF Fistulas and Opened Frontal Sinus. *J Neurol Surg A Cent Eur Neurosurg*. 2015 Nov, 76(6):433-7
 24. Van Lindert E, Perneczky A, Fries G, Pierangeli E: The supraorbital keyhole approach to supratentorial aneurysms: concept and technique. *Surg Neurol* 1998 May, 49(5):481-9.
 25. Yasargil MG, Fox JL: The microsurgical approach to intracranial aneurysms. *Surg Neurol* 1975 Jan, 3(1):7-14.