



Bilateral traumatic basal ganglia haemorrhage, a rare entity. Experience at single institute with review of literature

Vibhu Shankar Parashar, Vivek Kumar Kankane,
Gaurav Jaiswal, Tarun Kumar Gupta

* Department of Neurosurgery, R.N.T. Medical College & M.B.
Groups of Hospital Udaipur (Rajasthan), INDIA

ABSTRACT

Aims. Traumatic basal ganglia haemorrhage is rare entity but post traumatic bilateral basal ganglia hematoma is even extremely rare and was earlier presented as case reports. Its incidence is about 3% after a closed head injury however, the incidence is higher in post mortem studies.

Material & Methods. Out of 1485 head injury patients admitted to our institute from January 2012 to January 2019, there were 9 cases of traumatic bilateral basal ganglia haemorrhage. The incidence of traumatic bilateral basal ganglia Haemorrhage in our series is 0.61% which is very less compared to previous literature.

Results. There were 6 males and 3 females; age ranging from 19 to 50 years (average 32 years). Patients with hypertension, history of drugs abuse, history of coagulopathy, with doubtful history of trauma or unknown mode of injury were excluded from the study. The mode of injury in all the patients was road traffic accidents. Average follow up was 9.54 months. Outcome was assessed by Glasgow outcome Score. In 8 out of 9 patients, outcome was good. One patient died. All the nine cases were managed conservatively.

Conclusion. We report nine cases from a single institute which to the best of our knowledge is the largest series in world literature. Prognosis is variable and dependent on many factors. The prognosis of TBGH is favourable if not associated with other disorders like hypertension, diabetes mellitus, and coagulation disorders or diffuse axonal injury.

INTRODUCTION

Traumatic basal ganglia haemorrhage (TBGH), are a rare entity and reported in only 3% of closed head injuries. [1] However autopsy series indicate a higher incidence ranging between 10% to 12%. [2,3] It is defined as a haemorrhagic lesion located in the basal ganglia or neighbouring structures, such as the internal capsule and the thalamus. It can be classified as "large," if it is more than 2cm in diameter or as "small" if it measures <2 cm in diameter. [2] Bilateral basal ganglia hematoma after trauma is extremely rare and is limited to case reports. The mechanism of TBGH is unclear but is thought to be due to shearing

Keywords
basal ganglia,
trauma,
bilateral,
haemorrhage



Corresponding author:
Vivek Kumar Kankane

R.N.T. Medical College &
M.B. Groups of Hospital
Udaipur, Rajasthan, India

vivekkankaneg@gmail.com

Copyright and usage. This is an Open Access article, distributed under the terms of the Creative Commons Attribution Non-Commercial No Derivatives License (<https://creativecommons.org/licenses/by-nc-nd/4.0/>) which permits non-commercial re-use, distribution, and reproduction in any medium, provided the original work is unaltered and is properly cited. The written permission of the Romanian Society of Neurosurgery must be obtained for commercial re-use or in order to create a derivative work.

ISSN online 2344-4959
© Romanian Society of
Neurosurgery



First published
September 2019 by
London Academic Publishing
www.lapub.co.uk

of lenticulostriate or anterior choroidal blood vessels due to the violent acceleration deceleration brought about by a high velocity injury. [2,4] Since Basal ganglia hematoma can be due to trauma and thus takes importance in the medico legal cases where bleeding may be attributed to a non-traumatic cause. Thus, the identification of TBGH is of prime relevance.

MATERIAL AND METHODS

Out of the 1485 traumatic head injury patients, the study group comprised of nine patients of TBGH identified on the basis of initial Noncontrast CT (NCCT) head, admitted from January 2012 to January 2019 in the Department of Neurosurgery at R.N.T. Medical College and M.B. Hospital, Udaipur, Rajasthan. A written informed consent was taken from all patients, as applicable. Hypertensive patients, drugs abuse history, history of coagulopathy with doubtful history of trauma or unknown mode of injury was excluded from the study. The diagnosis of TBGH was made on the basis

on NCCT head and Outcome was assessed by Glasgow outcome score.

RESULTS

Total head injury patients admitted to the hospital were 1485 among which nine patients of Traumatic bilateral basal ganglia Hemorrhage were identified and thus incidence of Bilateral TBGH in our series is 0.61% (nine patients) which is very less as compared to previous literature. There were 6 males and 3 females; age ranging from 19 to 50 years (average 32 years (Table 1)). All patients had sustained road traffic accidents. NCCT head was done in all the patients [Figure -1, 2, 3, 4 & 5] after initial resuscitation. GCS at admission were 7 to 12 (mean 10.0). (Table 1) All the patients were managed conservatively. Outcome was assessed by Glasgow outcome Score (Table 2). Outcome were labeled as good (GOS-5, 4) and poor (GOS1-3). The average follow up was 9.54 months. In 8 out of 9 patients the outcome was good. One patient had poor outcome and died.

TABLE 1. Demographic analysis, management and outcome of all patients

S.no	Age (yr)	Gender	Mode of injury	GCS at admission	Focal neurological deficit	Management	Outcome measured by GOS
1	19	Male	RTA	12	No	Conservative	5
2	45	Female	RTA	9	Left sided hemiparesis	Conservative	4
3	24	Male	RTA	10	Left sided hemiparesis	Conservative	5
4	50	Male	RTA	7	Left sided hemiparesis	Conservative	1
5	20	Male	RTA	9	Right sided hemiparesis	Conservative	5
6	40	Male	RTA	9	Left sided hemiparesis	Conservative	5
7	35	Female	RTA	10	No	Conservative	5
8	25	Female	RTA	12	No	Conservative	5
9	30	Male	RTA	12	No	Conservative	5

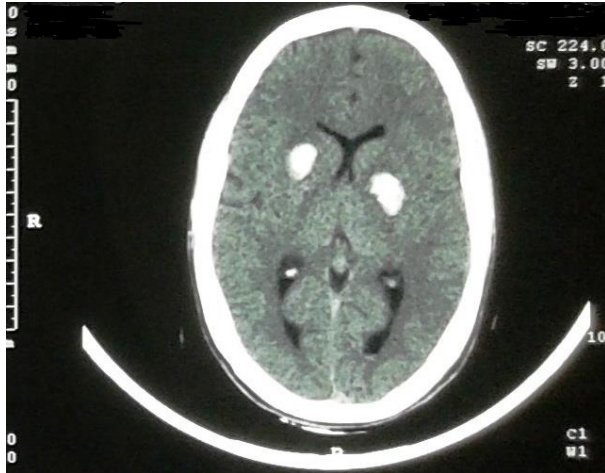


IMAGE 1. NCCT head shows hemorrhage in bilateral basal ganglia region, with involvement of right anterior limb of internal capsule.

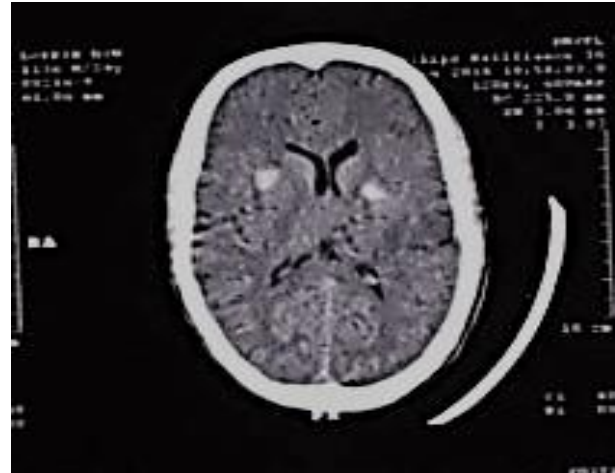

IMAGE 2. NCCT head shows hemorrhage in bilateral basal ganglia, with left frontal depressed fracture with underlying small left frontal contusion.

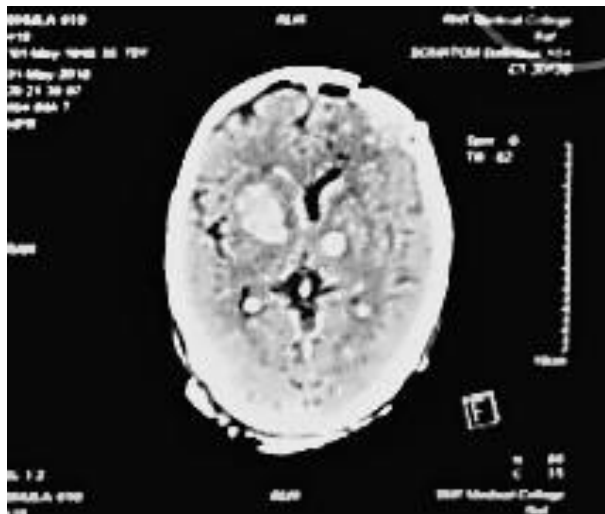


IMAGE 4 & 5. NCCT head shows hemorrhage in bilateral basal ganglia region with subdural hemorrhage in right frontotemporoparietal region and subarachnoid hemorrhage along right frontal and temporal sulci and gyri.

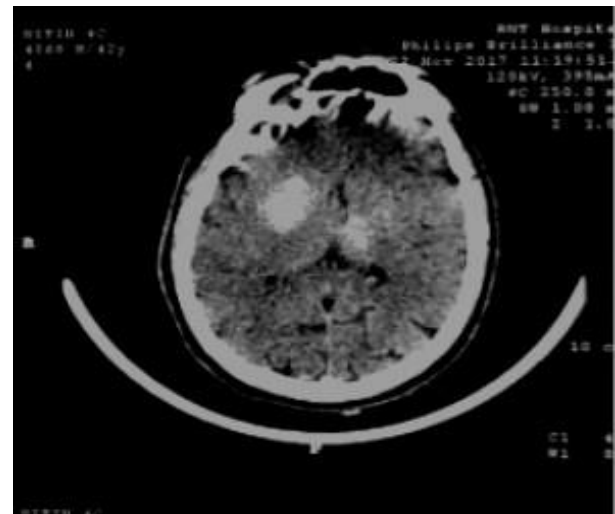
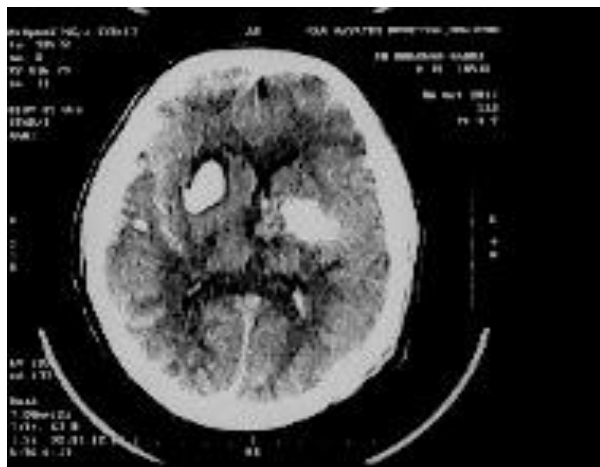

IMAGE 3. NCCT head shows hemorrhage in bilateral basal ganglia region with fracture of outer table of right frontal sinus.

TABLE 2: Glasgow outcome score (GOS)

GOS Score	Functional status
5	Resumption of normal life, there may be minor neurological and or psychological deficit
4	Able to work in a shattered environment and travel by public transportation
3	Dependent for daily support by reason of mental or physical disability or both



2	Unresponsive for weeks or months or until death
1	Death

DISCUSSION

The TBGH is a rare entity with an incidence rate of about 3% in closed head injuries. The exact pathogenesis of basal ganglia hematoma is unclear; however, it is suggested that a strong impact over the vertex, forehead, or occipital region, then shearing force causes the brain to be displaced through the tentorial notch. This results in stretching and tearing of the vessels resulting in hematoma. [2] The sudden acceleration/deceleration forces at the time of injury result in shearing strain over the lenticulostriate and anterior choroidal vessels leading to bleeding. Mosberg and Lindenberg, in an autopsy of fatal head injury patient, demonstrated massive hematoma in the pallidum and ruptured twig of the anterior choroidal artery. [4]

Since basal ganglia region is predisposed to hypertensive bleed, at times, it becomes difficult to distinguish between hypertensive and traumatic hemorrhage. It has been suggested that the TBGHs are small, multiple, rarely bilateral, located in the zone of lentiform nucleus and external capsule, whereas spontaneous hemorrhages are large, solitary, and located mainly in the region of thalamus and internal capsule. [5, 6] In a known hypertensive patient with head injury and findings of basal ganglia bleed, it is imperative to ascertain the sequence of events. This may be a medico legal issue; as to whether the patient had spontaneous basal ganglia bleed leading to the subsequent head injury or it was the head injury, which caused the basal ganglia hematoma.

In all our patients, there was a definite history of trauma with no antecedent history of preexisting medical illnesses and bleeding diathesis, thus the bilateral basal ganglia bleed seen on CT/MRI scans was traumatic in nature. As our patients had small bilateral TBGH with volume <25 mL and showed gradual improvement of GCS with medical management, they were managed conservatively.

Treatment is based on protocol as for intracranial hematoma taking into account the neurological status, presence of mass effect and response to other means of controlling intracranial pressure.

Treatment options for TBGH include conservative, open surgery, CT guided stereotactic or ultrasound guided aspiration. Katz et al [1], Bhargava et al [6], Jang et al [7] and Kimura et al,[8] have reported favorable outcomes for TBGH with conservative management. Boto et al advised surgical evacuation of all lesions with volume >25 ml; however, poor outcome was noted in most of these patients. [3] Boto et al noted that 84% of surgically managed patients had an unfavorable outcome. Surgical evacuation entails approach to the hematoma via the thalamo-ganglionic region, leading to further damage of the eloquent areas resulting in possible poor outcome. Surgical management was done in patient described in case report by Yanaka et al.[9] Craniotomy was performed in patients reported by Pandey et al [10],Jain et al[11] and Calderon et al [12].

The outcome of TBGH has been found to be variable. Amongst 37 patients studied by Boto et al.59%died, 5% were vegetative, 19% experienced severe disabilities, and 16% made a favorable recovery.[3] Katz et al.[1], Bhargava et al [6], Kaushal et al [13] and Zhang et al [14] have also reported good prognosis for TBGH. Kankane et al reported bilateral traumatic basal ganglia bleed and both the patient managed conservatively and outcome was good and no focal neurological deficit. [15] Zhang YX, et al reported single case of 45year female of traumatic bilateral traumatic basal ganglia bleed and patient managed conservatively and outcome was good. [14]In our study, all the patients were managed conservatively and in 8 out of 9 patients the outcome was good. One patient had poor outcome and died. Large size, associated coagulation disorders, DAI, presence of other bleeds like intraventricular of brain stem hemorrhage, age >60, abnormal pupillary response, abnormal motor response to pain, and severe head injury are reported to be indicators for poor prognosis.[1,2,5,16,17]

This rare entity has been previously reported in literature by Yanaka et al (2 cases), Jang et al (1 case), Kaushal et al (1 case), Bhargava et al. 1 (1 case), Jain et al (1 case), Pandey et al (1 case), Calderon et al (1 case), Kankane et al (2 cases) and Zhang et al (1 case). (Table 3)

TABLE 3. Review of literature with previously reported cases

No	author	Year	Total case	Age	Gender	Diagnosis	Management	Out come
1	Yanaka et al	1991	2	17 75	Male Male	TBBGH TBBGH	Surgical	Good
2	Jang et al	2007	1	50	Male	TBBGH with SAH	Conservative	Good
3	Kaushal et al	2011	1	42	Male	TBBGH	Conservative	Good
4	Bhargava et al	2012	2	25 50	Male Male	TBBGH TBBGH	Conservative	Good
5	Jain et al	2013	1	38	Male	TBBGH with epidural hematoma	Craniotomy	Good
6	Pandey et al	2014	1	37	Male	TBBGH with subdural hematoma	Craniotomy	Poor
7	Calderon et al	2014	1	28	Male	TBBGH with epidural hematoma	Craniotomy	Death
8	Kankane et al	2016	2	20 40	Male Male	TBBGH with hemiparesis	Conservative	Good
9	Zhang et al	2016	1	45	Female	TBBGH	Conservative	Good
10	Present study	2019	9	19-50 (range)	6-males 3-females	4-TBBGH 5- TBBGH with hemiparesis	9--Conservative	8-Good 1-Death

CONCLUSION

Traumatic BGH is uncommon, and bilateral BGH is very rare entity with only few cases reported in world's literature. We report nine cases from a single institute which to the best of our knowledge is the largest series in world literature. Prognosis is variable and dependent on many factors. The prognosis of TBGH is favorable if not associated with other disorders like hypertension, diabetes mellitus, and coagulation disorders or diffuse axonal injury. TBGHs are compatible with a favorable recovery if

present in isolation and not associated with damage to other cortical and sub cortical structures. Patients with isolated TBGH do well with conservative management.

REFERENCES

1. Katz DI, Alexander MP, Seliger GM, Bellas DN. Traumatic basal ganglia hemorrhage: Clinicopathologic features and outcome. *Neurology*. 1989;39:897-904.
2. Adams JH, Doyle D, Graham DI, Lawrence AE, McLellan DR.

- Deep intracerebral (basal ganglia) haematomas in fatal non-missile head injury in man. *J Neurol Neurosurg Psychiatry*. 1986;49:1039-43.
3. Boto GR, Lobato RD, Rivas JJ, Gomez PA, de la Lama A, Lagares A. Basal ganglia hematomas in severely head injured patients: Clinoradiological analysis of 37 cases. *J Neurosurg*. 2001;94:224-32.
 4. Mosberg WH, Lindenberg R. Traumatic hemorrhage from the anterior choroidal artery. *J Neurosurg* 1959 Mar;16(2):209-221.
 5. Kumar S, Jha D, Abbey P, Mishra V, Handa A. Outcome of Traumatic Basal Ganglia Hemorrhage. *Internet J Neurosurg*. 2009:61
 6. Bhargava P, Grewal SS, Gupta B, Jain V, Sobti H. Traumatic bilateral basal ganglia hematoma: a report of two cases. *Asian J Neurosurg* 2012 Jul;7(3):147-150.
 7. Jang KJ, Jwa CS, Kim KH, Kang JK. Bilateral traumatic hemorrhage of the basal ganglia. *J Korean Neurosurg Soc* 2007 Apr;41(4):272-274.
 8. Kimura M, Sobata E, Suzuki S, Nonogaki Y, Iwabuchi T. Traumatic hematoma in the basal ganglia (caudate) with favorable prognosis: report of two cases. *No ShinkeiGeka* 1994 Feb;22(2):155-158.
 9. Yanaka K, Egashira T, Maki Y, Takano S, Okazaki M, Matsumaru Y, Kamezaki T, Ono Y, Nose T. Bilateral traumatic hemorrhage in the basal ganglia: report of two cases. *No ShinkeiGeka* 1991 Apr;19(4):369-373.
 10. Pandey N, Mahapatra A, Singh PK. Bilateral large traumatic hemorrhage of the basal ganglion. *Asian J Neurosurg* 2014 Oct-Dec;9(4):240.
 11. Jain SK, Sundar IV, Sharma V, Prasanna KL, Kulwal G, Tiwari RN. Bilateral large traumatic basal ganglia haemorrhage in a conscious adult: a rare case report. *Brain Inj* 2013;27(4):500-503.
 12. Calderon-Miranda WG, Alvis-Miranda HR, Alcalá-Cerra G, Rubiano AM, Moscote-Salazar LR. Bilateral Traumatic Basal Ganglia Hemorrhage Associated With Epidural Hematoma: Case Report and Literature Review. *Bull Emerg Trauma*. 2014;2(3):130-132.
 13. Kaushal R, Kataria R, Gupta A, Sinha V. Traumatic bilateral (mirror image) basal ganglia bleed. *Indian J Neurotrauma* 2011 Dec;8(2):109-110.
 14. Zhang YX, Wei SQ, Xing YY, Liu Q, He WJ Bilateral traumatic hemorrhage of the basal ganglia. *Chin J Traumatol*. 2016 Aug 1;19(4):247-8.
 15. Kankane VK, Gupta TK, Jaiswal G. Traumatic bilateral basal ganglia bleed: A report of rare two cases and review of the literature. *Asian J Neurosurg* 2016;11:457.
 16. Fujioka M, Maeda Y, Okuchi K, Kagoshima T, Taoka T. Secondary change in the substantia nigra induced by incomplete infarct and minor hemorrhage in the basal ganglia due to traumatic middle cerebral arterial dissection. *Stroke* 1999 Sep;30(9):1975-1977.
 17. Lee JP, Wang AD : Post-traumatic basal ganglia hemorrhage: analysis of 52 patients with emphasis on the final outcome. *J Trauma* 31 : 376380, 1991.-2.