

Article

Use of high performance technologies in the treatment of chronic neuropathic pain

Ion Streltov, Marcela Nour, Madalina Radu, Mihai Malcoci, Oana Bisoc, Ecaterina Olaru, Iulia Aldea
ROMANIA



DE GRUYTER
OPEN

Use of high performance technologies in the treatment of chronic neuropathic pain

Ion Streltov¹, Marcela Nour², Madalina Radu³, Mihai Malcoci⁴,
Oana Bisoc⁵, Ecaterina Olaru⁶, Iulia Aldea⁷

¹Primary Neurosurgeon, Clinical Hospital Emergency "Prof. Dr. N. Oblu" Iasi, ROMANIA

²Neurosurgeon, Clinical Hospital Emergency "Prof. Dr. N. Oblu" Iasi, ROMANIA

³Resident Plastic Surgery, "Sf. Spiridon" Hospital Iasi, ROMANIA

⁴Resident Neurosurgery, Clinical Hospital Emergency "Prof. Dr. N. Oblu" Iasi, ROMANIA

⁵Primary neurologist, Clinical Hospital Emergency "Prof. Dr. N. Oblu" Iasi, ROMANIA

⁶Primary Anesthesia-Intensive Care, Clinical Hospital Emergency "Prof. Dr. N. Oblu" Iasi, ROMANIA

⁷Principal Psychologist, Clinical Hospital Emergency "Prof. Dr. N. Oblu" Iasi, ROMANIA

Abstract: Spinal cord neurostimulation is a minimally invasive treatment method for chronic neuropathic pain that is refractory to treatment, and is part of top technology in field. Relatively recent introduction of this method in the Neurosurgery Clinic "Prof. Dr. N. Oblu" of Iasi has aligned the clinic's therapeutic arsenal to world standards. This has made it possible to treat in Romania a category of patients who would be treated abroad until now. Our clinic has entered the "National Program for diagnostic and treatment using high performance equipment" - Subprogram of treatment of neuropathic pain by implant of a spinal cord neurostimulator and is currently the only one in Romania where this treatment can be done. This represents a new step in the transformation process of the Clinical Hospital Emergency "Prof. Dr. N. Oblu" Iasi in a real Center of Excellence in the field Neurosurgery. The team dealing with the implant consists of 3 neurosurgeons, a neurologist, a psychologist and an anesthetist, trained in a specialized foreign center.

Key words: spinal cord stimulation, back pain, central nervous system stimulation, complex regional pain syndrome, failed back surgery syndrome

History

Electrotherapy of pain by neurostimulation began shortly after in 1965 R.Melzack and P. Wall proposed gate control theory (theoretical basis) spinal cord neurostimulation, wherefore they received the

Nobel Prize [1]. According to this theory, nerves that carry painful peripheral stimuli, touch sensations and vibration end in the dorsal horn (the gate) of the spinal cord. Thus, it has been hypothesized that this entry may be manipulated to "close the gate", thus

blocking the spread of the painful impulse. On this theory, in 1971, Shealy et al. [2] performed the first implant of the spinal cord neurostimulator in the treatment of chronic pain. Shimogi et al [3] published the analgesic effect of neurostimulation. Later spinal cord neurostimulation developed very rapidly over the last two decades by introducing implantable neuropeacemakers using guided surgical systems. [4]. Every year, over 50,000 neurostimulation implants are performed worldwide. [5].

Chronic neuropathic pain

Pain is “An unpleasant experience that we primarily associate with tissue damage or describe in terms of tissue damage.” (International Association for the Pain Study (IASP, 1986)). According to statistics, in Europe 1 out of 5 patients (70 millions of adults) suffer from chronic pain [6]. If in most patients the pain is the symptom of a disease, this is not always true. In 7 - 8% of the patients the pain persists even after removing the trigger factor. This pain ceases to be one symptom, becoming itself a disease. In recent years, medicine has begun to recognize that chronic pain is a self-esteem disease, after a long time it was considered a psychological and overlooked problem. This type of pain is refractory to common medication (non-steroidal analgesics, anti-inflammatory drugs, opioids), physiotherapy and infiltration local. Therefore, it requires a totally different approach to traditional treatment strategies. The difficulty of treating neuropathic pain is also explained by the lack of knowledge the mechanisms that trigger it. Up to now, at least

20 such pathophysiological mechanisms have been known. Neuropathic pain is caused by a decrease in the excitability threshold of a receptors, poor processing of nociceptive stimuli (neurons become over-excited, continuing to emit electrical impulses long after the trigger factor has been removed), disruption of the neuronal control mechanism (ineffective cells with inhibitor effect on it), etc.

The pain process goes through 4 stages: transduction, transmission, perception, and modulation. Factors stimulants (ATP, GABA, glutamate, nitric oxide, prostaglandin and substance P mediators) irritate the free nervous terminations that respond to pain, and transformation into the electrical signal by transduction appears. This signal enters the spinal cord through the posterior horns and propagates ascending to the brainstem, and from there to the limbic system and thalamus. Here the signals of pain are processed and contextualized in the perception process. Through modulation, the brain can alter the transmission of subsequent nerve impulses by amplifying or reducing the release of neurotransmitters.

Symptomatology of chronic neuropathic pain

- Due to the long-term nervous disorders, the symptoms are more important in the distal extremities (soles, palms) than in thighs or arms.

- no visible damage
- dysaesthesia - an alteration of sensitivity leading to spontaneous unpleasant sensations such as those tingling, sting and burning;
- allodynia - pain caused by stimuli that are normally painless. This stimulus can be touch

(for example, touching a feather) or heat (when the pain is caused by a temperature that would not normally be disturbing);

- a paradoxical combination of loss of sensitivity and hyperalgesia of painful area, the presence of paroxysms

- autonomic hyperactivity - abnormal blood flow, hyperthermia and skin sweating accompany the painful sensation and contribute to its persistence (for example, in complex regional pain syndromes).

Chronic neuropathic pain is refractory to treatment with analgesics or opioids, but it improves with antidepressants, antiepileptic and vasodilators, as well as application to the painful place of hot-cold compresses.

Spinal cord neurostimulation

a) Indications:

- FBSS - Failed Back Surgery Syndrome (FBSS);
- Regional Complex Pain Syndrome (CPRS) type I (also called sympathetic dystrophic reflex) and type II (also called causal);
- Diabetic neuropathy;
- Neuralgia postherpetica.
- Amyloidosis neuropathy;
- Neuropathy from Fabry disease;
- Polyradiculoneuritis Guillain-Barré;
- Neuropathy from peripheral vascular disease;
- Lyme disease (Borreliosis, 1000-sided illness);
- Toxic (ethanolic) neuropathy;
- Neuropathy from vitamin deficiencies in group B;
- Ghost pain in vertebral-medullary trauma;
- Pain in oncology pathology; and so on

b) Contraindications:

- The presence of other electrical devices in the body (cardiac pacemaker, cochlear implant), because the electrical impulses of the neurostimulator can interfere with the electrical impulses of these devices;
- Serious heart disease (class III-IV N.Y.H.A., valvular stenosis, angina pectoris);
- Blood clotting disorders - Patients with chronic anticoagulant therapy present an increased risk of developing peridural hematomas at the implant site and spinal cord compression, sometimes with motor deficits;
- Psychiatric disorders, drug abuse and / or addiction;
- Trophic or gangrene ulcers;
- Local infections;
- Immune system deficiencies;
- Patient incapacity to use implanted device and inability to present at control visits;
- Age under 18.

Female candidates with fertile potential should have a urine pregnancy test and use contraceptive methods recommended by the investigator.

c) The neurostimulation system

It includes several components: electrode, extension, impulse generator (trial and permanent), patient remote control, physician programmer.

Stimulation electrode. There are several types of electrodes that differ in number of contacts, stimulation contact length, contact distance etc. We used electrodes with lengths between 50 and 75 cm and diameter of 1.5 mm, with 8 contacts and resistance up to 250Ω.



Figure 1 - Different types of stimulation electrodes

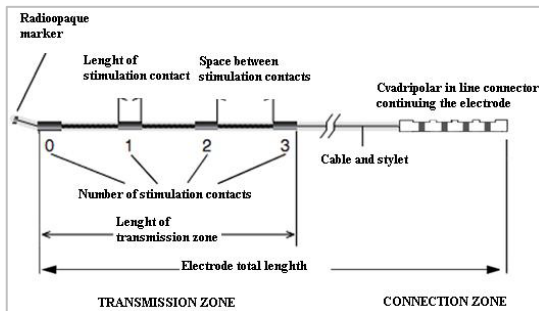


Figure 2 - Stimulation electrode – schema

The extension connects the stimulating electrode to the impulse generator.




Figure 3 – Extension



Figure 4 - External generator (trial)

The pulse generator is a device designed to provide electrical impulses to the stimulating electrode. Includes a battery with at least 2.5 Ah, which generates pulses with maximum voltage up to 10.5 volts, frequency between 50 and 120 Hz and duration between 100 and 500 msec. The generator stores the stimulus program set up by the physician only from the amplitude, frequency, duration of the impulse, and the order of the stimulation contacts on electrode. It also memorizes the start and stop times of the generator, as well as the changes of the amplitude performed by the patient via the remote control.



Figure 5 - Compatible IRM Impulse Pump Generator

The life span of the power supply is 3 to 5 years and can be replaced after consumption. New generators are IRM compatible, rechargeable and automatically adjusts their pulse voltage depending on the position of the body.

Remote. It is used by the patient to transmit and receive wirelessly data to the spinal cord neurostimulator. Through this, the patient can optimize settings, can completely reset or shut down the spinal cord neurostimulator in case of fluctuations feeding or accidental exposure to a powerful electromagnetic field, adjusts the amplitude of the pulse based on the limits prescribed by the physician. Using the remote control the patient can check the status of the spinal cord neurostimulator battery located in the generator pulses, patient remote control battery and confirmation that the neurostimulator has received the information from the remote control.

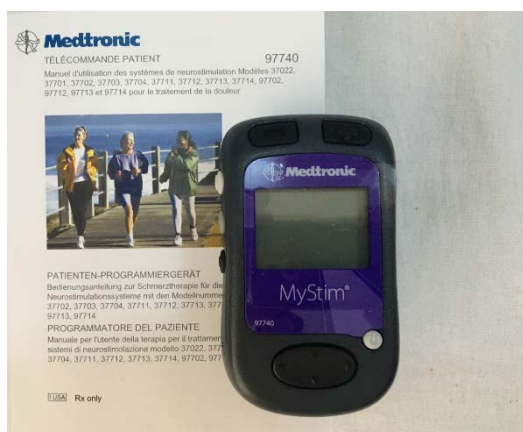

Figure 6 - Patient remote control

N-Vision is a small portable computer specializing in the programming of generators pulses. The data transmission between N-

Vision and the generator is 2.4 GHz. Through the programmer, the physician sets up a stimulus program adapted to each patient by modifying the parameters of these impulses to the maximum therapeutic efficiency and order electrode stimulation contact.



Figure 7 - The N'Vision programmer

The mechanism of action of the spinal cord neurostimulator consists in blocking the transmission painful impulses in the upward spinal tracts to the thalamus and limbic system, where integration, analysis and awareness of suffering is taking place. The effect of neuromodular, which consists of suppressing the release of inhibitory chemical neuromodulators suppress the transmission of pain. This mechanism of functioning also derives from the fact that the pain is suppressed minutes, hours to even days after stopping the pacemaker. This could be due to the fact that the spinal cord neurostimulation increases the synthesis of the GABA

neurotransmitter, which has an effect of removing amino acid excitators.

Until the introduction of spinal cord neurostimulation, the only way to resolve pain was surgery to discontinue the paths carrying the pain signals. But the key success was the finding of carrier tracts, often the intervention being a failure.

Objectives

This study presents the preliminary results of the stimulation of the posterior tracts of spinal cord via neurostimulatory implant in chronic neuropathic pain, performed in the Clinic of Neurosurgery Iasi.

Selection of patients

From 2015 until now in our clinic we have performed 36 implant procedures at 22 patients: 14 women and 8 men between 40 and 76 years of age with an average disease progression of 2.8 years and an average of 2 to 3 neurosurgical interventions per patient. 20 cases were with failed back surgery syndrome (FBSS) after repeated neurosurgical interventions for both herniated lumbar discs, as well as after decompression in foraminal and / or spinal stenosis, degenerative spondylolistezis, peridural and radicular fibrosis, 1 case with ghost pain after dorsal inferior vertebromedular trauma, 1 complex complex regional posttraumatic pain syndrome (CRPS) type I (sympathetic dystrophic reflex) and a case of persistent pain after repeated interventions for trigeminal neuralgia. The implant was done in 2 steps - test stimulation and permanent implant.

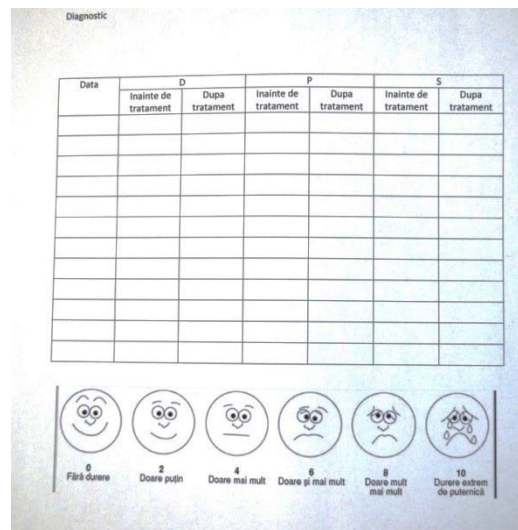


Figure 8 - VAS scale

Neurological consult. The vast majority of cases selected for the implant were patients with the failed back surgery syndrome, with outstanding pain, irradiated in the inferior limb neuropathy-like (spontaneous, non-effortless, with paroxysmal exacerbations), with an intensity of over 7 in the analog-visual scale (VAS), measured 3 times a day within 3 days. All the patients did medical treatment, physiotherapy and spinal infiltration up to 6 months. There were followed the beginning, character, duration, intensity, territory and evolution of pain. The essential features of this type of pain was allodynia, hyperalgesia and hyperpathia. The neurological examination showed that these clinical signs coexisted frequently in our cases and were very difficult to differentiate.

Psychological consultation has been done in all patients, primarily to exclude any psychological problem that could affect the outcome. The most common effects secondary

to the neuropathic pain were depression, anxiety, somatization, sleep, family and / or marital problems. Cases with obvious signs of somatization of pain and those with a history of suicidal ideas were sent to psychiatric examination and excluded from the batch. It was important to establish realistic expectations by the patient: the efficiency of stimulation between 40% and 60% of the cases, and the efficiency criterion - the reduction by at least 50% of the intensity pain and decreased analgesic drug intake. It is also important to grant support and encourage pain patients.

The Roland-Morris Questionnaire (2004)

The patient draws on the dermatomus distribution charts in different colors the location of the pain, a numbness or burning feeling.

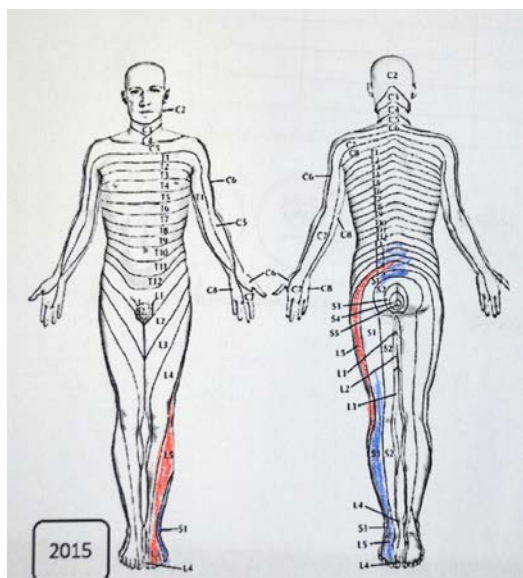


Figure 9 - These charts are very useful intraoperatively for covering painful areas

Patients with inflammatory and purulent skin rashes, as well as those with local irritation secondary to various physiotherapeutic procedures located even at a distance from the placement of the electrode impose the delay of the surgery until these are resolved.

Preparing the patient for the implant. The selected cases for the implant benefited from spinal MRI exam, primarily to exclude injuries that would require reintervention, the level of the conus medullaris.

Sometimes we use CT to evaluate the anatomical area of the implant (highlighting the possible spinal abnormalities, narrow spaces, etc.) that could pose technical problems in performing the implant safely.

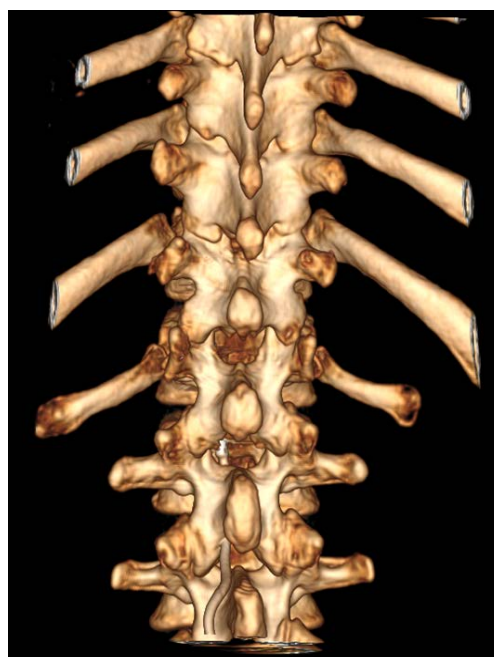

Figure 10 - CT reconstruction for the anatomical evaluation of the implant area

Provisional implant technique

The patient's position on the operative table is ventral decubitus. Anesthesia is intravenous, the patient being conscious throughout the intervention. Radiological survey a projection of laryngeal apophyses L3-L4.

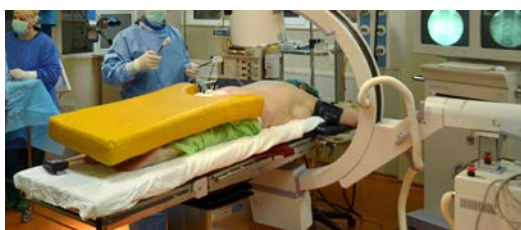

Figure 10 - Set up the implant room

After local anesthesia with Xilina 1%, vertical cutaneous incision is performed on a length of 3-4 cm, on the median line. Touhy needle (hypodermic needle, slightly curved at the end, also used in implantation of epidural catheters) is inserted at 45° from the spinal axis, obliquely to the median line, on left or right to spinous apophyses (depending on lateral pain) until cessation resistance after passing the yellow ligament. Typically the channel is entered through the L2-L3 lamina below the level of the conus medullaris (to avoid direct lesion). After extraction the stylet through the needle lumen, one inserts the electrode into the posterior epidural space. The electrode must cross at least 4 vertebrae from the place of introduction to the stimulation area.

The electrode is driven under C-ARM control to the desired location, depending on the location of the pain area in the lower limbs (usually up to the back of the D9-D10 vertebral body).

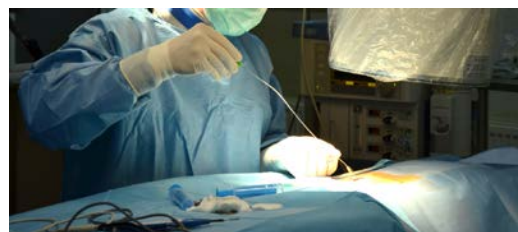

Figure 11 - Insertion of the electrode to the posterior epidural space

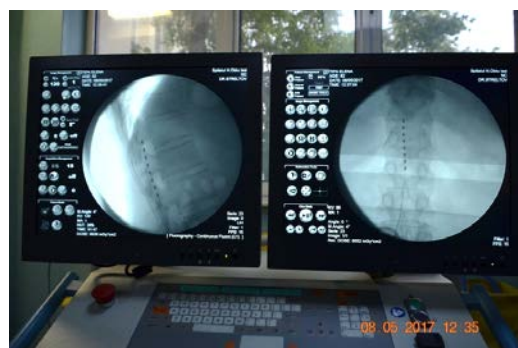

Figure 12 - Radiological control of correct positioning of the electrode

The electrode is connected via extension to N'vision programmer and the unscrubbed physician produces the first electrostimulation of the posterior cords. The patient indicates the area the painful condition is covered by paresthesia ("tingling") and decreased intensity of pain.

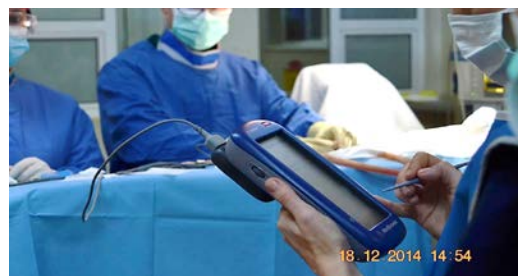

Figure 13 - Intraoperative medullary stimulation

After radiological confirmation of correct electrode position and good stimulation intraoperatively, the extension is transcutaneously exteriorized on the lateral side of the trunk and sutured to the tegument. The wounds are sutured, and the distal end of the extension connects to the temporary impulse generator. The whole system is attached to the skin with adherent drape.

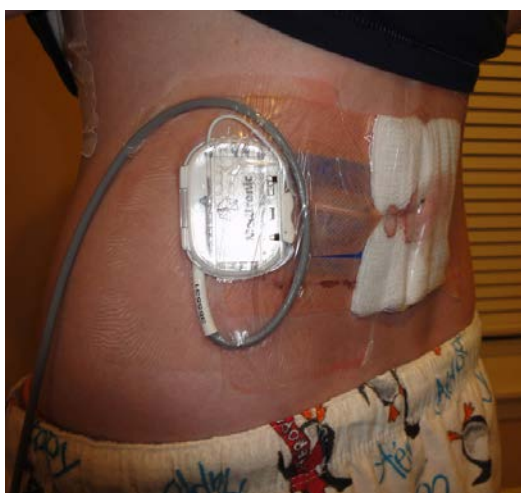

Figure 14 - Externalization of the extension and connection to the external generator

Suture suppression is done after 6-7 days postoperatively. For 2 to 3 weeks the patient is in the neurostimulation test period. The patient is called for visits repeatedly to adjust the electrical parameters of impulse by intensity, voltage, amplitude and its duration. Depending on the position of the body (bent, sitting or orthostatism) the electrode can move farther or closer to the back of the spinal cord requiring manual adjustment to the patient's power of impulse for an effective stimulation of the spinal cord. The patient is taught to

control his own pain by using his personal remote depending on his daily activities.

Security measures. Patients have forbidden activities involving sudden shocks, twists or excessive trunk flexion, as it may cause disconnection or breakage of the components system. This can lead to intermittent stimulation or even loss of stimulation. Special warnings and increased attention are required when a defibrillation is required, electrocauterizations, MRI exams, radiofrequency ablation and endoscopy for therapeutical purpose, as powerful sources of electromagnetic interference can cause overheating the components of the neurostimulation system with tissue damage. There can occur instantaneous increases in stimulation intensity or intermittent stimulation, and the patients may feel vibrations or shocks, return to initial symptoms or even need reprogramming the neurostimulator. Although it can create discomfort, all of this does not lead to device malfunction or serious injury to the patient.

The permanent implant technique

If during the test stimulation the pain intensity decreased by at least 4 to 5 points on pain scale or more than half of its intensity with gradual decrease in medication doses, is decided to perform the permanent implant. It involves the replacement the external provisional generator with a sterile one. The place where the generator will be implanted must either be easily accessible to the patient for easy synchronization with personal remote control. The exact location of the implant is established preoperatively in agreement with

the patient to avoid it overlaps with the level at which he usually wears his belts / trousers. Internalisation of the sterile generator is done subcutaneously, usually on the anterior face of the abdomen, paraumbilical left.

The permanent implant is done under general anesthesia via oro-tracheal intubation. The position of the patient on the operating table is in lateral decubitus, with the painful side up. Preparation the operator field is similar to the provisional implantation technique with the reference that apart from the lumbar region it will disinfect the anterior face of the abdomen, where the sterile impulse generator is to be implanted.

The wound is reopened where the connection between the electrode and the extension was made. One disconnects and suppress the extension with the non-sterile external generator. Another extension is added, sterile, that is connected to the electrode implanted in the previous intervention. Extension cable is tunned subcutaneously to the anterior face of the abdomen, where it connects to the sterile generator and itself inserted into the subcutaneous paraumbilical pocket.

The generator is fixed with non-resorbable sutures to the abdominal muscle. The wound will be sutured with vicryl 3.0 (skin Ethilon 3.0).

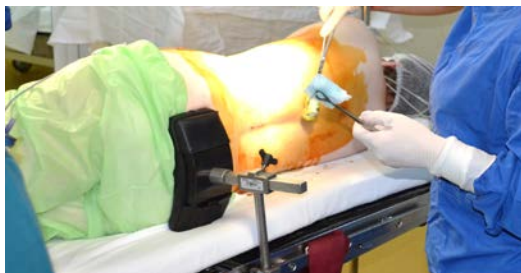


Figure 15 - Prepare the operator field for the permanent implant



Figure 17 - Connect the extension to the generator

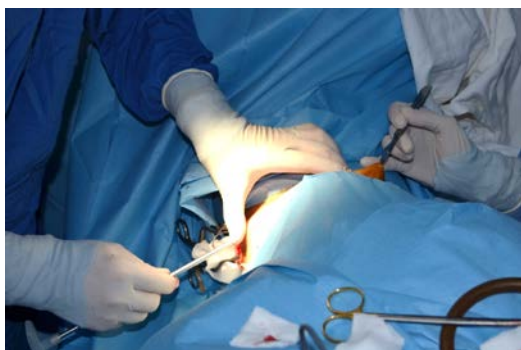


Figure 16 - Subcutaneous tunneling of the extension

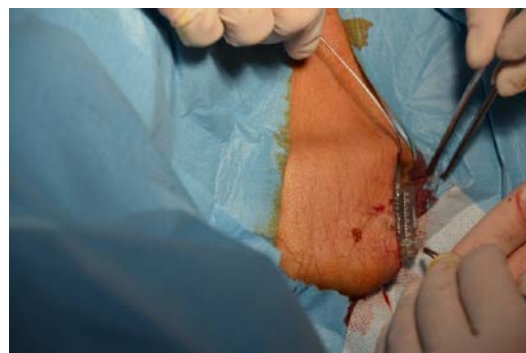

Figure 18 - Internalizing the generator in the paraumbilical pocket

Surgical Electrodes in Chronic Pain Management. Another type of electrodes we used are the Specify™ surgical electrode. It has the shape of a 16-palletized blade programmable independently and assigned in 3 rows 5-6-5.

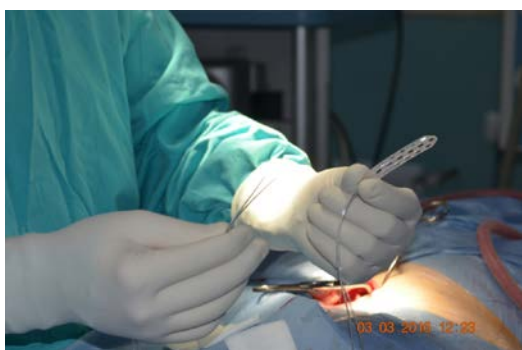


Figure 19 - Specify™ Surgical Electrodes

This type of electrode offers several options and configurations for customized therapy individually to each patient. First, it is more effective in cases of associated irradiated pain with vertebral syndrome. The Specify™ electrode is implanted after a good stimulation with percutaneous electrode during the test period. The surgical implant is made with general anesthesia after bilateral traction of muscle masses and lower partial lamina resection at level D11.

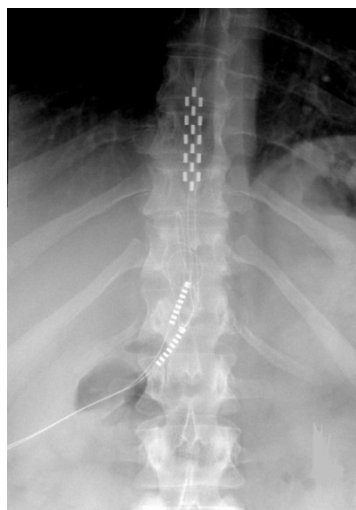

Figure 20 - Radiological control - Specify™ electrode positioned at D9

Insert the electrode into the D9 - D10 retrodural space. Otherwise - connections to the generator are performed via the extension – similar to the technique of implant of the percutaneous electrode. The surgical electrode has the advantage of a larger coating and the minimal risk of slipping from the percutaneous space, but has the greater risk of septic complications. From the point of view of battery consumption, the surgical electrode has one much higher than the percutaneous yield, being the electromagnetic field at the surgical one is oriented in one direction, while the percutaneous electrode is directed at 360°.

Intraoperative incidents: Of the 30 procedures performed in 2 cases we found the presence of CSF in the penetration of the yellow ligament with the Touhy needle. Both cases required 2 - 3 days of bed rest, the period of postfunctional cephalalgia. 2 cases with the migration of the electrode required repositioning, 3 cases of remediation with the

replacement of the damaged elements of the circuit and a case of infection with the staphylococcus aureus required system suppression.

Results

The effectiveness of spinal cord neurostimulation was based on average comparison results of pain intensity before and after implant, performed 3 times a day. We have noted a reduction in pain intensity on average by 4.7 p. on the VAS scale and improvement in functional capacity and quality of life in 67% of cases. The best results were obtained in patients aged 20-60 years with a disease progression up to 2 years, with a maximum of 2 to 3 neurosurgical interventions on the spine, prevalence of radicular syndrome on the vertebral syndrome and with minimal psychological changes.

Perspectives: We intend to extend the procedure's indications to neuropathies of various etiologies, stimulation of sacral nerve in sphincter disorders, gastric and colon stimulation for gastrointestinal disorders, vagal nerve stimulation in epilepsy, carotid stimulation for hypertension, etc

Conclusions

- The spinal cord neurostimulator is a medical standard that benefits tens of thousands of people worldwide every year;
- Neurostimulation reduces the need for drugs and their side effects.
- Neuroaugmentation is a minimally invasive, nonablative and reversible procedure a relatively low incidence of

- complications and a wide range of benefits.
- The level of spinal cord stimulation can be adjusted and programmed hourly, day and night;
- It does not produce irreversible changes in the spinal cord or nerves, and the system implanted can be disabled or removed without consequences;
- Does not cause habit or addiction;
- Absence of complications or sequelae characteristic of destructive methods within surgical treatment;
- Neurostimulation radically improves the quality of life and enables social and economics reintegration of patients.

Correspondence

streltovion@gmail.com

References

1. Melzack, R., and Wall, P.D. (1965). Pain mechanisms: a new theory. *Science*, Vol. 150, 971-979.
2. Shealy, C.N., Mortimer, J.T., and Resnick, J. Electrical inhibition of pain by stimulation of the dorsal columns: Preliminary reports. *J. Int. Anesth. Res. Soc.*, 46: 489-491, 1967.
3. Shimoji K, Higashi H, Kano T, Asai S, Morioka T. Electrical management of intractable pain. (1971) *Masui (The Japanese Journal of Anesthesiology)*, 20: 444-447.
4. Dilorenzo, D. J.; and Bronzino, J.D. (2008). *Neuroengineering*. CRC Press. Chapter 7.
5. Nagy A, Mekhail MD, PhD, Jianguo Cheng MD, PhD, Samer Narouze MD, Leonardo Kapural MD, PhD, Mark N. Mekhail BSc, Timothy Deer MD. *Practical pain. Clinical Applications of Neurostimulation: Forty Years Later*. Volume 10, Issue 2 March/April 2010 Pages 103-112.
6. Breivik H., et. al *European Journal of Pain*, 2008.
7. Timothy Deer MD, Jason Pope MD, Salim Hayek MD, Samer Narouze MD, Parag Patil

MD, PhD, Robert Foreman PhD, Ashwini Sharan MD, Robert Levy MD, PhD.

Neurostimulation for the Treatment of Axial Back Pain: A Review of Mechanisms, Techniques, Outcomes, and Future Advances. *Neuromodulation: Technology at the Neural Interface* Volume 17, Issue S2 October 2014 Pages 52-68

8. Sweet W.H., Wepsic J.G. Control of pain by focal electrical stimulation for suppression. *Ariz Med.* 1969. Vol. 83. P. 1042-1045.
5. Sweet W.H., Wepsic J.G. Stimulation of the posterior columns of the spinal cord for pain control: indications, technique and results. *Clin. Neurosurg.* 1974. Vol. 21. P. 278-310.
9. Barolat G., Sharan A.D. Future trends in spinal cord stimulation. *Neurol. Res.* 2000. Vol. 22. P. 279-284.
10. Masnyk T., Brown F. Spinal cord stimulation in the treatment of failed back surgery syndrome. *Curr. Rev. Pain.* 1998. Vol. 2. P. 77-84.
11. Dostrovsky J., Lozano A. Mechanisms of electrostimulation. *Mov. Disord.* 2002. Vol. 17, suppl. 3. P. 63-69.

12. Cioni B., Meglio M., Pentimalli L. et al. Spinal cord stimulation in the treatment of paraplegic pain. *J. Neurosurg.* 1995. Vol. 82. P. 35-39.

13. Taylor R.S. Spinal cord stimulation in complex regional pain, syndrome and refractory neuropathic back and leg pain failed back surgery syndrome: results of a systematic review and meta-analysis. *J. Pain Symptom Manage.* 2006. Vol. 31, N 4. P. 13-19.

14. Grahn P.J., Mallory G.W., Berry B.M. et al. Restoration of motor function following spinal cord injury via optimal control of intraspinal microstimulation: toward a next generation closed-loop neural prosthesis. *Front. Neurosci.* 2014 Sept 17. doi: 10.3389/fnins.2014.00296.

15. Taylor RS, Van Buyten J-P, Buchser E. Complex Regional Pain Syndrome. *Eur J Pain* 2006; 10: 91-101.

16. Thomson SJ, Cruglov D, Duarte RV. A spinal cord stimulation service. *Neuromodulation*, 2017; E-pub ahead of print. DOI: 10.1111/ner.12587.