

Article

Study of predisposing risk factors and etiology of chronic subdural hematoma in clipped patients of unruptured intracranial aneurysms – an institutional experience

T. Kawase, Ahmed Ansari, Yoko Kato, Yasuhiro Yamada, Riki Tanaka
JAPAN, INDIA



Study of predisposing risk factors and etiology of chronic subdural hematoma in clipped patients of unruptured intracranial aneurysms – an institutional experience

T. Kawase¹, Ahmed Ansari^{1,2}, Yoko Kato¹, Yasuhiro Yamada¹,
Riki Tanaka¹

¹Neurosurgery, Fujita Health University, Banbuntane Hotokukai Hospital, Nagoya, JAPAN

²Neurosurgery, UPUMS, Saifai, UP, INDIA

Abstract: *Introduction:* Chronic subdural hematoma in clipped patients of unruptured intracranial aneurysms might lead to sudden neurological deterioration and may need emergency evacuation. We studied the effects of various factors in its etiology. *Materials and methods:* A retrospective study of 91 operated clipped patients of unruptured aneurysms in the year 2014-2015 was taken. Various predisposing factors were studied. *Results:* Goreisan use was not associated with any reduction in post operative CSDH formation. Arachnoidoplasty and reduced post operative dead space contributed in a reduced formation of CSDH. *Conclusion:* Older male patients with aneurysms who had been treated with anticoagulant drugs should be considered candidates for additive ARP to prevent the development of postoperative CSDH.

Key words: Goreisan, arachnoidoplasty, anticoagulant, subdural hematoma

Introduction

Chronic subdural hematoma (CSDH) is one of the most common neurosurgical complications and one of the most under reported complication following clipping of unruptured aneurysms. It may lead to sudden neurological deterioration and might need surgical evacuation. Mori and Maeda reported that post operative complications of CSDH occurred in 5.4% of patients (1).

Most of the patients of CSDH are treated by surgical evacuation, although there are

some who have been treated by corticosteroids (2), angiotensin converting enzyme inhibitors (3), hypertonic glucose (4) and mannitol (5). Recently, especially in Japan, the use of traditional herbal medicine in the prevention of CSDH in post operative cases has come into prevalence (6).

Goreisan is believed to have two important actions-One is the diuretic action and the other is hydrostatic modulating action in which the movement of water molecules is adjusted (7).

We report our institutional experience with Goreisan in operated unruptured aneurysm cases.

Materials and methods

We conducted a retrospective study in the year 2014-2015. All patients of unruptured intracranial aneurysms of any age and sex, with follow up for one year were included in the study. A total of 91 patients were thence enrolled for the present study. Different factors were evaluated- age and sex of the patient, anti coagulant use, post operative pneumocephalus, arachnoidoplasty, and Goreisan use. 91 clipped patients of unruptured aneurysms who later developed CSDH were included in the study. The

patients were divided into two groups. In the first group, 21 cases were symptomatic CSDH causing either mass effect or deterioration in consciousness and required surgical evacuation. The second group had 70 cases which were asymptomatic or small CSDH and managed conservatively. Single burr hole evacuation method was deployed for evacuation of CSDH. Routine follow up of these patients over a period of 1 year was performed.

Statistical analysis

For age comparison, student t-test (unpaired) was used. Rest data was qualitative, analysed by Chi square test.

Results

TABLE I

Showing characteristics in groups operated for CSDH and those not operated following clipping

	GROUP 1: 21/91 (23%)	GROUP 2: 70/91 (77%)
MEAN AGE	69.5 years (p<0.015)	64.44 years
MALE:FEMALE	11:10	8:62
GOREISAN USE	17/21	48/70
ANTICOAGULANT	3/21 (p =0.044)	2/70
DEAD SPACE	19/21(90.5%)	27/70
ARACHNOIDOPLASTY	4/21	31/70

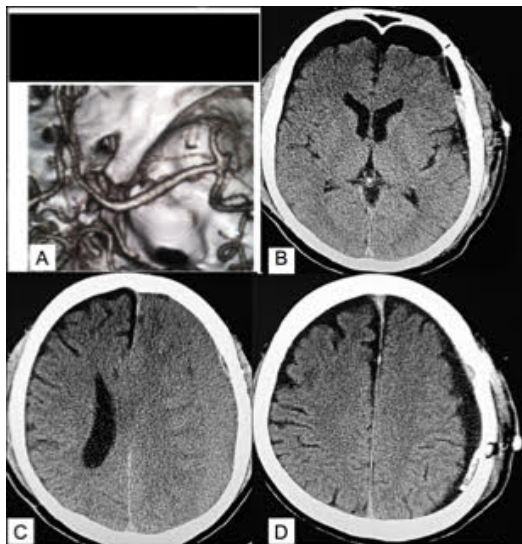


Figure 1 - case illustration of 76 years female with A: left MCA aneurysm, B: post operative Day 1 CT scan showing bifrontal pneumocephalus, C: 2 months following surgery patient had left CSDH causing mass effect, D: following evacuation of the hematoma

Discussion

Although the pathogenesis of CSDH is not completely understood, various key points need to be highlighted. Subdural effusion is believed to be the result of arachnoid tearing by neurosurgical intervention, which causes fluid with or without blood to invade the subdural space and facilitate the formation of outer membrane (8), which then forms internal capillaries or sinusoids. These fenestrated blood vessels allow plasma fluid leakage and the resultant enlargement of the subdural space. Repeated bleeding occurs from degenerating endothelium of capillaries which is accompanied by local hyperfibrinolysis. CSDH tends to occur in patients in elderly patients of unruptured aneurysms, because brain atrophy tends to

cause enlargement of the subarachnoid space and stretching of the bridging veins which facilitate the tearing of the arachnoid membrane and leakage of bloody cerebrospinal fluid into subdural space.

Our series reported a higher incidence of CSDH, as all the patients operated were unruptured aneurysms which had a lax brain compared to other series which had a much lower incidence of CSDH, due to their clipping in ruptured aneurysms. Secondly, with the suctioning of CSF from cisterns, the lax brain in unruptured aneurysms became all the more lax.

We noted a reduced incidence of post operative CSDH in male patients, which may be countered by absence of oestrogen, which may cause the blood vessels in the inner dural layer to become more ectatic because of estrogen priming of these vessels and thus more likely to bleed (9).

Some studies have reported an important role of Aquaporin 4 (AQP4) in CSDH. Utsuki et al reported that AQP4 is expressed in the outer membrane of CSDH (10). Aquaporins are a family of transmembrane channels that allow rapid movement of water and in some cases small molecules across the plasma membrane, hence playing a critical role in brain edema pathogenesis (11,12). Goreisan inhibits AQP4 (13), which is expressed on the outer membrane of CSDH. Asano et al also described the AQP blocking action of Goreisan (14). However, our study did not find any particular benefit with the usage of goreisan.

Torn arachnoid causes a direct contact between subdural space and the cortex, which

leads to continued oozing from the capillaries, hence leading to increase formation of CSDH. We found that with the use of arachnoidoplasty, the incidence of CSDH was overtly reduced in our patients.

We recommend that older male patients with aneurysms who had been treated with anticoagulant drugs should be considered candidates for additive ARP to prevent the development of postoperative CSDH.

Correspondence

Ahmed Ansari

Assistant Professor Neurosurgery, UPUMS, Saifai,
UP, India.

ahmed.ansari2@gmail.com

References

1. Mori K, and Maeda M. "Surgical treatment of chronic subdural hematoma in 500 consecutive cases: clinical characteristics, surgical outcome, complications, and recurrence rate. *Neurologia medico-chirurgica* 41.8 (2001): 371-381.
2. Voelker JL. Nonoperative treatment of chronic subdural hematoma. *Neurosurg Clin N Am.*2000 Jul;11(3):507-13.
3. Weigel R, Hohenstein A, Schlickum L, Weiss C, Schilling L. Angiotensin converting enzyme inhibition for arterial hypertension reduces the risk of recurrence in patients with chronic subdural hematoma possibly by an antiangiogenic mechanism. *Neurosurgery.* 2007 Oct;61(4):788-92; discussion 792-3.
4. Ambrosetto C. Post traumatic subdural hematoma. Further observations on nonsurgical treatment. *Arch. Neurol* 1962;6: 287-292.
5. Suzuki J, Takaku A. Non surgical treatment of chronic subdural hematoma. *J. Neurosurgery.* 1970; 33: 548-553.
6. Okamura A, Kawamoto Y, Sakoda E, Murakami T, Hara T. Evaluation of recurrence factors and Goresan administration for chronic subdural hematoma after percutaneous subdural tapping. *Hiroshima J. Med. Sci.* 2013; 62:77-82.
7. Ohnishi N, Nagasawa K, Yokoyama T. The verification of regulatory effects of Kampo formulations on body fluid using mice model. *J. Trad. Med.* 2000; 17:131-136.
8. Hasegawa M, Yamashita T, Yamashita J, Suzuki M, Shimada S. Traumatic subdural hygroma: pathology and meningeal enhancement on magnetic resonance imaging. *Neurosurgery* 1992; 31: 580-585.
9. Markwalder TM. Chronic subdural hematomas: a review. *J Neurosurg.* 1981;54:637-645.
10. Utsuki S, Oka H, Inukai M, Abe K, Fujii K. role of saireito in postoperative chronic subdural hematoma recurrence prevention. *J. Trad. Med.* 2012; 29: 137-142.
11. G. T. Manley, D. K. Binder, M. C. Papadopoulos, A. S. Verkman. New insights into water transport and edema in the central nervous system from phenotype analysis of aquaporin-4 null mice. *Neuroscience.* 2004; 129(4): 983-991.
12. S Saadoun, M Papadopoulos, D Davies, S Krishna, B Bell. Aquaporin-4 expression is increased in oedematous human brain tumours. *J Neurol Neurosurg Psychiatry.* 2002 Feb; 72(2): 262-265.
13. Kurita, T., K. Nakamura, M. Tabuchi, M. Orita, K. Ooshima and H. Higashino., 2011. Effects of gorei-san: A traditional japanese kampo medicine, on aquaporin 1, 2, 3, 4 and V2R mRNA expression in rat kidney and forebrain.. *J. Med. Sci.*, 11: 30-38.
14. Asano S, Watanabe T, Shinohara T, Fujii N, Ogawa A, Nakagomi T. Medical treatment by Goresan only or with other hemostatic agents for chronic subdural hematoma without operations. *Gazz. Med. Ital.* 2013; 172: 911-915.