

Article

Kinked and retained nasogastric tube in polytrauma patient; a case report

Ashok Kumar, Vardan Kulshreshtha, Pavan Kumar, Gaurav Jaiswal, Tarun Kumar Gupta
INDIA



DE GRUYTER
OPEN

Kinked and retained nasogastric tube in polytrauma patient; a case report

Ashok Kumar¹, Vardan Kulshreshtha¹, Pavan Kumar¹,
Gaurav Jaiswal², Tarun Kumar Gupta³

¹Senior residents, ²Associate professor, ³Professor
Department Of Neurosurgery, RNT Medical College, Udaipur, INDIA

Abstract: Enteral feeding is an important and preferred technique of feeding in head injury patient to provide nutrition. As inadequate nutrition causes decrease in physical ability, neurological impairment and takes a long time for improvement or delayed deterioration. With our best knowledge kinked and retained nasogastric tube in stomach is a very rare complication of feeding in head injuries patients. Predisposing factors that can cause kinking is excess tube length, tube in situ for long time and small bore tube. We are reporting one such case of kinked and retained nasogastric tube in the stomach of a polytrauma patient which was retrieved by upper GI endoscope.

Key word: Nasogastric tube, kinked, retained, G I endoscopy

Introduction

Nutritional support constitutes an important issue in intensive care for critically ill patients. However, it is generally neglected and underestimated in the subgroup of TBI population. In the recent most important trials in nutrition, Casaer et al. only included 0.6% of patients with neurological diseases (1). Enteral nutrition is clearly established as the preferential route of nutrition support for this population verses parenteral nutrition. There appears to be a consensus on early initiation of enteral nutrition. Adequate nutritional support in TBI is essential to provide the optimal milieu for neurological and systemic recovery. Despite various studies in TBI, ‘what, when, and how’ of nutritional

replacement remains elusive. Nutrition therapy should start early within 24 to 48 hours of admission to the intensive care unit. The feeding should be adjusted based on the patient’s nutritional requirements over the next 48 to 72 hours (2). American Association of Neurological Surgeons’ (AANS) guidelines the recommended full nutritional replacement to be instituted by the seventh day. Cochrane Collaboration reviews have suggested that nutrition therapy may improve mortality and neurological outcomes (3). Early feeding may be associated with a trend towards better outcomes in terms of survival and disability (4). Enteral nutrition has many advantages over total parenteral nutrition (TPN), the latter being associated with several

complications (5). The weighted average mortality for severe TBI is 39%, and for unfavorable outcome is 60% on the Glasgow Outcome Scale (6).

Case report

A 15 year female patient admitted in department of neurosurgery as a follow up case of head injury with chest injury with blunt trauma abdomen. He sustained injury due to fall from tree 2 month back, at time of admission GCS was e1v1m4 and pupillary anisocoria present, right pupils was 2mm nonreactive and left pupil was 4mm nonreactive, clinically multiple ribs fracture present and surgical emphysema over right side of chest. Patient intubated and simultaneously intercostals drainage tube was inserted. After stabilizing the patient CECT chest and abdomen and NCCT head done, CECT chest and abdomen revealed multiple ribs fracture with hemothorax left side, liver laceration, while NCCT head revealed a small

intracranial hemorrhage in frontal area along the falx and small subdural hematoma at frontal convexity (Figure1). Patient kept on ventilator and on 2nd day tracheotomy was done. Patient was managed conservatively and subsequently weaned from ventilator and tracheostomy decanulated and discharged with satisfactory general condition after 21 days with nasogastric tube in situ with follow up advice. Patient presented for follow up after 2 weeks period. We tried to change the nasogastric tube but it was not possible for which pt was shifted to gastroenterology department and upper GI endoscopy done. It revealed kinking of nasogastric tube and densely adhered with its side eyelets (Figure 2). Distal end of tube was held by grasper and proximal end was pulled, this procedure repeated many time because tube in side stomach was become hard which was causing slippage from grasper, finally it was detached from point of contact at eyelets and was pulled out judiciously (Figure 3).

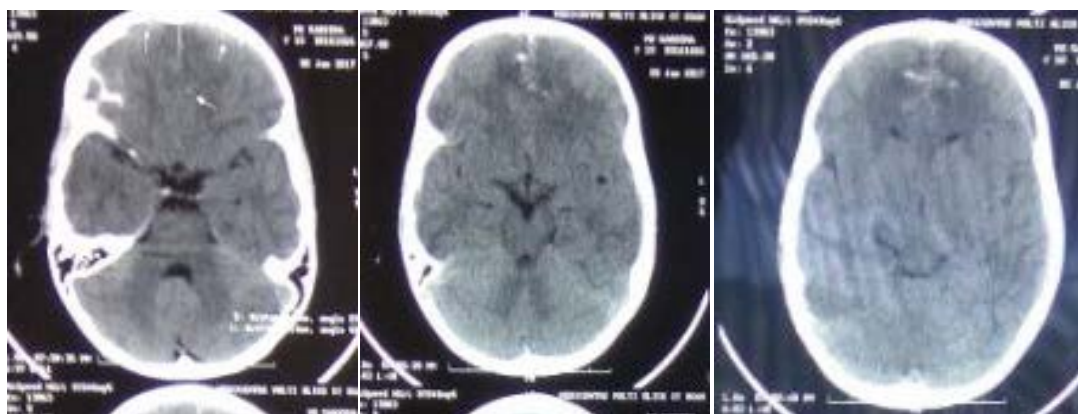


Figure 1 - NCCT head: frontal ICH along the falx and thin SDH along bi-frontal convexity

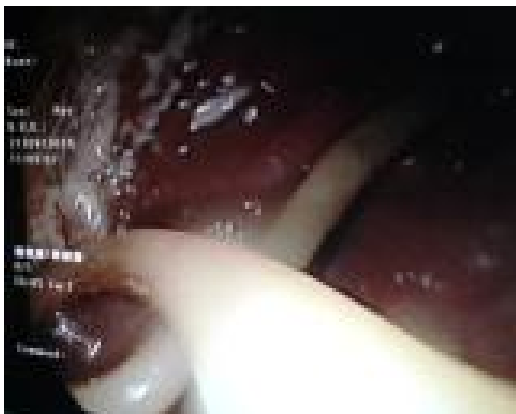

Figure 2 - Kinked and adhered nasogastric tube



Figure 3 - Retrieved tube

Discussion

Complication of nasogastric feeding is well known, it has been found that nasogastric tube has functional and mechanical complication. The distal portion of NGT has multiple apertures (the weakest part) making it susceptible to kink, coil, and knot. Tan M et, al. Demonstrated the complications which appeared were: tube dislodgement (48.5%); electrolytic alterations (45.5%); hyperglycemia (34.5%); diarrhea (32.8%); constipation

(29.7%); vomiting (20.4%); tube clogging (12.5%); and lung aspiration (3.1%) (7). De Aguilar-Nascimento and Kudsk demonstrated that of 932 blind post pyloric tube placement attempts, (46%) failed and 20 (1.6%) were airway misplacements (8). Montejo et, al. found that 251 patients (63%) experienced one or more GI complications during their feeding course. Yung-Fong Tsai et, al. Conducted study that Insertions using smaller size NGTs or softer silicone stomach tubes have more kinking (9). Although an apparently innocuous and simple procedure, NGT insertion is essentially an invasive procedure and often needs repetitive attempts which may result in adverse events such as kinking, knotting, bleeding, false passage; sometimes the attempts end in failure. (10) We reported this case to bring this rare presentation of kinked and retained nasogastric tube in such patients.

Conclusion

A multidisciplinary approach should be performed in head injury patients to provide adequate nutrition, energy and electrolyte. Kinking of nasogastric tube are rare condition and have been described very few cases. One of the common causes of complication of nasogastric feeding is unawareness and ignorance of tube feeding. Nasogastric feeding most widely used for feeding purpose in head injury patients but the great care to be taken to avoid its complication by choosing appropriate tube size, type and positioning by x-rays, irrigation by plane water after each feed and drugs, routine changing of tube. Removal and insertion of tube should be

carried out routinely, and whenever there is difficult to retrieve the tube it should be removed under endoscopic guidance otherwise there may be high possibilities of injury to gastro esophageal junction which may cause bleeding, reflux disease and may leads to death.

Correspondence

Ashok Kumar, 401 Hitawala Complex, Raghuroop Apartment, Sardarpura, Udaipur, Rajasthan, India
Email: dr.ashokkumar011@gmail.com
Phone: +919610463977

References

1. Casaer MP, Mesotten D, Hermans G, Wouters PJ, Schetz M, et al. (2011) Early versus late parenteral nutrition in critically ill adults. *N Engl J Med* 2011 Aug 11;365(6):506-17. doi: 10.1056/NEJMoa1102662. Epub 2011 Jun 29
2. Cook AM, Peppard A, Magnuson B (2008) Nutrition considerations in traumatic brain injury. *Nutr Clin Pract* 23: 608–620, SAGE journal dec 2008.
3. Perel P, Yanagawa T, Bunn F, Roberts I, Wentz R, Pierro A. Nutritional support for head-injured patients. *Cochrane Database Syst Rev.* 2006;(4):CD001530. Review.
4. Borzotta P, Pennings J, Papasadero B, Paxton J, Mardesic S, Borzotta R. Enteral versus parenteral nutrition after severe closed head injury. *J Trauma.* 1994;37:459–66.
5. Frost P, Bihari D. The route of nutritional support in the critically ill: Physiological and economical considerations. *Nutrition.* 1997;13 (Suppl):58S–63.
6. Rosenfeld JV, Maas AI, Bragge P, Morganti-Kossmann MC, Manley GT, et al. Early management of severe traumatic brain injury. 2012, *Lancet* 380: 1088–1098
7. Tan M, Zhu JC, Yin HH. Enteral nutrition in patients with severe traumatic brain injury: reasons for intolerance and medical management *Br J neurosurgery* 2011; Feb: 25 (1) 2- 8doi 10.3109/02688697.2010.522745
8. De Aguilar-Nascimento JE, Kudsk KA. Clinical costs of feeding tube placement. *JPEN J Parenter Enteral Nutr.* 2007;31:269–273.
9. Yung-Fong Tsai, Chiao-Fen Luo, Amina Illias, Chih-Chung Nasogastric tube insertion in anesthetized and intubated patients: a new and reliable method Lin, and Huang-Ping Yu, *BMC Gastroenterology* 2012;12:99
10. Sekhar Ranjan Basu, Sabyasachi Das, Sujata Dolai, Santanu Ghosh, Mohan Chandra Mandal, Pallab Kumar Mistri, Rajiv Roy. Comparison of four techniques of nasogastric tube insertion in anaesthetised, intubated patients: A randomized controlled trial. *IGA214 Year: 2014 | Volume: 58 | Issue: 6 | Page: 714-71.*