

The probiotic *Enterococcus faecium* modifies the intestinal morphometric parameters in weaning piglets

El probiótico *Enterococcus faecium* modifica los parámetros morfométricos intestinales en lechones destetados

doi: 10.15446/rfna.v69n1.54748

Johana Andrea Ciro Galeano^{1*}; Albeiro López Herrera² and Jaime Parra Suescún²

ABSTRACT

Key words:

Weaning
Small intestine
Piglets
Probiotics
Villi

Global trends for animal production have seen a decrease in the use of antimicrobial compounds in feed, generating the need to implement new nutritional strategies that stimulate growth and promote intestinal health. This study aimed to determine whether the addition of *E. faecium* in drinking water improves intestinal morphometric parameters in post-weaning pigs compared with the probiotics strains *L. acidophilus* and *L. casei* on days 1 (21 days of age), 15 and 30 postweaning. The small intestine was completely removed to evaluate the morphometric parameters (length and width of villi and crypts) in the different intestinal segments (duodenum, jejunum, and ileum). They were fed for 30 days with two diets: commercial diet with or without antibiotics. The different probiotics, *L. acidophilus*, *L. casei* and *E. faecium*, were administered in the drinking water of the animals that consumed the commercial diet without antibiotics. A randomized block design in split-plot arrangement was used. There was a significant increase ($P<0.01$) in the width and length of villi, and a decrease ($P<0.01$) in the values obtained for the width and depth of crypts in the animals that consumed *E. faecium*, as compared to those that consumed the diet with addition of antibiotics. The use of probiotics, especially *E. faecium*, is a nutritional treatment strategy when antimicrobial compound are used, improving the intestinal morphometric parameters and, at the same time, the digestive and productive parameters of the animals. Work is in progress to investigate the effects of probiotic supplementation on the modification of gut microbiota of post-weaning piglets.

RESUMEN

Palabras claves:

Destete
Intestino delgado
Lechones
Probióticos
Velloidades

Las tendencias mundiales en producción animal han llevado a disminuir el uso de compuestos antimicrobianos en la alimentación, generando la necesidad de implementar estrategias nutricionales que estimulen el crecimiento y promuevan la salud intestinal. Este estudio tuvo como objetivo determinar si la adición de *E. faecium* en el agua potable mejora parámetros morfométricos intestinal en cerdos de destete posteriores en comparación con las cepas de probióticos *L. acidophilus* y *L. casei* en los días 1 (21 días de edad), 15 y 30 posteriores destete. El intestino delgado se eliminó completamente para evaluar los parámetros morfométricos (longitud y anchura de las vellosidades y criptas) en los diferentes segmentos intestinales (duodeno, yeyuno, ileon). Los animales fueron alimentados con dos dietas: dieta comercial con y sin la adición de antibióticos. Los probióticos *L. acidophilus*, *L. casei* y *E. faecium*, se suministraron separadamente en el agua de bebida de los animales que consumieron la dieta comercial sin antibiótico. El diseño estadístico utilizado fue de bloques al azar en un arreglo de parcelas divididas. Se observó un aumento significativo ($P<0.01$) en ancho y altura de vellosidades, y una disminución ($P<0.01$) en los valores obtenidos para ancho y profundidad de criptas en los animales que consumieron *E. faecium*, frente a aquellos que consumieron la dieta con adición de antibiótico. El uso de probióticos, especialmente *E. faecium* se constituye en una estrategia terapéutica nutricional al uso de compuestos antimicrobianos, mejorando las características morfométricas intestinales de los animales.

¹ Fundación Universitaria Autónoma de las Américas. Carrera 28 No. 98-56, Pereira, Colombia.

² Grupo BIOGEM - Facultad de Ciencias Agrarias - Universidad Nacional de Colombia. A.A. 1779, Medellín, Colombia.

* Corresponding author <johana.ciro@uam.edu.co>

In order to increase the performance reproductive sow, premature weaning of piglets has become common practice, generating stress and retarding the post-weaning growth of the pigs. The stress generated by separation from the mother, the abrupt change in food, the inclusion of raw vegetative material in the diet, and the poor development of the gastrointestinal tract in piglets result in a disruption of the mucosa integrity and a reduction in the digestion and absorption of nutrients at the intestinal level (Ciro *et al.*, 2013). Furthermore, weaning modifies intestinal microbial population, characterized by a change and imbalance in the intestinal functions (Kang *et al.*, 2010), which in turn generate economic losses in the swine industry (Reis *et al.*, 2007; Campbell *et al.*, 2013).

Before weaning, intestinal villi are long, well-structured, and very efficient in the absorption of nutrients due to the fact that intestinal glandular cells are able to replace the villi enterocytes as fast as they are lost (Gómez *et al.*, 2008; Ciro *et al.*, 2013). However, after weaning, the length of villi is reduced by almost half, causing the appearance of a higher proportion of immature and weak enterocytes at the extremes of the villi (Cabrera *et al.*, 2013), resulting in cellular death, reduction in the surface area of the villi, imbalance in osmotic regulation, infiltration of the lamina propria by mononucleotide cells (Jacobi *et al.*, 2013), and, therefore, a decrease in the nutrient absorption processes (Zhenfeng *et al.*, 2008). Food that is not digested and absorbed by the small intestine remains available in the cecum and colon for microbial populations, generating intense activity and a proliferation of enteropathogens, specifically Enterotoxigenic *E. coli* (ETEC), *salmonella* spp., *clostridium perfringens*, and rotaviruses (lesser extent), which result in diarrhea (Lallès *et al.*, 2004; Farzan *et al.*, 2013).

In order to counteract the different enteric problems, feed supplementation with antimicrobial compounds is currently offered, which have been used in the swine industry as growth parameters and also as therapeutic y/o prophylactic treatments of gastrointestinal diseases in piglets (Kang *et al.*, 2010). Currently, the trends in animal production patterns is promote the reduction and possible elimination of the inclusion of antimicrobial compounds without restrictions in feed through the implementation of diets with alternative approaches that stimulate growth and intestinal health (Kang *et al.*,

2010), that decrease the generation of residues in the consumption product and of bacteria that are resistant to the antibiotics (Ghosh *et al.*, 2013), and that do not harm human health (Zeyner and Boldt, 2006).

As a result, the use of Probiotics has been proposed as a nutritional treatment strategy, "live microorganisms that, when administered at suitable quantities, confer benefits to the health of the host." (FAO / OMS, 2006, DiRienzo, 2014). These microorganisms have created a close relationship between nutrition, microbiota, and health (Songisepp *et al.*, 2012; Flesh *et al.*, 2014; Mitsouka *et al.*, 2014). In pigs, probiotics, such as *E. faecium* or *B. cereus* variant Toyoi, are commonly used, based on prior reports of positive effects against microbial infections (Bednorz, *et al.*, 2013), *E. faecium* also changes the properties of absorption, secretion and transport of the intestinal barrier in piglets (Klingpor *et al.*, 2013). For these reasons, this study aimed to determine whether the addition of *E. faecium* in drinking water improves intestinal morphometric parameters in post-weaning pigs compared with the probiotics strains *L. acidophilus* and *L. casei*.

MATERIALS AND METHODS

Ethical considerations

All experimental procedures were conducted according to guidelines suggested by "The International Guiding Principles for Biomedical Research Involving Animals" (CIOMS, 2012), and approved by the Ethics Committee on Animal Experimentation of Universidad Nacional de Colombia, Medellín (CEMED-03 of May 7, 2012).

Location

The fieldwork was conducted in the commercial farm "Caña Brava", and is located in the municipality of Gómez Plata with an altitude of 1,540 meters, and a temperature range of 18 to 22 °C, corresponding to a tropical lower-montane wet forest zone (bmh-MB).

Animals

Eighty duroc x pietrain cross piglets (male and female) weaned at 21 days of age and with an approximate weight of 6 ± 0.5 kg were used, which were separated into groups of 8 during the post-weaning period. Each of the corrals was provided with trough-type feeders, in a controlled temperature room (26 ± 3 °C). Water was

provided *ad libitum* throughout the experiment. The provided commercial diet (pelleted feed) was enriched with vitamins, minerals, and lysine HCL. The diets were balanced in order to meet all of the minimal nutrition requirements and proposals from the NRC (2012) (Table 1). The quantity of feed offered to the piglets was administered in accordance with the dietary table that

corresponded to the productive stage (growth). Additional feed was provided when required by the animals likewise, the drinking water that contained the probiotic strains was offered daily from day 1 of the weaning until the slaughter, which was carried out sequentially during the 30 days of the growth stage. No solid feed was provided to the piglets during the lactation.

Table 1. Proximal analysis of the basal diet.

Proximal composition	
Crude protein (%)	22.0
Ether extract (%)	6.0
Ash (%)	8.0
Fiber (%)	5.0
Moisture (%)	13.0

Diets

The animals were fed with two diets: a commercial diet with and without the addition of antibiotics. The different probiotics strains (*L. casei*, *L. acidophilus* and *E. faecium*) were administered in the drinking water of the animals that consumed the commercial diet without antibiotics as follows:

Diet 1 (D1): Commercial feed without antibiotics, without supplementation with probiotic strains in the drinking water.

Diet 2 (D2): Commercial feed with antibiotics (manufacturer's recommended dosage), without supplementation with probiotic strains in the drinking water.

Diet 3 (D3): Commercial feed without antibiotics, with supplementation with the commercial probiotic strain *L. acidophilus* in the drinking water.

Diet 4 (D4): Commercial feed without antibiotics, with supplementation with the commercial probiotic strain *L. casei* in the drinking water.

Diet 5 (D5): Commercial feed without antibiotics, with supplementation with the commercial probiotic strain *E. faecium* in the drinking water.

The quantity of probiotics added was based on the instructions for their preparation and addition provided by the manufacturer's recommendations. The inclusion of the probiotics in the drinking water was carried out by directly mixing a liter of water with 30 g of commercial

sugar, thereby guaranteeing minimal populations of 10^8 UFC with suitable viability, which was added in 50 L of water, and evaluated through microbiological analyses. The animals were receiving water without probiotics, were also added to a liter of water with 30 g of sugar. The feed used in this study was free of antibiotics (except the D2 diet) as the aim was not to modify the diet but to incorporate probiotics as an alternative to using antibiotics. The experiment diets were provided for 30 days starting at the day of weaning (age of 21 days).

Intestinal tissue sampling

During the experiment phase, euthanasia was carried out on the 35 piglets in the following manner: on the initial day, or day 1 (day of weaning), 5 piglets were slaughtered randomly, which represented the reference group in order to verify the general state of health and the macroscopic evaluation of the state of the organs of the animals before providing the experiment diets and the experiment units for each of the treatments; and day 15 and 30 post-weaning, 3 piglets were slaughtered randomly for each treatment, performing euthanasia to 30 piglets. All piglets were slaughtered 2.5 hours after their last feeding. The animals were sedated with the neuroleptic stresnil® (Azaperona) intramuscularly and were subsequently subjected to Nitrox® inhalation.

After the slaughter, the piglets were placed in a supine position, dissected in the abdominal region, and had their

small intestine completely extracted, from the pyloric union to the ileocecal valve. Afterwards, the intestine was lined up on a table, measured without any tension, divided into three equally sized sections (duodenum, jejunum, and ileum) (Segalés and Domingo, 2003). The duodenum was the segment that started at the pylorus and terminated at the Treitz ligament; the jejunum was the proximal segment of the small intestine that continued along an angle and the ileum was the proximal segment (10 cm) before the ileocecal union. Approximately 1 cm of the transversal sections of the intestinal tissue was eliminated and 5 cm were taken from the start of each of the segments: duodenum, jejunum and ileum for each animal. The digesta contained in the samples was removed by a cold saline infusion wash as previously described (Reis *et al.*, 2005; Ciro *et al.*, 2013), and preserved in 10% buffered formalin and subsequently stored until performing laboratory determinations.

Morphometric analysis of the small intestine **Morphometry of the small intestine**

Samples from three regions of the small intestine were processed and analyzed in the Laboratory of Animal Pathology at the Universidad de Antioquia for analysis by experts.

Histotechnological processing

The tissues were placed in 10% buffered formalin for 48 hours, embedded in paraffin, sliced in 4 µm thick cuts and stained with Hematoxylin-Eosin in order to be washed and stored in ethanol : water (75:25, v:v), in accordance with the method reported by Vente-Spreeuwenberg *et al.* (2003). These cuts were micro-dissected in order to determine the mean of the height and width of the intestinal villi, as well as the depth and width of the adjacent crypts. In each lamina three transverse cuts were mounted per slide.

Microscopic evaluation and morphometric analysis of images

The histological sections were analyzed quantitatively by computerized digital image processing, as follows: An optical microscope (Leica DMLB, Meyer Instruments, Houston, TX, USA) was used to identify tissue areas; then, the corresponding images were captured with a three megapixel 200X zoom camera for instant digital microscopy (Moticam 2300, Motic, Hong Kong, China).

The images were analyzed with Motic Images Plus 2.0 image treatment software (Motic, Hong Kong, China).

The following morphometric variables were measured in each of the histological cuttings:

Intestinal villi

Height: once the villus based was established, a line was made from the mid-point to the apex.

Width: a line was made from the apical borders of the epithelial cells of opposite sides, located at approximately the middle of the villus.

The depth and width of the intestinal crypts were also determined, in accordance with the prior descriptions of Marion *et al.* (2002) and Vente-Spreeuwenberg *et al.* (2001).

Intestinal crypts

Depth: taken drawing a line or continuous segments from the opening to the base.

Width: with a line connecting the apical borders of the epithelial cells located on opposite sides at a mid-point level of the crypt.

The average value for each variable was calculated after performing measurements in eight villi and their corresponding intestinal crypts. Due to the fact that villus height may vary in each intestinal fold, being shorter at the apex, it was required that each region was equally represented in the assessment. In consequence, a circular fold of the mucosa was chosen, measuring two villous from the bottom, two on the right, two from the left side and two from the vertex. This procedure was repeated in each section of the small intestine (duodenum, jejunum and ileum) allowing to verify the effect of different diets on the villi according to their location. As far as we are aware, this analysis has not been performed previously.

Statistical design

The experiment was conducted as a randomized block design in divided parcels. The animals were blocked by initial weight. Each animal was assigned to one of 5 treatments (five experimental diets and three post-weaning periods), and each treatment had three repetitions. Statistical data analysis was conducted using the General Linear Models procedure (GLM) of SAS

program (2007). A Duncan test was used to compare treatment means ($P < 0.05$).

RESULTS AND DISCUSSION

The pigs that consumed the experiment diets did not presented any signs of illness that would force their retirement or immediate slaughter. No food leftovers were observed during the experiment.

In this experiment, no statistical interaction was observed between the different experiment diets and the weaning periods for any of the studied variables; therefore it was

unnecessary to analyze those two factors independently. The change in length and width defined between each of the diets and exposure periods villi can be seen in Table 2. With respect to the length and width of villi, showed a significant increase ($P < 0.01$) between the different evaluated diets, where D1 obtained lower values compared to D2 and off the diet with probiotics, where animals in D5 reported higher values (Figure 1) for this intestinal variable. For intestinal segments there was significant statistical difference ($P < 0.01$), where the duodenum showed higher values compared to the other two segments (jejunum and ileum) to villi length

Table 2. Comparison of villi (μm) of different intestinal sections in pigs that consumed the experiment diets for 30 days post-weaning

Villi (μm)	Intestinal segment	Day	D1	D2	D3	D4	D5	SEM
Length	Duodenum ¹	1	335.7 ^X	338.6 ^X	341.5 ^X	334.7 ^X	342.3 ^X	3.34
		15	393.4 ^{A,Y}	427.2 ^{B,Y}	455.3 ^{C,Y}	478.7 ^{D,Y}	497.1 ^{E,Y}	
		30	421.1 ^{A,Z}	455.8 ^{B,Z}	485.1 ^{C,Z}	512.5 ^{D,Z}	539.5 ^{E,Z}	
	Jejunum ²	1	321.5 ^X	322.6 ^X	321.5 ^X	322.1 ^X	322.5 ^X	
		15	378.5 ^{A,Y}	401.1 ^{B,Y}	421.9 ^{C,Y}	444.3 ^{D,Y}	462.2 ^{E,Y}	
		30	409.3 ^{A,Z}	415.8 ^{A,Z}	436.9 ^{B,Z}	468.7 ^{C,Z}	491.5 ^{D,Z}	
	Ileum ³	1	302.5 ^X	303.7 ^X	301.9 ^X	304.7 ^X	303.2 ^X	
		15	341.4 ^{A,Y}	366.8 ^{B,Y}	394.6 ^{C,Y}	415.4 ^{D,Y}	436.8 ^{D,Y}	
		30	371.3 ^{A,Z}	374.9 ^{A,Y}	403.5 ^{B,Z}	434.6 ^{C,Z}	461.6 ^{D,Z}	
Width	Duodenum ¹	1	114.5 ^X	113.2 ^X	115.9 ^X	114.7 ^X	115.1 ^X	1.23
		15	124.4 ^{A,Y}	138.5 ^{B,Y}	163.0 ^{C,Y}	182.6 ^{D,Y}	197.7 ^{E,Y}	
		30	137.9 ^{A,Z}	156.6 ^{B,Z}	186.1 ^{C,Z}	197.5 ^{D,Z}	211.5 ^{E,Z}	
	Jejunum ²	1	104.1 ^X	104.2 ^X	102.2 ^X	103.5 ^X	103.1 ^X	
		15	112.4 ^{A,Y}	126.7 ^{B,Y}	145.1 ^{C,Y}	164.4 ^{D,Y}	177.4 ^{E,Y}	
		30	125.3 ^{A,Z}	139.4 ^{B,Z}	159.7 ^{C,Z}	178.7 ^{D,Z}	190.5 ^{E,Z}	
	Ileum ³	1	94.2 ^X	95.4 ^X	96.1 ^X	95.2 ^X	95.3 ^X	
		15	104.2 ^{A,Y}	115.4 ^{B,X}	128.6 ^{C,Y}	142.5 ^{D,Y}	155.4 ^{E,Y}	
		30	115.4 ^{A,Z}	127.8 ^{B,Y}	138.9 ^{C,Z}	154.3 ^{D,Z}	175.2 ^{E,Z}	

D1: Commercial feed without probiotics and without antibiotics; D2: Commercial feed + antibiotics; D3: Commercial feed without antibiotics + *L. acidophilus*; D4: Commercial feed without antibiotics + *L. casei*; D5: Commercial feed without antibiotics + *E. faecium*.

^{A,B,C,D,E} In the same row with a similar superscript did not differ statically ($P < 0.05$). ^{X,Y,Z} In the same mean column with a similar superscript did not differ statistically ($P < 0.05$). ^{1,2,3} In the same row with a similar superscript did not differ statically ($P < 0.05$)

SEM: Standard error of the mean.

and width of. For the same variables under study, there was significant statistical difference between the different sampling days in each of the diets ($P < 0.05$) and intestinal segment, where higher values occurred in the 30th.

For the depth and width defined between each of the diets and exposure periods crypts variable can be seen in Table 3. For these variables there was a significant ($P < 0.01$) among the different diets evaluated, where D1

obtained higher values compared to D2 and facing diets with probiotics, where animals in D5 reported the lowest values for this intestinal variable. For intestinal segments there was significant statistical difference ($P < 0.01$), where the duodenum showed lower values compared to the other

two segments (jejunum and ileum) to crypt depth and width. For the same variables under study, there was significant statistical difference between the different sampling days in each of the diets ($P < 0.01$) and intestinal segment where the lowest values were presented at the 30th.

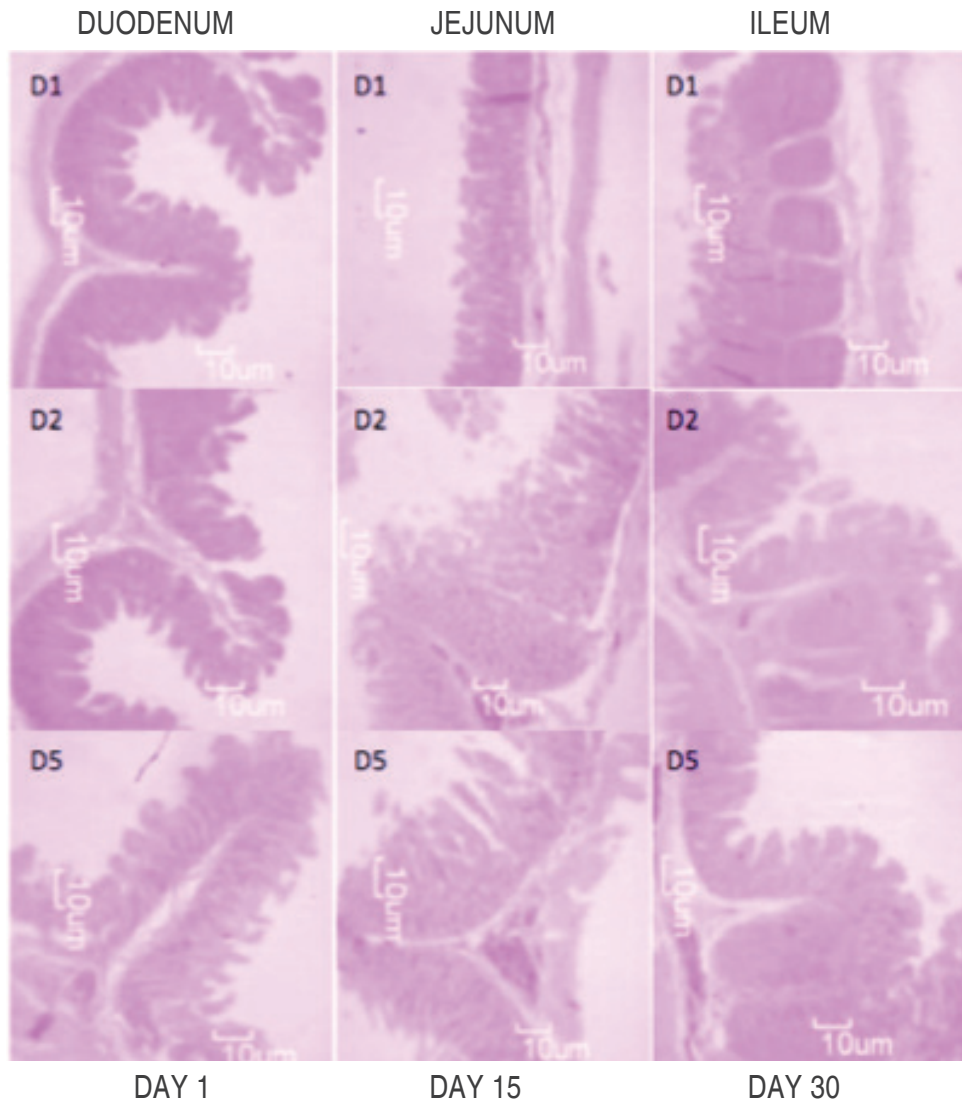


Figure 1. Comparison of intestinal villi (μm) in different intestinal segments of pigs fed experimental diets (D1, D2 and D5) at day 30 after weaning.

The development of the small intestine in recently born piglets is accelerated for the first 10 days of life, a period in which the intestine is colonized with bacteria from the mother and the environment, resulting in a microbial composition and diversity that are unstable and highly influenced by the use

of antibiotics, stress and nutrition (Schokker *et al.*, 2014). Therefore, increases in weight, length, and diameter that are associated with increases in the height and diameter of the villi and in the cellular populations that form them (enterocytes) are significant (Reis de Souza *et al.*, 2005).

Table 3. Comparison of crypts (μm) in different intestinal sections of pigs that consumed the experiment diets for various post-weaning periods.

Crypts (μm)	Intestinal segments	Day	D1	D2	D3	D4	D5	SEM
Depth	Duodenum ¹	1	127.2 ^X	125.2 ^X	126.2 ^X	124.5 ^X	125.6 ^X	1.04
		15	119.2 ^{A,Y}	118.5 ^{AB,Y}	114.3 ^{B,Y}	106.7 ^{C,Y}	99.5 ^{D,Y}	
		30	112.2 ^{A,Z}	108.9 ^{A,Z}	101.2 ^{B,Z}	97.3 ^{B,Z}	90.3 ^{C,Z}	
	Jejunum ²	1	138.3 ^X	136.6 ^X	135.1 ^X	136.5 ^X	137.3 ^X	
		15	129.2 ^{A,Y}	129.5 ^{A,Y}	122.2 ^{B,Y}	115.8 ^{C,Y}	108.3 ^{D,Y}	
		30	121 ^{A,Z}	115.4 ^{B,Z}	108.6 ^{C,Z}	102.2 ^{D,Z}	97.3 ^{E,Z}	
	Ileum ³	1	144.1 ^X	143.1 ^X	145.6 ^X	143.6 ^X	145.1 ^X	
		15	137.5 ^{A,Y}	120.1 ^{B,Y}	116.1 ^{C,Y}	110.7 ^{D,Y}	105.6 ^{E,Y}	
		30	128.0 ^{A,Z}	121.3 ^{B,Z}	114.9 ^{C,Z}	109.6 ^{D,Z}	102.6 ^{E,Z}	
Width	Duodenum ¹	1	118.3 ^X	118.5 ^X	119.6 ^X	118.9 ^X	119.9 ^X	0.58
		15	113.2 ^{A,Y}	111.9 ^{A,Y}	108.6 ^{B,Y}	104.1 ^{C,Y}	100.3 ^{D,Y}	
		30	107.1 ^{A,Z}	108.9 ^{A,Z}	103.2 ^{B,Z}	99.6 ^{C,Z}	94.1 ^{D,Z}	
	Jejunum ²	1	127.7 ^X	128.4 ^X	127.2 ^X	128.9 ^X	129.1 ^X	
		15	124.1 ^{A,Y}	118.9 ^{B,Y}	114.2 ^{C,Y}	109.2 ^{D,Y}	104.1 ^{E,Y}	
		30	118.3 ^{A,Z}	113.1 ^{B,Z}	109.8 ^{C,Z}	104.7 ^{D,Z}	101.2 ^{E,Z}	
	Ileum ³	1	133.2 ^X	133.8 ^{BX}	134.6 ^X	134.2 ^X	133.6 ^X	
		15	129.3 ^{A,Y}	123.9 ^{B,Y}	118.1 ^{C,Y}	114.2 ^{D,Y}	109.9 ^{E,Y}	
		30	123.5 ^{A,Z}	119.1 ^{B,Z}	113.2 ^{C,Z}	109.3 ^{D,Z}	105.3 ^{E,Z}	

D1: Commercial feed without probiotics and without antibiotics; D2: Commercial feed + antibiotics; D3: Commercial feed without antibiotics + *L. acidophilus*; D4: Commercial feed without antibiotics + *L. casei*; D5: Commercial feed without antibiotics + *E. faecium*.

^{A,B,C,D,E} In the same row with a similar superscript did not differ statically ($P < 0.05$). ^{X,Y,Z} In the same mean column with a similar superscript did not differ statistically ($P < 0.05$). ^{1,2,3} In the same row with a similar superscript did not differ statically ($P < 0.05$)

SEM: Standard error of the mean.

Likewise, the villi at the beginning of life in piglets are elongated fingers in appearance, which swell over time, and, at 7-8 life weeks, acquire a tongue-like form (Müller *et al.*, 2011). However, at weaning (approximately 21 to 28 days old), the length is reduced by almost half and the depth of the glandules is increased, with the appearance of more weak and immature enterocytes in the extremes of the villi, reducing their size (atrophy) (Parra *et al.*, 2011) and their ability to digest and absorb nutrients (Fre *et al.*, 2005; Suzuki *et al.*, 2005; Ciro *et al.*, 2013). For these reasons, the intestinal morphometric parameters of this study demonstrated a significant decrease in those animals that consumed the commercial diet with or without the addition of antibiotics as compared to the diets supplemented

with probiotic strains. However, those animals that consumed the diet supplemented with antibiotics (D2), despite having high values, never exceeded the values obtained of the animals that consumed the diets supplemented with the probiotic strains (Figure 1), in agreement with the results of Sou (2012), who reported a morphological atrophy of the villi and hyperplasia of the crypts in animals that were weaned and provided a commercial diet (supplemented with antibiotics), while animals that consumed a diet supplemented with *Lactobacillus plantarum* exhibited the highest value for the villi height. This suggests that feed with lactic acid bacteria can help re-stabilize the equilibrium of the gastrointestinal tract in new born pigs and during the productive age (Kang, 2010).

There are various indicators that describe suitable intestinal functions, among which is the integrity of the villi, for which Siggers (2014) reported that, when providing swine colostrum with a combination of lactic acid bacteria (*L. Plantarum*, *L. acidophilus*, *L. casei*) to piglets, there was not significance in the variables of villi height or crypt depth, which suggests that the effect of probiotics favors intestinal integrity and digestive functions, as seen with sow colostrum, which upon contact with the microflora of the nipple, increases the concentration of lactic acid bacteria. Therefore, in our study, the animals that consumed the diets that were supplemented with probiotics not only demonstrated an increase in the height and width of the villi, but also a decrease in the depth and width of the crypts, as compared to the pigs that consumed the commercial diet with and without the addition of antibiotics.

Similarly, Wang (2013) reported that *E. faecium* not only improved the function of the intestinal barrier, but also, decreases the pathogenic bacteria colonization and infiltration by toxins, thereby preventing the characteristic diarrhea of the weaning period. Because of this, the animals fed D5 (*E. faecium*) in this study, reported improvements morphometric parameters, which could increase the capacity of the enzyme secretion and absorption in the duodenum and jejunum of pigs.

CONCLUSIONS

The use of probiotics, particularly *E. faecium* in animal nutrition in the growing period is an excellent nutritional alternative treatment strategy to the use of antimicrobial compounds because probiotics improve the intestinal morphometric parameters, and subsequently digestive and productive parameters of the animals. Therefore, the use of probiotics as additives in the production of balanced animal feed not only assures the optimal development and maintenance of the intestinal morphometric parameters in the intestinal architecture, such as the villi and crypts, but could also stimulates the immune response and the nutrient absorption. Work is in progress to investigate the effects of probiotic supplementation on the gut microbiota, and in turn improved the understanding of the mechanisms by which probiotics cause changes in the digestive physiology, and stimulation of the immune system and,

in this way, to develop strategies providing solution the enteric problems found in the critical post-weaning period.

REFERENCES

- Bednorz, C., S. Guenther, K. Oelgeschläger, B. Kinnemann, R. Pieper, S. Hartmann, K. Tedin, T. Semmler, K. Neumann, P. Schierack, A. Bethe and L.H. Wieler. 2013. Feeding the probiotic *Enterococcus faecium* strain NCIMB 10415 to piglets specifically reduces the number of *Escherichia coli* pathotypes that adhere to the gut mucosa. *Applied Environmental Microbiology* 79(24): 7896-904. doi: 10.1128/AEM.03138-13.
- Cabrera, R.A., J.L. Usry, C. Arrellano, E.T. Nogueira, M. Kutschenko, A.J. Moeser and J. Odle. 2013. Effects of creep feeding and supplemental glutamine or glutamine plus glutamate (Aminogut) on pre- and post-weaning growth performance and intestinal health of piglets. *Journal of Animal Sciences and Biotechnology* 4(1): 29. doi: 10.1186/2049-1891-4-29
- Campbell, J.M., J.D. Crenshaw and J. Polo. 2013. The biological stress of early weaned piglets. *Journal of Animal Sciences and Biotechnology* 4(1): 19. doi: 10.1186/2049-1891-4-19
- CIOIMS. Council For International Organization Of Medical Sciences And The International Council For Laboratory Animal Science. 2012. International guiding principles for biomedical research involving animals. Disponible en: http://grants.nih.gov/grants/olaw/Guiding_Principles_2012.pdf
- Ciro, J.A., A. López and J.E. Parra. 2013. Expresión molecular de la vilina en yeyuno de lechones posdestete que consumieron LPS de *E. coli*. *Revista CES Medicina Veterinaria y Zootecnia* 8(2): 32-41. doi: 10.15446/rfmvz.v61n2.44677
- DiRienzo, D.B. 2014. Effect of probiotics on biomarkers of cardiovascular disease: implications for heart-healthy diets. *Nutrition Reviews* 72(1): 18-29. doi: 10.1111/nure.12084
- FAO/OMS. Organización de las Naciones Unidas para la Agricultura y la Alimentación. 2006. Probióticos en los alimentos, propiedades nutricionales y directrices para la evaluación. Disponible en: <ftp://ftp.fao.org/docrep/fao/009/a0512s/a0512s00.pdf>
- Farzan, A., J. Kircanski, J. DeLay, G. Soltes, J.G. Songer, R. Friendship and J.F. Prescott. 2013. An investigation into the association between *cpb2*-encoding *Clostridium perfringens* type A and diarrhea in neonatal piglets. *Canadian Journal of Veterinary Research* 77(1): 45-53.
- Fleisch, A.G., A.K. Poziomyck and D. de C. Damin. 2014. The therapeutic use of symbiotics. *ABCD: Arquivos Brasileiros de Cirurgia Digestiva* 27(3): 206-209. doi: 10.1590/s0102-67202014000300012
- Fre S, M. Huyghe, P. Mourikis, S. Robine, D. Louvard and S. Artavanis-Tsakonas. 2005. Notch signals control the fate of immature progenitor cells in the intestine. *Nature* 435: 964-968.
- Ghosh, T.S., S.S. Gupta, G.B. Nair and S.S. Mande. 2013. In silico analysis of antibiotic resistance genes in the gut microflora of individuals from diverse geographies and age-groups. *PLoS One* 8(12): e83823. doi: 10.1371/journal.pone.0083823
- Gómez IAS, D. Vergara and F. Argote. 2008. Efecto de la dieta y edad del destete sobre la fisiología digestiva del lechón. *Revista Biotecnología en el Sector Agropecuario y Agronómico* 6: 32-41.
- Jacobi, K.S., J.A. Moeser, T.A. Blikslager, M.J. Rhoads, A.B. Corl, J.R. Harrell and J. Odle. 2013. Acute effects of rotavirus and

- malnutrition on intestinal barrier function in neonatal piglets. *World Journal of Gastroenterology* 19(31): 5094–5102. doi: 10.3748/wjg.v19.i31.5094
- Kang, P., D. Toms, Y. Yin, Q. Cheung, J. Gong, K. De Lange and J. Li. 2010. Epidermal growth factor-expressing *Lactococcus lactis* enhances intestinal development of early-weaned pigs. *The Journal of Nutrition*. 140(4): 806-811. doi: 10.3945/jn.109.114173
- Klingspor S, H. Martens, D. Caushi, S. Twardziok, J.R. Aschenbach and U. Lodemann. 2013. Characterization of the effects of *Enterococcus faecium* on intestinal epithelial transport properties in piglets. *Journal of Animal Science*; 91(4): 1707-1718. doi: 10.2527/jas.2012-5648
- Lallès J.P., S. Konstantinov and H.J. Rothkötter. 2004. Bases physiologiques, microbiologiques et immunitaires des troubles digestifs du sevrage chez le porcelet: données récentes dans le contexte de la suppression des antibiotiques additifs alimentaires. *Journées Recherche Porcine*. 2004; 36: 139-150.
- Marion, J., M. Biernat, F. Thomas, G. Savary, Y. Le Breton, R. Zabielski, I. Le Huërou-Lurona and J. Le Dividich. 2002. Small intestine growth and morphometry in piglets weaned at 7 days of age. Effects of level of energy intake. *Reproduction and Nutrition Development* 42: 339–354. doi: 10.1051/rnd:2002030
- Mitsuoka, T. 2014. Development of functional foods. *Bioscience of Microbiota, Food and Health* 33(3): 117-28.
- Müller A, M. Oertli and I.C. Arnold. 2011. Pylori exploits and manipulates innate and adaptive immune cell signaling pathways to establish persistent infection. *Cell Communication and Signaling*. 9(1): 25. doi: 10.1186/1478-811X-9-25.
- NRC. 2012. National Research Council. *The Nutrient Requirements of Swine*. 8th rev. ed. Washington, DC, USA: National Academy Press.
- Parra, S.J., T.J. Agudelo, M.C. Ramírez, B. Rodríguez and H.A. López. 2011. Lipopolysaccharide (LPS) from *E. coli* has detrimental effects on the intestinal morphology of weaned pigs. *Revista Colombiana de Ciencias Pecuarias* 24: 598-608.
- Reis, S.T.C., C.M.J. Guerrero, B.A. Aguilera and L.G. Mariscal. 2005. Efecto de diferentes cereales sobre la morfología intestinal de lechones recién destetados. *Revista Mexicana de Ciencias Pecuarias* 43: 309-321.
- Reis, S.T.C., L.G. Mariscal, B.A. Aguilera and J.G.H. Cervantes. 2007. Digestibilidad de la proteína y energía en dietas para lechones complementadas con tres diferentes tipos de suero de leche deshidratado. *Veterinaria México* 38: 141-151.
- SAS®. SAS/STAT User's Guide. Institute Inc. Statistical Analysis Systems Institute. Version 9.1th Ed. Cary, NC: SAS Institute Inc. 2007.
- Schokker, D., J. Zhang, L.L. Zhang, S.A. Vastenhouw, H.G. Heilig, H. Smidt, J.M. Rebel and M.A. Smits. 2014. Early-life environmental variation affects intestinal microbiota and immune development in new-born piglets. *PLoS One*. 9(6): e100040. doi: 10.1371/journal.pone.0100040
- Segalés, J y M. Domingo. 2003. La necropsia en el ganado porcino, diagnóstico anatomopatológico y toma de muestras. *Boehringer Ingelheim S.A, Madrid, España*. 128 p.
- Siggers, R.H., J. Siggers, M. Boye, T. Thymann, L. Molbak, T. Leser, B.B. Jensen and P.T. Sangild. 2008. Early administration of probiotics alters bacterial colonization and limits diet-induced gut dysfunction and severity of necrotizing enterocolitis in preterm pigs. *The Journal of Nutrition* 138(8): 1437-44. doi: 10.1152/ajpgi.00414.2007
- Songisepp, E., P. Hütt, M. Rätsep, E. Shkut, S. Kõljalg, K. Truusalu, J. Stsepelova, I. Smidt, H. Kolk, M. Zagura and M. Mikelsaar. 2012. Safety of a probiotic cheese containing *Lactobacillus plantarum* Tensia according to: A variety of health indices in different age groups. *Journal of Dairy Science* 95(10): 5495-509. doi: 10.3168/jds.2011-4756
- Suo C, Y. Yin, X. Wang, X. Lou, D. Song, X. Wang and Q. Gu. 2012. Effects of *Lactobacillus plantarum* ZJ316 on pig growth and pork quality. *BMC Veterinary Research*. 25; 8: 89-101. doi: 10.1186/1746-6148-8-89.
- Suzuki K, H. Fukui, T. Kayahara, M. Sawada, H. Seno, H. Hiai, R. Kageyama, H. Okano and T. Chiba. 2005. Hes1-deficient mice show precocious differentiation of Paneth cells in the small intestine. *Biochemical and Biophysical Research Communications* 328: 348–352.
- Vente-Spreeuwenberg M.A.M., A.C. Verdonk, H.R. Gaskins, and M.W.A. Verstegen. 2001. Small intestine epithelial barrier function is compromised in pigs with low feed intake at weaning. *Journal of Nutrition* 131: 1520-1527.
- Wang Z, W. Chai, M. Burwinkel, S. Twardziok, P. Wrede, C. Palissa, B. Esch and M.F. Schmidt. 2013. Inhibitory influence of *Enterococcus faecium* on the propagation of swine influenza: A virus *in vitro*. *PLoS One*8(1): e53043. doi: 10.1371/journal.pone.0053043.
- Zeyner, A and E. Boldt. 2006. Effects of a probiotic *Enterococcus faecium* strain supplemented from birth to weaning on diarrhoea patterns and performance of piglets. *Journal of Animal Physiology and Animal Nutrition* 90: 25–31.
- Zhenfeng Z, O. Deyuan, P. Xiangshu, W.K. Sung, L. Yanhong and W. Junjun. 2008. Dietary arginine supplementation affects microvascular development in the small intestine of early-weaned pigs. *Journal of Nutrition* 138: 1304-1309.

