

Nathaniel W. Yang, MD

¹Department of Otolaryngology-Head and Neck Surgery
College of Medicine - Philippine General Hospital
University of the Philippines Manila

²Department of Otolaryngology -Head and Neck Surgery
Far Eastern University - Nicanor Reyes Medical Foundation
Institute of Medicine

Fracture of the Petrous Carotid Canal

A 23-year-old male motorcyclist experienced blunt head trauma with loss of consciousness, headache and vomiting, epistaxis and right otorrhagia after a collision with a motor vehicle. Fractures involving the right parietal and temporal bones, as well as acute subdural and subarachnoid hemorrhage were identified on a cranial and facial CT scan. On independent evaluation of the imaging study, a subtle but distinct fracture line in the skull base involving the petrous carotid canal was identified. (Figure 1) The patient subsequently underwent CT angiography to evaluate for any injury to the internal carotid artery. In this examination, good opacification of the internal carotid arteries and their branches was noted, with no evident aneurysm, arteriovenous malformation or arteriovenous fistula formation.

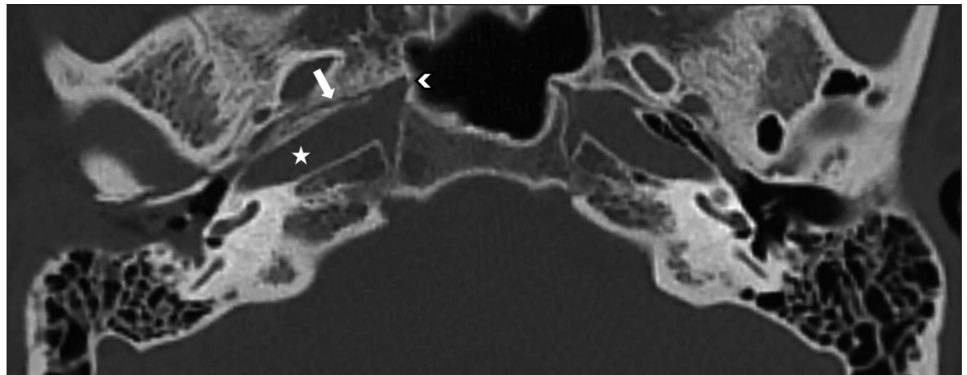


Figure 1. Axial CT image at the level of the basal turn of the cochlea. A fracture line runs longitudinally in the right skull base (white arrow). It extends into the petrous carotid canal (white star) and the posterolateral wall of the sphenoid sinus (white chevron).

In patients with temporal bone fractures, the most commonly encountered complications are: tympano-ossicular injury causing conductive hearing loss, cochlear or vestibular injury causing sensorineural hearing loss or vertigo, facial nerve trauma causing facial paralysis, and fractures of the tegmen or posterior cranial fossa plate causing cerebrospinal fluid leaks.¹ On the other hand, injury to the intratemporal portion of the internal carotid artery has been described as a rare complication and as such may be overlooked.¹ However, its potentially devastating and life-threatening sequelae necessitates a purposeful and intentional evaluation for its presence. These sequelae include brain ischemia from arterial dissection or complete vascular occlusion, exsanguinating epistaxis or otorrhagia from carotid pseudoaneurysms, and the formation of carotid-cavernous fistulas.² The incidence of involvement of the carotid canal in skull base fractures has been reported to be around 24%, with around 11% of this group developing internal carotid artery injuries.³ As such, the presence of fractures involving the petrous carotid canal is an indication for CT or MR angiography to further evaluate the internal carotid artery.⁴

Correspondence: Dr. Nathaniel W. Yang
Department of Otolaryngology – Head and Neck Surgery
University of the Philippines Manila
Ward 10, Philippine General Hospital, Taft Avenue
Ermita, Manila 1000
Philippines
Phone: (632) 8526 4360
Telefax: (632) 8525 5444
Email: nwyang@up.edu.ph

The author declared that this represents original material, that the manuscript has been read and approved by the author, that the requirements for authorship have been met by the author, and that the author believes that the manuscript represents honest work.

Disclosures: The author signed a disclosure that there are no financial or other (including personal) relationships, intellectual passion, political or religious beliefs, and institutional affiliations that might lead to a conflict of interest.



Creative Commons (CC BY-NC-ND 4.0)
Attribution - NonCommercial - NoDerivatives 4.0 International

REFERENCES

1. Diaz RC, Cervenka B, Brodie HA. Treatment of Temporal Bone Fractures. *J Neurol Surg B Skull Base*. 2016 Oct;77(5):419-29. DOI: 10.1055/s-0036-1584197; PubMed PMID: 27648399; PubMed Central PMCID: PMC5023437.
2. Varo Alonso M, Utrilla Contreras C, Diez Tascón Á, García Raya PS, Martí de Gracia M. Traumatic Injury of the Petrous Part of the Temporal Bone: Keys for Reporting a Complex Diagnosis. *Radiologia (Engl Ed)*. 2019 May-Jun;61(3):204-214. English, Spanish. DOI: 10.1016/j.rx.2018.12.005; PubMed PMID: 30777299.
3. Resnick DK, Subach BR, Marion DW. The significance of carotid canal involvement in basilar cranial fracture. *Neurosurgery*. 1997 Jun;40(6):1177-81. DOI: 10.1097/00006123-199706000-00012; PubMed PMID: 9179890.
4. Kurihara YY, Fujikawa A, Tachizawa N, Takaya M, Ikeda H, Starkey J. Temporal Bone Trauma: Typical CT and MRI Appearances and Important Points for Evaluation. *Radiographics*. 2020 Jul-Aug;40(4):1148-1162. DOI: 10.1148/rg.2020190023; PubMed PMID: 32442046.