



Joyce Anne F. Regalado-Go, MD
Terrence Jason Flores, MD
Al E. Santiago, MD

Department of Otolaryngology-Head and Neck Surgery
'Amang' Rodriguez Memorial Medical Center

Correspondence: Dr. Al E. Santiago
Department of Otolaryngology-Head and Neck Surgery
'Amang' Rodriguez Memorial Medical Center
Sumulong Highway Sto. Nino, Marikina 1800
Philippines
Fax: (632) 8941 3441
Email: E-mail: doc_al_santiago@yahoo.com

The authors declared that this presents original material that is not being considered for publication or has not been published or accepted for publication elsewhere or in part, in print or electronic media; that the requirements for authorship have been met by all the authors, and the authors believe that the manuscript represents honest work.

Disclosures: The authors signed a disclosure that there are no financial or other (including personal) relationship, intellectual passion, political or religious beliefs, and institutional affiliations that might lead to conflict of interest.

Presented at the 62nd PSO-HNS Annual Convention and IFHNOS World Tour held on October 22, 2018 at the Manila Hotel, Philippines and at the Philippine Society of Otolaryngology Head and Neck Surgery 1st virtual Surgical Instrumentation Contest (3rd Place), November 25, 2020.



Creative Commons (CC BY-NC-ND 4.0)
Attribution - NonCommercial - NoDerivatives 4.0 International

Single Stage Transoral Cordectomy and Medialization Thyroplasty in Early Glottic Squamous Cell Carcinoma: A Case Report

ABSTRACT

Objective: To present the case of a 78-year-old man with Glottic SCCa stage I who underwent single stage transoral cordectomy type IV with medialization thyroplasty under general anesthesia.

Methods:

Design: Case Report
Setting: Tertiary Government Training Hospital
Patient: One

Results: Postoperatively, patient was able to phonate and gave a VHI score of 12 and GRBAS score of 4. He was able to resume oral feeding without any signs of aspiration. Postoperative flexible laryngoscopy showed fully mobile vocal cords with good approximation in the midline.

Conclusion: This report suggests that vocal cord medialization via thyroplasty may be performed after cordectomy in a single stage, providing acceptable postoperative voice as well as good swallowing outcome.

Keywords: *thyroplasty; laryngeal cancer; squamous cell carcinoma; glottis; vocal cord; cordectomy*

Laryngeal Squamous cell carcinoma (SCCa) is one of the most common malignancies of the head and neck. In the Philippines, it ranked 17th with an incidence rate of 1% in both sexes, the 10th most common among men (3%), and the 21st among women (0.5%).¹ With the advent of endoscopy, diagnosis of early (T1-T2) laryngeal SCCa enabled surgeons to manage these patients early in the course of the disease.² With deeper knowledge of laryngeal compartmentalization as well as early diagnosis, the management of early glottic SCCa has shifted from total laryngectomy to larynx-preserving surgery.²

Transoral Cordectomy is the mainstay of treatment for early glottic SCCa. It provides excellent local control and laryngeal preservation.³ Although it is considered superior compared to other modalities, it has its disadvantages. Postoperative complications such as dysphonia and aspiration are correlated with the amount of tissue resected.⁴ Type III and IV cordectomy, which involve trans muscular approach and total cordectomy respectively, are associated with persistent dysphonia postoperatively.⁵ One way to address these postoperative complications is by medialization via type I thyroplasty.⁶ The current practice in applying this technique after cordectomy is to wait for at least 6 -12 months to allow for adequate wound healing as well as postoperative surveillance for tumor recurrence.⁴ However, during the interval prior to planned phonosurgery, patients may suffer from postoperative dysphonia and aspiration resulting in decreased quality of life and a higher incidence of complications.

In this report, we present our case of a 78-year-old man diagnosed with stage I Glottic SCCa (T1N0M0) who underwent transoral cordectomy type IV combined with medialization thyroplasty in a single stage approach. To the best of our knowledge, such procedures done in a single stage setting have not been previously reported.

CASE REPORT

A 78-year-old man consulted at our out-patient clinic with a 6-month history of hoarseness and Voice Handicap Index (VHI) of 46 with GRBAS score of 11 (G3R2B2A2S2) without any signs of dyspnea nor dysphagia. He was a known smoker and alcoholic beverage drinker with no familial history of carcinoma.

Indirect laryngoscopy revealed a white plaque on his left vocal cord. Neck examination was unremarkable. Laryngeal computed tomography (CT) showed a soft tissue prominence of the left glottic cord relative to the right with no enlarged lymph node seen. (Figure 1) He underwent direct laryngoscopy with biopsy that showed a diffuse whitish plaque extending from the anterior to posterior part of the left true vocal cord and a white plaque at the anterior 1/3 of the right true vocal cord. (Figure 2) Histopathological report revealed keratinizing squamous cell carcinoma of the left vocal cord and squamous metaplasia on the right. We diagnosed glottic SCCa stage I (T1a N0 M0). A single stage transoral type IV cordectomy of the left with simultaneous medialization thyroplasty under general anesthesia was planned.

Our patient underwent cordectomy type IV under direct suspension laryngoscopy. While maintaining direct suspension, we proceeded with vocal cord medialization type I thyroplasty type using Gore-Tex implant (Figure 3, 4) maintaining an intact inner perichondrium. Postoperatively, our patient was able to phonate and resume oral feeding. No dyspnea nor aspiration were noted. Postoperative flexible laryngoscopy showed

fully mobile vocal cords with good approximation in the midline on phonation. The patient was discharged on his 3rd hospital day.

He was followed up every month based on the National Comprehensive Cancer Network (NCCN) guidelines. Flexible endoscopy and FEES done after 1 month (Figure 5) and 3 months (Figure 6) post-surgery yielded no aspiration and no tumor recurrence. On both

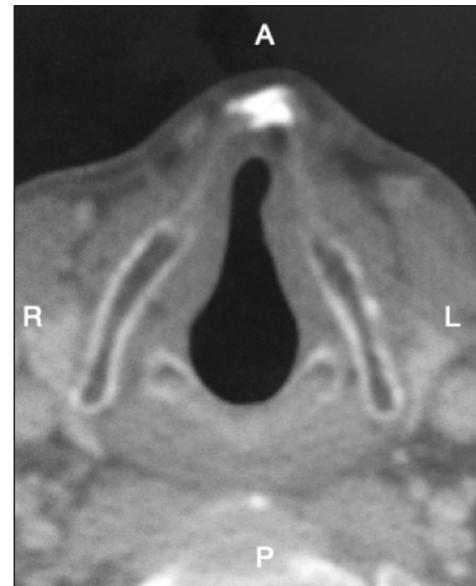


Figure 1. Laryngeal CT scan with contrast, axial view, showing a soft tissue prominence of the left glottic cord relative to the right.

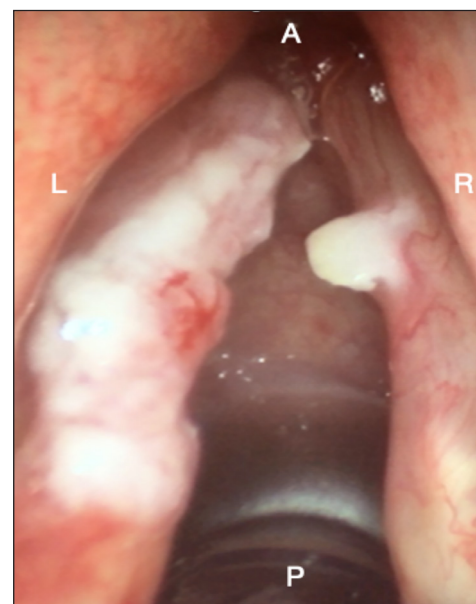


Figure 2. Intraoperative direct laryngoscopy findings showing a diffuse whitish plaque at the anterior 2/3 of the left true vocal cord extending anteriorly, sparing the anterior commissure, and posteriorly, sparing the vocal process of the arytenoid. The white blob on the anterior 1/3 of the right true vocal cord was mucoid material that was easily removed with a cottonoid swab without any underlying mucosal findings. L, left; R, right; A, anterior; P, posterior.

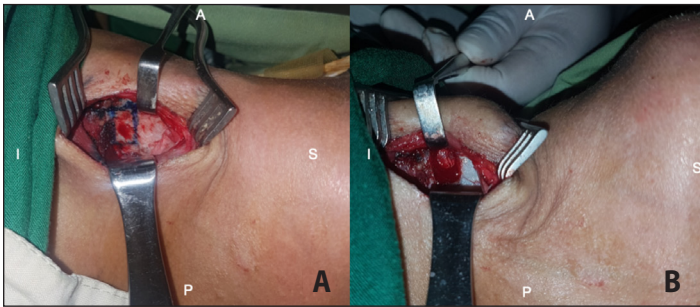


Figure 3. A. Marking of tracheal window on the left thyroid cartilage; and B. Tracheal window created, with intact perichondrium seen in the window. A, anterior; P, posterior; S, superior; I, inferior.

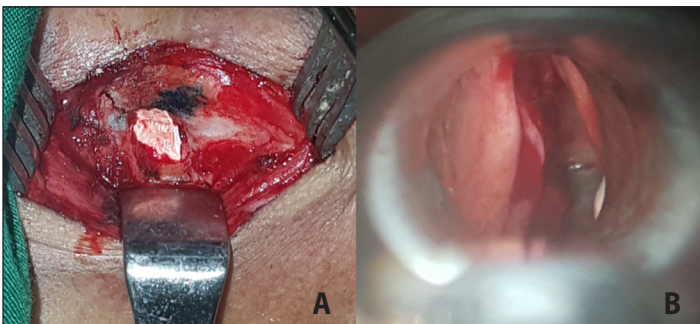


Figure 4. A. Goretex implant inserted through the tracheal window allowing medialization of the remaining left glottis; and B. Transalaryngeal inspection via direct suspension laryngoscopy showing medialization of left glottis.

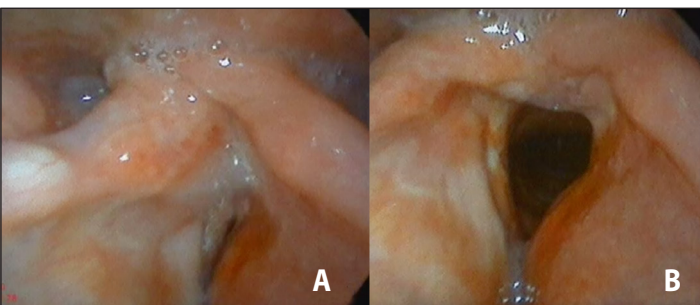


Figure 5. One-month postoperative flexible laryngoscopy showing mobile true vocal cords with A. good glottic closure; and B. full abduction; note pooling of saliva.

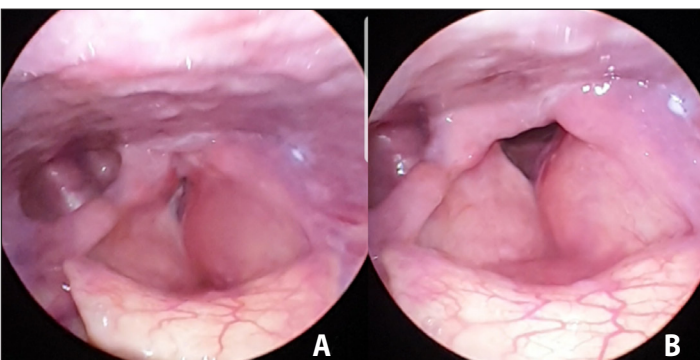


Figure 6. Three-month postoperative flexible laryngoscopy showing fully mobile vocal cords with A. good glottic closure; and B. full abduction; no pooling of saliva noted.

occasions, a VHI score of 12 and GRBAS score of 4 (G1R1B0A1S1) was obtained showing significant improvement in dysphonia.

DISCUSSION

Based on the NCCN 2020 guidelines, the recommended treatment options for patients with early glottic SCCa (T1) include endoscopic/ open resection, partial laryngectomy, or radiotherapy.⁷ Whereas different studies argue the superiority of one treatment modality over another, the choice depends on the patient’s wishes, anticipated functional outcome, reliability of follow-up, and general medical condition. These options were presented to the patient, and he opted for transoral cold steel cordectomy.

Transoral microsurgery is associated with several postoperative complications due to the extent of the surgical approach. Resulting glottic incompetence causes dysphonia and aspiration.^{8,9} These complications are especially associated with type IV cordectomy, which includes complete cordectomy that extends from the vocal process to the anterior commissure, and type V cordectomy, which is an extended cordectomy encompassing a contralateral cord (Type Va) or the arytenoid (Type Vb).⁵ The incidence of postoperative aspiration occurs at a rate of 2.1% to 11.5% in various studies.¹⁰⁻¹⁴ These resulting complications are usually managed conservatively with voice therapy and speech rehabilitation. However, this only marginally attenuates complications due to the wide glottic gap resulting from the procedure. In these cases, medialization thyroplasty is commonly performed to ameliorate glottal closure.⁹

Historically, type I thyroplasty or medialization thyroplasty which was popularized by Isshiki is used in patients with disease causing imperfect closure of the glottis during phonation such as vocal cord paralysis or atrophy.⁶ Recent applications of this procedure include the management of patients who develop postoperative dysphonia after cordectomy for laryngeal carcinoma.¹⁴ The timing of thyroplasty after cordectomy is usually 6-12 months to allow for scar maturation and for surveillance of tumor recurrence.^{9,14,16} Moreover, maintaining an intact perichondrium is crucial to preserve laryngeal compartmentalization and intralaryngeal barriers.^{16,17} Performing medialization thyroplasty after cordectomy is widely documented in literature.^{18,19} However, to the best of our knowledge, these two procedures have not been performed in tandem for early glottic SCCa, based on a search of HERDIN Plus, the ASEAN Citation Index (ACI), the Global Index Medicus - Western Pacific Region Index Medicus (WPRIM) and Index Medicus of the South East Asia Region (IMSEAR), the Directory of Open Access Journals (DOAJ), PubMed MEDLINE, Google Scholar, and Cochrane Library using the keywords (“single-stage” AND “cordectomy” AND [“medialization thyroplasty” OR “thyroplasty type I”]).



In our case, we performed a single stage transoral cordectomy together with medialization thyroplasty and achieved good postoperative outcome. We believe that this combined technique is an acceptable option for the management of early stage glottic SCCa especially in patients who cannot tolerate or are unable to undergo a second stage procedure. More importantly, this combined technique may enable the surgeon to improve dysphonia immediately and simultaneously prevent if not eliminate aspiration symptoms post-surgery. We hope that more cases will support our experience.

REFERENCES

1. Laudico AV, Mirasol-Lumague MR, Medina VM, Mapa CA, Valenzuela F, Pukkala E. Philippines Cancer Facts and Estimates. *Philippine Cancer Society*. Available from: http://www.philcancer.org.ph/wp-content/uploads/2017/07/2015-PCS-Ca-Facts-Estimates_CAN090516.pdf.
2. Chawla S, Carney AS. Organ preservation surgery for laryngeal cancer. *Head Neck Oncol*. 2009 May 15;1:12. DOI: 10.1186/1758-3284-1-12; PubMed PMID: 19442314; PubMed Central PMCID: PMC2686690.
3. Sigston E, de Mones E, Babin E, Hans S, Hartl DM, Clement P, et al. Early-stage glottic cancer: oncological results and margins in laser cordectomy. *Arch Otolaryngol Head Neck Surg*. 2006 Feb; 132(2):147-152. DOI: 10.1001/archotol.132.2.147; PubMed PMID: 16490871.
4. Bertelsen C, Reder L. Efficacy of type I thyroplasty after endoscopic cordectomy for early-stage glottic cancer: literature review. *Laryngoscope*. 2018 Mar;128(3):690-696. DOI: 10.1002/lary.26877; PubMed PMID: 29314074.
5. Remacle M, Eckel HE, Antonelli A, Brasnu D, Chevalier D, Friedrich G, et al. Endoscopic cordectomy. a proposal for a classification by the Working Committee, European Laryngological Society. *Eur Arch Otorhinolaryngol*. 2000; 257(4), 227-231. PubMed PMID: 10867840.
6. Isshiki N, Okamura H, Ishikawa T. Thyroplasty type I (lateral compression) for dysphonia due to vocal cord paralysis or atrophy. *Acta Otolaryngol*. 1975 Nov-Dec;80(5-6):465-473. DOI: 10.3109/00016487509121353; PubMed PMID: 1202920.
7. National Comprehensive Cancer Network (NCCN) [homepage on the Internet]. NCCN Guidelines (Head and Neck Cancers) version 2020 Cancer of the Glottic Larynx [cited 21 Feb 2020]. Available from: <https://www.nccn.org/guidelines/guidelines-detail?category=1&id=1437>.
8. Peretti G, Piazza C, Del Bon F, Mora R, Grazioli P, Barbieri D, et al. Function preservation using transoral laser surgery for T2–T3 glottic cancer: oncologic, vocal, and swallowing outcomes. *Eur Arch Otorhinolaryngol*. 2013 Aug;270(8):2275-81. DOI: 10.1007/s00405-013-2461-9; PubMed PMID: 23568037.
9. Piazza C, Villaret AB, De Zinis LOR, Cattaneo A, Cocco D, Peretti G. Phonosurgery after endoscopic cordectomies. II. Delayed medialization techniques for major glottic incompetence after total and extended resections. *Eur Arch Otorhinolaryngol*. 2007 Oct;264(10):1185-90. DOI: 10.1007/s00405-007-0330-0; PubMed PMID: 17534641.
10. Galli A, Giordano L, Sarandria D, Di Santo D, Bussi M. Oncological and complication assessment of CO2 laser-assisted endoscopic surgery for T1-T2 glottic tumours: clinical experience. *Acta Otorhinolaryngol Ital*. 2016 Jun;36(3):167-73. DOI: 10.14639/0392-100X-643; PubMed PMID: 27214828; PubMed Central PMCID: PMC4977004.
11. Sjögren EV. Transoral laser microsurgery in early glottic lesions. *Curr Otorhinolaryngol Rep*. 2017;5(1):56-68. DOI: 10.1007/s40136-017-0148-2; PubMed PMID: 28367361; PubMed Central PMCID: PMC5357474.
12. Estomba CMC, Reinoso FAB, Velasquez AO, Fernandez JLR, Conde JLF, Hidalgo CS. Complications in CO2 laser transoral microsurgery for larynx carcinomas. *Int Arch Otorhinolaryngol*. 2016 Apr;20(2):151-5. DOI: 10.1055/s-0035-1569145; PubMed PMID: 27096020; PubMed Central PMCID: PMC4835325.
13. Roh JL, Kim DH, Park CI. Voice, swallowing and quality of life in patients after transoral laser surgery for supraglottic carcinoma. *J Surg Oncol*. 2008 Sep 1;98(3):184-9. DOI: 10.1002/jso.21101; PubMed PMID: 18561157.
14. Ford CN, Bless DM, Prehn RB. Thyroplasty as primary and adjunctive treatment of glottic insufficiency. *J Voice*. 1992 Jan 1; 6(3):277-285. DOI: [https://doi.org/10.1016/S0892-1997\(05\)80154-7](https://doi.org/10.1016/S0892-1997(05)80154-7).
15. Demir UL, Çevik T, Kasapoğlu F. Is there a change in the treatment of T1 glottic cancer after CO2 laser? A comparative study with cold steel. *Türk Arch Otorhinolaryngol*. 2018 Jun;56(2):64-69. DOI:10.5152/tao.2018.3053; PubMed PMID: 30197801; PubMed Central PMCID: PMC6123107.
16. Sittel C, Friedrich G, Zorowka P, Eckel HE. Surgical voice rehabilitation after laser surgery for glottic carcinoma. *Ann Otol Rhinol Laryngol*. 2002 Jun;111(6):493-9. DOI: 10.1177/000348940211100604; PubMed PMID: 12090704.
17. Kirchner JA, Carter D. Intralaryngeal barriers to the spread of cancer. *Acta Otolaryngol*. May-Jun 1987;103(5-6):503-13. PubMed PMID: 3618179.
18. Kirchner JC, Kirchner JA, Sasaki CT. Anatomic foramina in the thyroid cartilage: incidence and implications for the spread of laryngeal cancer. *Ann Otol Rhinol Laryngol*. 1989 Jun; 98(6), 421-425. DOI:10.1177/000348948909800604; PubMed PMID: 2729824.
19. Zapater E, Oishi N, Hernandez R, Bastera J. Medialization thyroplasty under intubation anesthesia to restore the voice after cordectomy. *Laryngoscope*. 2016 Jun;126(6):1404-7. DOI: 10.1002/lary.25600; PubMed PMID: 26372050.