



EDITORIAL

- 4 **Death and Dying During the COVID-19 Pandemic:**
Tahan Na, Humimlay
Lapeña JFF

REVIEW ARTICLE

- 6 **Prevalence of Olfactory Dysfunction Among COVID-19 Patients with Self-Reported Smell Loss Versus Objective Olfactory Tests: A Systematic Review and Meta-Analysis**
Regalado JAF, Tayam MMH, Santos RA, Gelera JE

ORIGINAL ARTICLES

- 15 **Self-Reported Assessment of Outcome-Based Education in Philippine Otolaryngology - Head and Neck Surgery Residency Training Programs by Consultants and Residents**
Almazan MNA
- 24 **Classification and Stages of Middle Ear Cholesteatoma at the Southern Philippines Medical Center Using the European Academy of Otolaryngology and Neurotology / Japan Otological Society (EAONO / JOS) System**
Toral DB, Laganao CRD
- 28 **Predominant Endotype of Nasal Polyps in a Sample of Filipinos Following Endoscopic Sinus Surgery for Chronic Rhinosinusitis with Nasal Polyposis**
Nabile-Llanes KV, Roldan RA
- 33 **Association of Anosmia and Positive SARS-CoV-2 (COVID-19) RT-PCR Test Results Among Patients in the Quezon City General Hospital**
Alega JJP, Cruz ETS

CASE REPORTS

- 37 **Smell Training in Prolonged COVID-19 Post-Infectious Olfactory Dysfunction: A Case Report**
Villar PMAC, Chua RU, Robles RP
- 41 **Self-Inflicted Craniofacial Impalement Injury with a Screwdriver During the COVID-19 Pandemic: A Case Report**
Gatela JLJG
- 45 **To the Lip and Beyond: A Case Report of a Midline Tessier 30 Cleft**
Suarez JDC, Perez GCC

SURGICAL INNOVATIONS AND INSTRUMENTATION

- 50 **The Use of Commercially Available Non-Medical Grade USB Cameras for Physician Guided ENT Out-Patient Self-Examination During the COVID-19 Pandemic**
Cafino RY

PRACTICE PEARLS

- 57 **Understanding the Use of Polycaprolactone in East Asian Structural Rhinoplasty: Questions and Answers**
Yap EC

FEATURED GRAND ROUNDS

- 62 **Delayed Sudden Blindness From Unilateral Ophthalmic Artery Vasospasm Following Endoscopic Sinus Surgery?**
Chua RJ, Regalado JAF, Gelera JE

FROM THE VIEWBOX

- 65 **Fenestral Otosclerosis: A Subtle Lesion Easily Missed**
Yang NW

UNDER THE MICROSCOPE

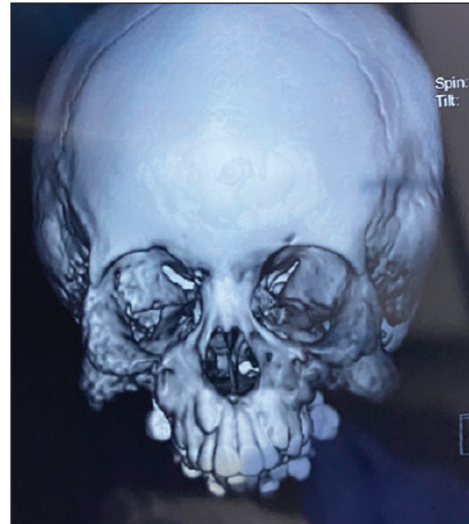- 67 **Inverted Ductal Papilloma of the Salivary Gland**
Carnate JM

CAPTOONS

- 69 **Doknet's World**
Billones WU

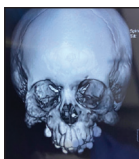PASSAGES

- 70 **Elvira I. Colmenar, MD**
Colmenar MTI
- 71 **Ruben G. Henson, Jr., MD**
Henson RD
- 72 **Marlon V. del Rosario, MD**
Calderon AF
- 73 **Oliverio O. Segura, MD**
Segura PPR

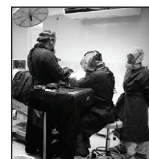

Death and Dying During the COVID-19 Pandemic: *Tahan Na, Humimlay*
 Prevalence of Olfactory Dysfunction Among COVID-19 Patients with Self-Reported Smell Loss Versus Objective Olfactory Tests: A Systematic Review and Meta-Analysis
 Self-Reported Assessment of Outcome-Based Education in Philippine Otolaryngology - Head and Neck Surgery Residency Training Programs by Consultants and Residents
 Classification and Stages of Middle Ear Cholesteatoma at the Southern Philippines Medical Center Using the European Academy of Otolaryngology and Neurotology / Japan Otological Society (EAONO / JOS) System
 Predominant Endotype of Nasal Polyps in a Sample of Filipinos Following Endoscopic Sinus Surgery for Chronic Rhinosinusitis with Nasal Polyposis
 Association of Anosmia and Positive SARS-CoV-2 (COVID-19) RT-PCR Test Results Among Patients in the Quezon City General Hospital
 Smell Training in Prolonged COVID-19 Post-Infectious Olfactory Dysfunction: A Case Report
 Self-Inflicted Craniofacial Impalement Injury with a Screwdriver During the COVID-19 Pandemic: A Case Report
 To the Lip and Beyond: A Case Report of a Midline Tessier 30 Cleft
 The Use of Commercially Available Non-Medical Grade USB Cameras for Physician Guided ENT Out-Patient Self-Examination During the COVID-19 Pandemic
 Understanding the Use of Polycaprolactone in East Asian Structural Rhinoplasty: Questions and Answers
 Delayed Sudden Blindness From Unilateral Ophthalmic Artery Vasospasm Following Endoscopic Sinus Surgery?
 Fenestral Otosclerosis: A Subtle Lesion Easily Missed
 Inverted Ductal Papilloma of the Salivary Gland
 Doknet's World
 Elvira I. Colmenar, MD
 Ruben G. Henson, Jr., MD
 Marlon V. del Rosario, MD
 Oliverio O. Segura, MD

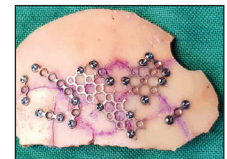COVER IMAGES



"Maxillary Fibrous Dysplasia in a 7-year-old"
iPhone 11 Pro Max
By Ricardo L. Ramirez Jr., MD




"COVID Surgery"
iPhone 11 Pro Max
By Ricardo L. Ramirez Jr., MD



"Make complex things simple then celebrate"
Samsung Galaxy Note 10
By Adrian F. Fernando, MD



"Watching and listening to singing birds, remind me what a blessing it is to be alive"
Fujifilm XE2s 250mm
By Adrian F. Fernando, MD



"The Hopeful Masked Lady"
10x14 watercolor and pen
By T. Teresa Paz G. Pascual, MD