



**EDITORIAL**

- 4 The Physician's Pledge: Promises at Dawn, Passages in Darkness  
Lapeña JF

**COMMENTARY**

- 6 On Shoulders of Giants: A Message from an Elder Fellow to New Diplomates  
Llamanzares TP

**REVIEW ARTICLE**

- 8 The Effectiveness of Intravenous Tranexamic Acid on Blood Loss and Surgical Time During Endoscopic Sinus Surgery: A Systematic Review  
Ligon JME, Almazan NA

**ORIGINAL ARTICLES**

- 13 Pneumococcal Conjugate Vaccine (Non-Typeable *Haemophilus influenzae* (NTHi) Protein D, Diphtheria or Tetanus Toxoid Conjugates) in Prevention of Acute Otitis Media in Children: A Cohort Study  
Chu TG, Cachola DRR III, Regal MAS, Llamas ACG, Martinez NV, Santos WR
- 16 Association of the Laterality of Chronic Suppurative Otitis Media and Sinonasal Disease Based on Temporal Bone CT Scans and Lund Mackay Scoring System  
Adan WC, Cruz, ETS
- 20 Adult Acute Epiglottitis: An Eight - Year Experience in a Philippine Tertiary Government Hospital  
Cruz MGY, Almazan NA
- 24 Accuracy of Fine Needle Aspiration Biopsy in Diagnosing Parotid Gland Malignancy  
Santiago KJB, Roldan RA, Castañeda SS
- 27 Motorcycle Related Cranio-Maxillofacial Injuries at a Tertiary Hospital in the Philippines  
De La Cruz RAR, Tuazon RS

**CASE REPORTS**

- 31 Granulation Tissue Mimicking a Glomus Tumor in a Patient with Chronic Middle Ear Infection  
Ong KMC, Labra PJP, Ricalde RR, Manasan CVC, Carnate JM
- 36 Rhinofacial Conidiobolomycosis in a 16-Year-Old Girl  
Parilla XVC, Cachuela JE
- 41 Relapsing Polychondritis Initially Presenting with Hoarseness and Difficulty Breathing in a 21-Year-Old Male  
Padua PF, Lim WL
- 47 A 15-Year Occult Foreign Body in the Subglottic Area of a 50-Year-Old Woman  
Segocio DJL, Dayanghirang CD, Cachuela JE

**SURGICAL INNOVATIONS AND INSTRUMENTATION**

- 51 True Congenital Macroglossia Surgically Managed Using a Modified Kole Technique  
Smith JC, Vicente GM
- 54 Medialization Thyroplasty Using a Pocket and Silicone Implant Technique  
Taningco MMF, Ibay EL

**FEATURED GRAND ROUNDS**

- 58 Meningioma in the Middle Ear: An Unusual Case of Hearing Loss  
Lim DMD, Yang NW

**FROM THE VIEWBOX**

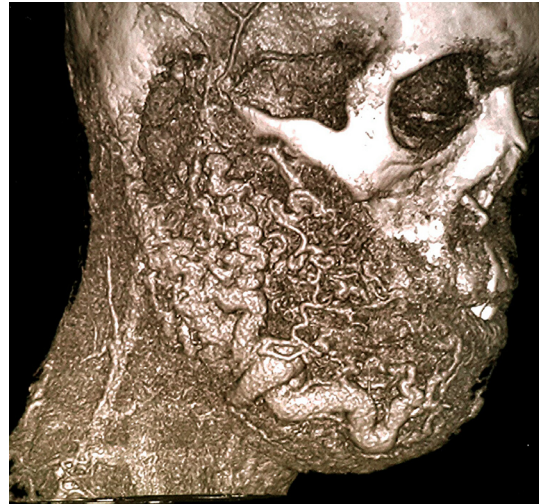
- 63 Spontaneous Middle Fossa Encephalocele  
Yang NW

**UNDER THE MICROSCOPE**

- 65 Low-Grade Cribriform Cystadenocarcinoma of the Parotid Gland  
Carnate JM

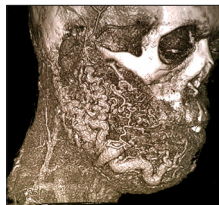
**PASSAGES**

- 67 Thierry F. Garcia, MD (1919-2016): The Most Good for the Most People  
Chiong CM
- 68 Sarah D. Moral-Ramos, MD (1979-2016): An Old Soul, Gone Too Soon  
Ong EAV

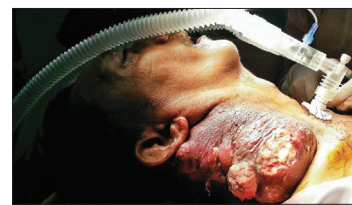


The Physician's Pledge: Promises at Dawn, Passages in Darkness  
 On Shoulders of Giants: A Message from an Elder Fellow to New Diplomates  
 The Effectiveness of Intravenous Tranexamic Acid on Blood Loss and Surgical Time During Endoscopic Sinus Surgery: A Systematic Review  
 Pneumococcal Conjugate Vaccine (Non-Typeable *Haemophilus influenzae* (NTHi) Protein D, Diphtheria or Tetanus Toxoid Conjugates) in Prevention of Acute Otitis Media in Children: A Cohort Study  
 Association of the Laterality of Chronic Suppurative Otitis Media and Sinonasal Disease Based on Temporal Bone CT Scans and Lund Mackay Scoring System  
 Adult Acute Epiglottitis: An Eight - Year Experience in a Philippine Tertiary Government Hospital  
 Accuracy of Fine Needle Aspiration Biopsy in Diagnosing Parotid Gland Malignancy  
 Motorcycle Related Cranio-Maxillofacial Injuries at a Tertiary Hospital in the Philippines  
 Granulation Tissue Mimicking a Glomus Tumor in a Patient with Chronic Middle Ear Infection  
 Rhinofacial Conidiobolomycosis in a 16-Year-Old Girl  
 Relapsing Polychondritis Initially Presenting with Hoarseness and Difficulty Breathing in a 21-Year-Old Male  
 A 15-Year Occult Foreign Body in the Subglottic Area of a 50-Year-Old Woman  
 True Congenital Macroglossia Surgically Managed Using a Modified Kole Technique  
 Medialization Thyroplasty Using a Pocket and Silicone Implant Technique  
 Meningioma in the Middle Ear: An Unusual Case of Hearing Loss  
 Spontaneous Middle Fossa Encephalocele  
 Low-Grade Cribriform Cystadenocarcinoma of the Parotid Gland  
 Thierry F. Garcia, MD (1919-2016): The Most Good for the Most People  
 Sarah D. Moral-Ramos, MD (1979-2016): An Old Soul, Gone Too Soon

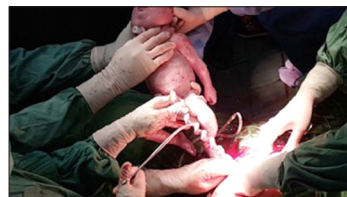**COVER IMAGES**



"Huuuuge Craniofacial AV Malformation"  
By Adrian F. Fernando, MD



"Air by-pass"  
By Rene Louie C. Gutierrez, MD



"Helping Hands: Ex Utero Intrapartum Treatment to Airway"  
By Daryl Anne A. del Mundo, MD



"Fruits and Orange Juice"  
33"x43" Acrylic on Hardboard  
By Mariano B. Caparas, MD