



EDITORIAL

- 4 Peer Review and the PJOHNS: Principles, Problems and Promise
Lapeña JF

ORIGINAL ARTICLES

- 6 Endoscopic Sinus Surgery Perioperative Outcomes after Intravenous Tranexamic Acid: A Double Blind Randomized Controlled Trial
Quiroga JMC, Jarin PSR
- 12 Posterior Nasal Neurectomy in Treatment of Intractable Rhinitis: A Preliminary Series
Vo MC, Pham HK, Nguyen MH
- 17 Reliability and Validity of the Filipino Sino-Nasal Outcome Test (SNOT) 22
Maningding CAC, Roldan RA
- 21 Evaluation of the Newborn Hearing Screening Program in The Medical City Based on Joint Commission on Infant Hearing (JCIH) 2007 Position Statement Quality Indicators
Que MHB, Reyes-Quintos MRT
- 25 Operative Time and Tympanic Membrane Graft Uptake in Endoscopic Transcanal versus Microscopic Post-Auricular Tympanoplasty for Chronic Otitis Media
Escalderon JRDJ, Lim WL
- 30 Histopathologically Positive Regional Neck Node Metastasis Among Patients with Laryngeal Squamous Cell Carcinoma
Soliman EGL, Pontejas AQY

CASE REPORTS

- 34 Inverted Papilloma of the Middle Ear Presenting as an Aural Polyp
Caro DJC
- 39 Extranasopharyngeal Angiofibroma: A Diagnostic Dilemma
Gupta N, Dass A, Saini V, Pol SA, Mittal L
- 43 Multiple Myeloma Presenting as a Parotid Mass
Borbe BB, Castañeda SS
- 47 Double Ectopic Thyroid Gland in a 10-Year-Old Filipino Boy
Mendez TJC, Navarro – Locsin CG

FEATURED GRAND ROUNDS

- 51 Bilateral Cricoaerytenoid Joint Ankylosis with a Perplexing Etiology
Sagun JRM, Cruz ETS

FROM THE VIEWBOX

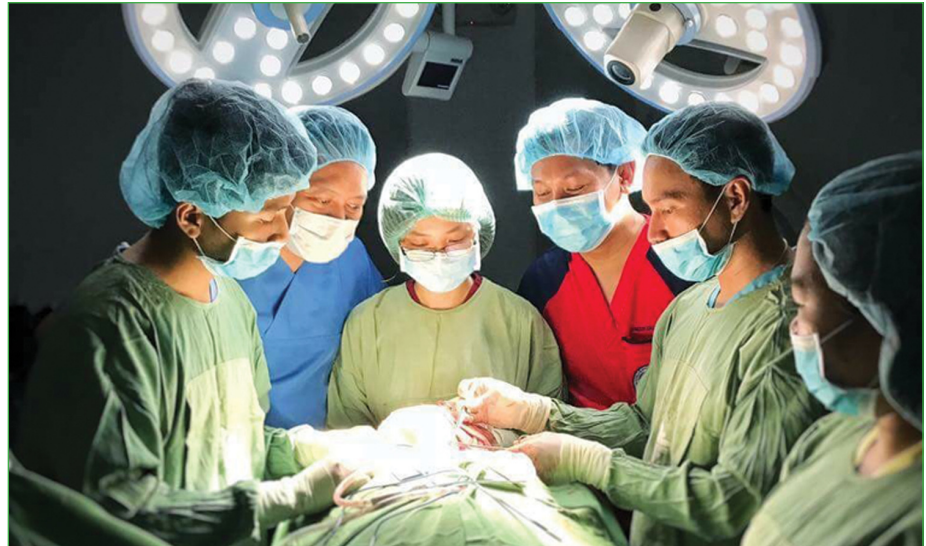- 56 Post-Operative Temporal Lobe Encephalocele
Bickle IC, Salim F

UNDER THE MICROSCOPE

- 58 Ameloblastic Fibrosarcoma of the Mandible
Go JT, Carnate JM

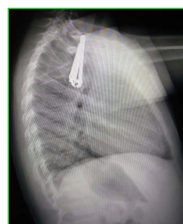PASSAGES

- 61 Mariano B. Caparas, MD (1932-2017)
Pontejas AQY

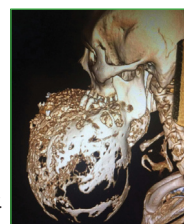


- Peer Review and the PJOHNS: Principles, Problems and Promise
- Endoscopic Sinus Surgery Perioperative Outcomes after Intravenous Tranexamic Acid: A Double Blind Randomized Controlled Trial
- Posterior Nasal Neurectomy in Treatment of Intractable Rhinitis: A Preliminary Series
- Reliability and Validity of the Filipino Sino-Nasal Outcome Test (SNOT) 22
- Evaluation of the Newborn Hearing Screening Program in The Medical City Based on Joint Commission on Infant Hearing (JCIH) 2007 Position Statement Quality Indicators
- Operative Time and Tympanic Membrane Graft Uptake in Endoscopic Transcanal versus Microscopic Post-Auricular Tympanoplasty for Chronic Otitis Media
- Histopathologically Positive Regional Neck Node Metastasis Among Patients with Laryngeal Squamous Cell Carcinoma
- Inverted Papilloma of the Middle Ear Presenting as an Aural Polyp
- Extranasopharyngeal Angiofibroma: A Diagnostic Dilemma
- Multiple Myeloma Presenting as a Parotid Mass
- Double Ectopic Thyroid Gland in a 10-Year-Old Filipino Boy
- Bilateral Cricoaerytenoid Joint Ankylosis with a Perplexing Etiology
- Post-Operative Temporal Lobe Encephalocele
- Ameloblastic Fibrosarcoma of the Mandible
Mariano B. Caparas, MD (1932-2017)


COVER IMAGES



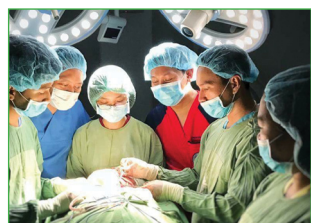"Kids Swallow the Darndest Things"
By Michael Joseph C. David, MD




"Head-sized ameloblastoma"
By Michael Joseph C. David, MD



"Fetus"
16.5" x 11.5", Poster Paint on Recycled Carton
By Hypte Raymund V. Aujero, MD



"Surhano"
Canon 5D Mark II 17-40
By Rene Louie C. Gutierrez, MD



"Campomanes Bay, Negros Occidental"
Fujifilm X-T1, 18mm f/3.6 iso800
By Michael Joseph C. David, MD