

Eduardo C. Yap, MD<sup>1,2</sup>

<sup>1</sup>Belo Medical Group

<sup>2</sup>Department of ENT

Metropolitan Medical Center

## Techniques in the Safe Use of Polycaprolactone in Structural Rhinoplasty

**Structural Rhinoplasty** is a term used by rhinoplastic surgeons wherein the existing structures are reconstructed and strengthened for functional and aesthetic improvement of the nose. The function refers mainly to breathing by correcting septal deviation and enlarging the internal valves.<sup>1</sup>

The usual surgical method is open rhinoplasty approach and all anatomical structures are analyzed. The central septal cartilage is removed while the remaining dorsal and caudal strut are reconstructed for better breathing and tip support.<sup>2</sup> The general concept is to alter the length and height of the existing dorsal and caudal strut by restructuring with the use of the central harvested cartilage. Cartilages used for strengthening the struts are called structural grafts while cartilages used for tip reshaping and projection are called contour grafts.<sup>3</sup>

Structural grafts commonly include the columellar strut graft, septal extension graft (SEG), spreader graft or extended spreader graft (ESG).<sup>1</sup> The columellar strut and SEG are used for lower cartilage and tip support. The spreader graft is used for strengthening the dorsal strut and enlarging the internal valve. The ESG is a spreader graft that is extended beyond the anterior angle of the septum for support of lower cartilage and tip. Among the structural grafts for lower cartilage tip support it is the Septal Extension Graft (SEG) that gives the best longevity.<sup>4</sup> The SEG is either placed side-to-side to the caudal strut or end-to-end supported by bilateral extended spreader graft (ESG). (Figures 1 & 2) Sometimes, a combination of ESG with SEG is needed to correct weakness of the struts. (Figure 3) Contour grafts are usually the dorsal graft and tip grafts. (Figure 4)

Because Asian (specifically South East Asian) noses are usually small, the harvested septum is often small and soft.<sup>3,4</sup> Occasionally the septum may look strong but upon harvest the dorsal and caudal struts weaken. Additional cartilage grafts are usually needed either from the auricle or from the rib. Auricular cartilage is too soft as support graft while the rib cartilage is strong because of its resemblance to septum in its histology. Autologous rib rhinoplasty is not only tedious and invasive but also more expensive which most patients do not prefer. Because of the paucity of septum, there are many substitute commercial materials in the market which can simulate the strength of septal cartilage as support graft. These can be homologous processed human rib cartilage, or alloplastic non-absorbable porous polyethylene. These materials are prone to long term complications e.g. warping, fracture, infection, resorption and extrusion.<sup>5,6</sup> Scientists and bioengineers recently developed polycaprolactone (PCL) which is a new synthetic absorbable porous material. It is marketed as a better material because not only it gives support but it also serves as a scaffold for tissue regeneration.<sup>7-9</sup>

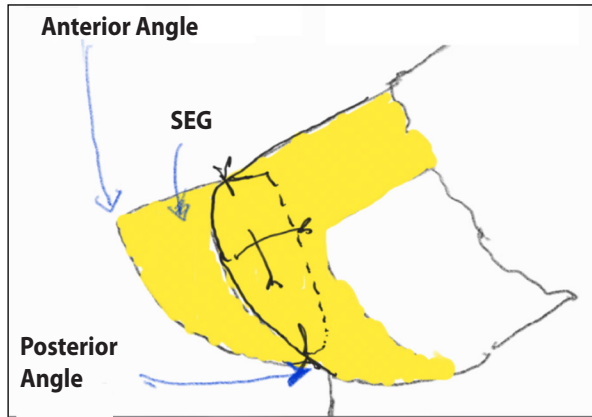
Correspondence: Dr. Eduardo C. Yap  
Unit 3, 28 Times St., West Triangle, Quezon City 1104  
Philippines  
Phone: (632) 8254 1111  
Email: edcyap88@gmail.com

The author declares that this represents original material that is not being considered for publication elsewhere in full or in part, in print or electronic media; that the manuscript has been read and approved by the author, that the requirements for authorship have been met by the author, and that the author believes that the manuscript represents honest work.

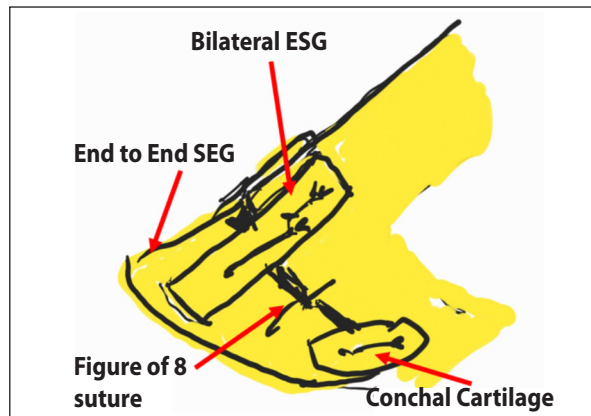
Disclosures: The author signed a disclosure that there are no financial or other (including personal) relationships, intellectual passion, political or religious beliefs, and institutional affiliations that might lead to a conflict of interest.



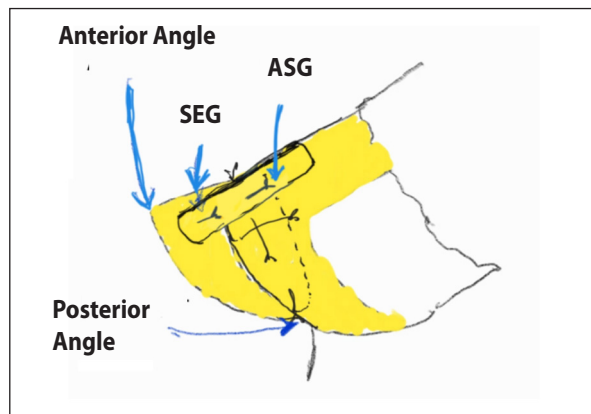
Creative Commons (CC BY-NC-ND 4.0)  
Attribution - NonCommercial - NoDerivatives 4.0 International



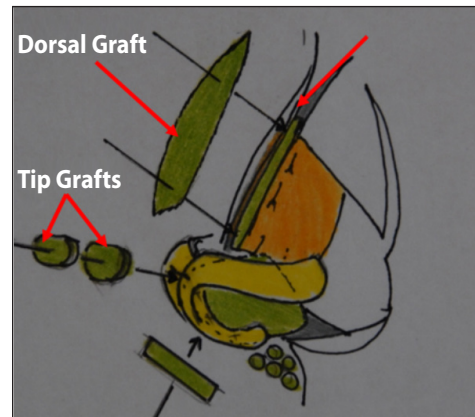
**Figure 1.** Schematic drawing of side-to-side Septal Extension Graft (SEG). Also depicted here is the modification done to produce a new anterior angle of the septum for tip support and projection. The posterior angle of the septum is maintained.




**Figure 2.** Schematic drawing of end-to-end SEG supported by bilateral extended spreader grafts (ESG), a figure-of-8 suture in the middle and conchal cartilage at the posterior angle of septum.



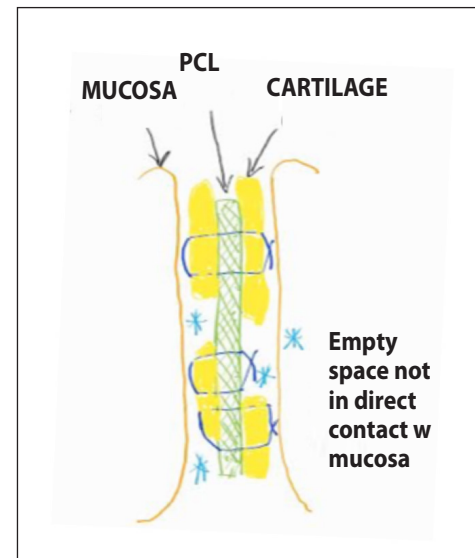
**Figure 3.** Schematic drawing of side-to-side SEG on the right and ESG on the left of the dorsal strut.



**Figure 4.** Schematic drawing of contour grafts namely dorsal graft for augmentation and tip grafts for projection.



**Figure 5.** Polycaprolactone (PCL) mesh use in septoplasty and rhinoplasty. Shown here is the more common 10 mm x 40 mm x 1 mm mesh.



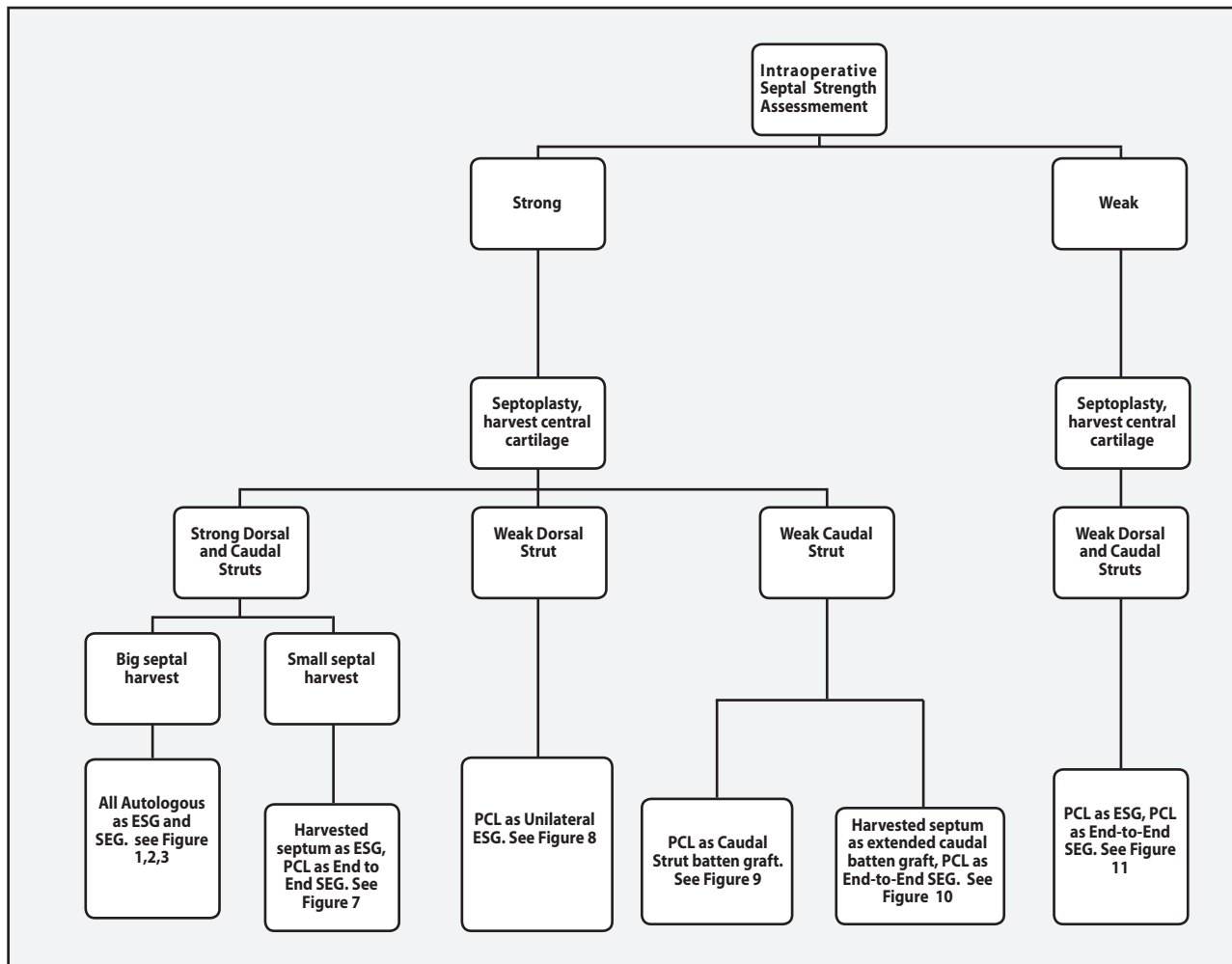
**Figure 6.** Schematic drawing of PCL inside membranous septum. Seen here is the coverage of PCL with cartilages held by PDS 5-0 sutures. Because of the elevated mucosa after covering with cartilages, the mucosa does not come in direct contact with PCL and erosion is minimized. Avoid quilting transmucosal suturing to avoid points of entry for infection.

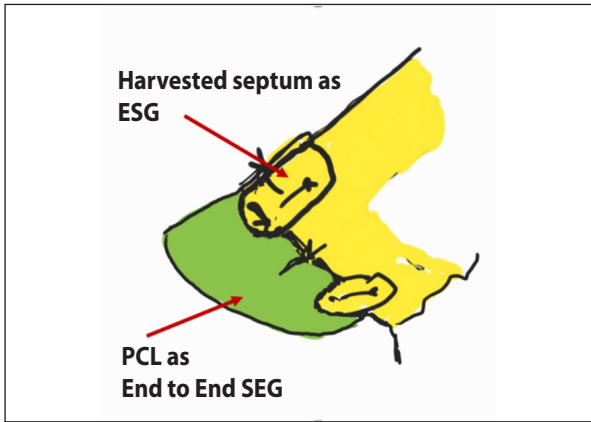
Polycaprolactone (PCL) is an absorbable material used in cranio-maxillofacial surgery as a scaffold for defects.<sup>10</sup> It is absorbed completely in 2 years. It is also a material used as threads in facial rejuvenation.<sup>11-13</sup> Recently PCL has been fashioned into mesh for use in septoplasty and rhinoplasty as implants and support.<sup>14,15</sup> Its use is mainly as a scaffold for tissue regeneration and support. It has been shown in studies that osteoblasts, chondroblasts and mesenchymal tissues grow into its pores.<sup>10,15</sup> It comes in various shapes and sizes. The ideal ones for use in nasal surgery are the 10 mm x 30-40 mm mesh plate with thickness variety of 0.8-1.2 mm. (Figure 5)

Polycaprolactone is not used routinely; it is still best to use all autologous tissues. The indication of the use of PCL depends on the structure of the nose (mainly the septum). It is best for use in cases of small septum with inadequate septal material for correction of deviation. It is also best for use in cases of weak septum or weak dorsal/

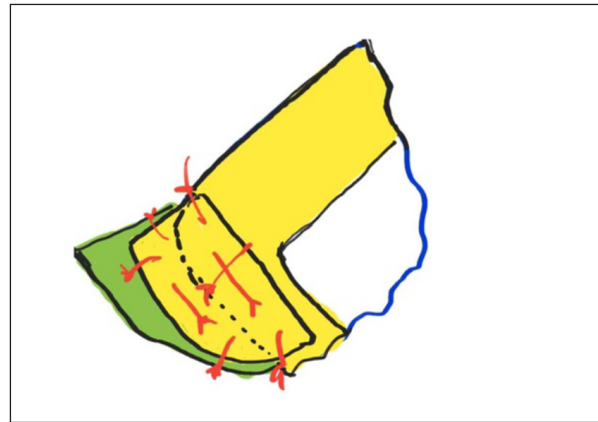
caudal struts after septal harvest to correct any possibility of collapse. Moreover, PCL is not advisable in severe contracted nose because forces of healing may lead to wound dehiscence, extrusion and infection. Extrusion and infection may also happen while PCL is still not completely absorbed in 2 years.

Since PCL is noted to lose its strength but provide well as a template for tissue regeneration, it is recommended to cover the PCL with septal or conchal cartilages whenever possible for 2 reasons: firstly, for protection against mucosal erosion and secondly as cartilage regeneration template for future support. (Figure 6). The decision to use PCL is made intraoperatively. The PCL mesh is fashioned into either an end-to-end SEG or ESG; both techniques of grafting are covered majority with cartilages. Following is the algorithm showing the indications when to use PCL after open rhinoplasty approach and assessment of the strength of the septum:

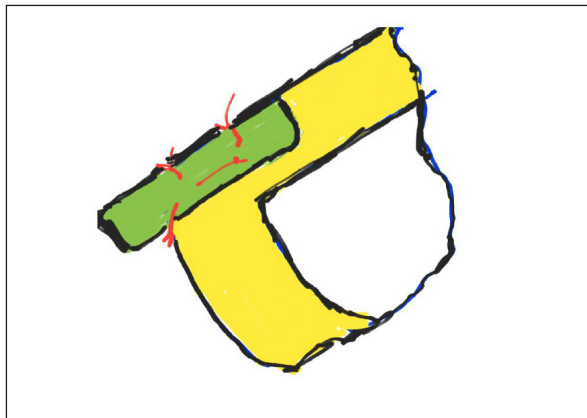




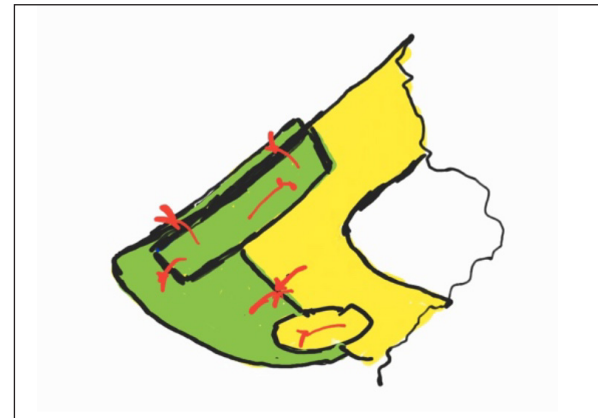**Figure 7.** For strong dorsal and caudal struts with small septum harvest, harvested septum is used as extended spreader graft while PCL is used as end-to-end SEG. The PCL has to be covered with conchal cartilages.



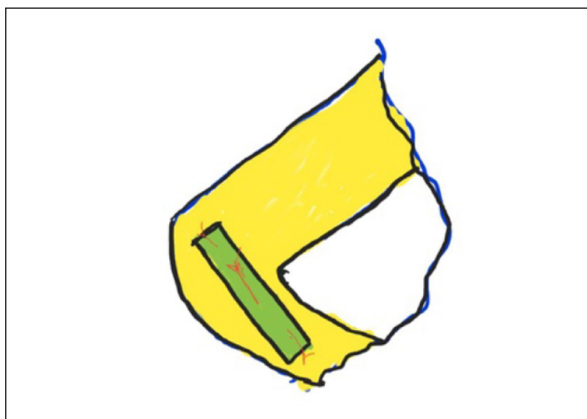
**Figure 10.** In cases of strong dorsal strut with a weak caudal strut the remaining septum can be used as extended caudal batten graft while the PCL is used as end-to-end SEG. The PCL has to be covered with conchal cartilages.



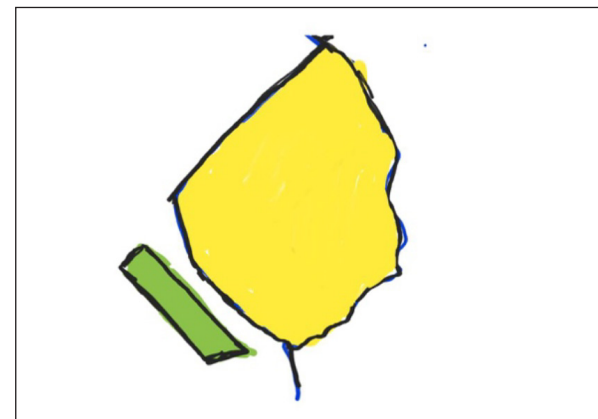
**Figure 8.** Unilateral PCL as ESG in cases of weak dorsal strut. PCL size is approx. 5 mm (w) x 1.5-2.0 mm (length). The PCL has to be covered with a thin cartilage for protection especially in the membranous septum area.



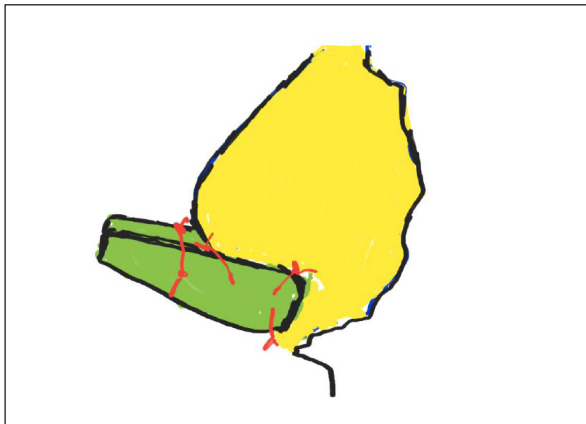
**Figure 11.** PCL is almost used entirely for the new dorsal and caudal strut. The ESG can be unilateral or bilateral. The end-to-end SEG mainly depends on the strength of the ESG. The entire PCL should be covered with remaining harvested septal cartilages supplemented with conchal cartilages for protection, cartilage tissue in growth and future support. This technique may obviate the need of extracorporeal septoplasty; it may be applicable to severely deviated superior and caudal septum.



**Figure 9.** PCL is used as a batten graft for weak or deviated caudal strut. The PCL size varies depending on deformity and has to be covered with cartilage for protection.



**Figure 12.** PCL as a floating columellar strut. Although the PCL is between the medial crura, it is still recommended to cover it with conchal cartilage.



**Figure 13.** Columellar strut (2 pieces of thin PCL mesh) fixed at posterior septum. This functions very similarly to SEG however it may be unstable. The PCL should be covered with conchal cartilages all the way from the tip to the posterior septum area to prevent erosion of mucosa.

There are times wherein minimal surgery is needed for tip projection. Since Asian noses have weak medial crura with heavy skin and soft tissue envelope, PCL can be used just as a columellar strut - either floating or fixed to the posterior caudal septum. Fixing to the posterior caudal septum functions similar to a SEG too. However, these techniques may be unstable. (Figures 12 & 13)

Polycaprolactone was commercially available locally in the latter part of 2018. From August 2018 to March 2020, I used PCL in 213 (40.7%) out of 523 cases of septoplasty for structural rhinoplasty for various indications. All outcomes were followed up through calls and/or texts and all results were good with all patients satisfied with their results as of this writing, except for two. One patient developed post-operative deviation of the SEG after a week; the etiology was due to the improper choice of PCL strength. Revision surgery was done with replacement by a thicker PCL. Another patient developed infection after 4 months. Revision surgery involved removal of PCL and placement of columellar strut for support. This initial experience with the use of PCL is promising but it is too early to conclude. Long term follow-up should be done to see changes in structure when the PCL is totally absorbed.

In summary, PCL is a strong absorbable tissue template mesh in septoplasty and rhinoplasty. It is gradually absorbed within 2 yrs. While it is in its early stage as a mesh graft, it gives strength. However, as it is slowly absorbed, it imbibes the surrounding tissue cells for regeneration for future strength. It is highly recommended to cover the PCL with cartilages to prevent erosion to surrounding mucosa. Aside from protection of the PCL against erosion and extrusion, the cartilage also gives the future strength as chondrocytes grow into the PCL mesh.

REFERENCES

1. Toriumi DM. Structural approach to primary rhinoplasty. *Aesthet Surg J*. 2002 Jan; 2(1): 72-84. DOI: 10.1067/maj.2002.122071; PMID: 19331957.
2. Whitaker EG, Johnson CM Jr. The evolution of open structure rhinoplasty. *Arch Facial Plast Surg*. 2003 Jul-Aug; 5(4):291-300. DOI: 10.1001/archfaci.5.4.291; PMID: 12873866.
3. Yap EC. Principles of Structural Rhinoplasty in South East Asian Noses. *Phillip J Otolaryngol Head Neck Surg*. 2014 Jul-Dec; 29(2): 41-44. DOI: <https://doi.org/10.32412/pjohns.v29i2.437>.
4. Won TB, Jin JR, Lee HJ. Nasal tip surgery in Asians. *Otolaryngology-Head and Neck Surgery*. 2008 May; 102.
5. Wee JH, Mun SJ, Na WS, Kim H, Park JH, Kim DK, et al. Autologous vs irradiated homologous costal cartilage as graft material in rhinoplasty. *JAMA Facial Plast Surg*. 2017 May 1;19(3):183-188. DOI: 10.1001/jamafacial.2016.1776; PMID: 28334327 PMID: PMC5540002.
6. Winkler AA, Soler ZM, Leong PL, Murphy A, Wang TD, Cook TA. Complications associated with alloplastic implants in rhinoplasty. *Arch Facial Plast Surg*. 2012 Nov; 14(6):437-441. DOI: 10.1001/archfacial.2012.583; PMID: 22928175.
7. Siddiqui N, Asawa S, Birru B, Baadhe R, Rao S. PCL-based composite scaffold matrices for tissue engineering applications. *Mol Biotechnol*. 2018 Jul; 60 (7): 506-532. DOI: 10.1007/s12033-018-0084-5; PMID: 29761314.
8. Malikmammadov E, Tanir TE, Kiziltay A, Hasirci V, Hasirci N. PCL and PCL-based materials in biomedical applications. *J Biomater Sci Polym Ed*. 2018 May-Jun; 29(7-9): 863-893. DOI: 10.1080/09205063.2017.1394711; PMID: 29053081.
9. Patricio T, Gloria A, Bartolo P. Mechanical and Biological behavior of PCL and PCL/PLA scaffolds for tissue engineering applications. *Chemical engineering transactions*. 2013 Jun 20; 32: 1645-1650. DOI: 10.3303/CET1332275.
10. Gaviria L, Pearson JJ, Montelongo SA, Guda T, Ong JL. Three-dimensional printing for craniomaxillofacial regeneration. *J Korean Assoc Oral Maxillofac Surg*. 2017 Oct; 43 (5): 288-298. DOI: 10.5125/jkaoms.2017.43.5.288; PMID: 29142862 PMID: PMC5685857.
11. Lin SL. Polycaprolactone facial volume restoration of a 46-year-old Asian women: a case report. *J Cosmetic Dermatol*. 2018 Jun; 17(3):328-332. DOI: 10.1111/jocd.12482; PMID: 29314648.
12. Rezaee Khiabanloo S, Jebreili R, Aalipour E, Eftekhari H, Saljoughi, Shahidi A. Innovative techniques for thread lifting of face and neck. *J Cosmet Dermatol*. 2019 May 3. DOI: 10.1111/jocd.12969; PMID: 31050152.
13. de Melo F, Marijnissen-Hofste J. Investigation of physical properties of a polycaprolactone dermal filler when mixed with lidocaine and lidocaine/epinephrine. *Dermatol Ther (Heidelv)*. 2012 Dec; 2(1):13. DOI: 10.1007/s13555-012-0013-7; PMID: 23205335 PMID: PMC3510390.
14. Kim DH, Yun WS, Shim JH, Park KH, Choi D, Park MI, et al. Clinical application of 3-Dimensional Printing technology for patients with nasal septal deformities: a multicenter study. *JAMA Otolaryngol Head Neck Surg*. 2018 Dec 1; 144 (12): 1145-1152. DOI: 10.1001/jamaoto.2018.2054; PMID: 30326042 PMID: PMC6583092.
15. Park YJ, Cha JH, Bang SI, Kim SY. Clinical Application of Three-Dimensional Printed Biomaterial Polycaprolactone (PCL) in Augmentation Rhinoplasty. *Aesthetic Plast Surg*. 2019 Apr; 43(2): 437-446. DOI: 10.1007/s00266-018-1280-1; PMID: 30498936.