

# Role of Topical Cyclosporine in Prevention of Pterygium Recurrence, after Primary Excision

Munawar Ahmed, Atif Mansoor, Noman Ahmed, Ghazi Khan Mari, Azfer Ahmed Mirza

*Pak J Ophthalmol 2019, Vol. 35, No. 3*

.....  
See end of article for  
authors affiliations  
.....

Correspondence to:  
Munawar Ahmed  
Associate professor,  
Institute of ophthalmology  
Liaquat University of Medical &  
Health Sciences Jamshoro  
**E-mail:**  
munawar\_404@yahoo.com

**Purpose:** To study the effect of cyclosporine on pterygium recurrence after primary excision

**Study Design:** Non randomized controlled trial.

**Place and Duration of Study:** The study was conducted in the department of Ophthalmology, Liaquat University of Medical and Health Sciences, Jamshoro from 2015 to 2017.

**Material and Methods:** One hundred and thirty eyes of 65 patients having bilateral pterygium, at least 2 mm encroaching on the cornea, were selected for study. Dimensions of pterygium were measured on slit lamp. Half of the eyes were selected for post-operative cyclosporine and was named as cyclo- eye and fellow other eye was named as non-cyclo eye. Immediate post-operative treatment was tobramycin dexamethasone eye ointment twice and moxifloxacin eye drops three times daily until corneal epithelium was restored, followed by moxifloxacin and Cyclosporine eye drops twice daily until complete healing of ocular surface occurred and then cyclosporine 0.05% alone once daily in the evening up to three months. In the fellow eye tobramycin dexamethasone eye ointment and moxifloxacin eye drops were used for complete healing time followed by tears alone three times for three months. Follow up was done for six months.

**Results:** Only Fifty-three patients who completed 6 months of follow-up were included in the results. In cyclo-eyes recurrent pterygium was observed only in 4 (07.55%) and in non-cyclo eyes recurrence was observed in 23 (43.40%) eyes. Mean healing time in cyclo-eyes was 21.1354 days and in non-cyclo-eyes, 15.0213 days.

**Conclusion:** Cyclosporine is effective in reducing the recurrence rate of pterygium.

**Key Words:** Pterygium, Cyclosporine, Cornea.

.....  
**P**terygium is a fibrovascular growth of conjunctiva over cornea at 3 and 9 o' clocks. It occurs most commonly in hot, dry and dusty atmosphere, which makes ocular surface dry, inviting the conjunctival blood vessels to reach the cornea. As cornea is avascular structure, it cannot maintain its integrity without sufficient tears for the outdoor workers in hot and dry atmosphere. The degenerative

changes in pterygium formation is accompanied by cellular proliferation and vascularization of corneal surface. Secretion of pro-inflammatory substances such as interleukin-1 and tumor necrosis factor- $\alpha$  secondary to long time ultraviolet (UV) radiation, is a main known factor in the formation of pterygium<sup>1,2</sup>. The vascular endothelial growth factor (VEGF), also increases in pterygium epithelium which is stimulated

by TNF- $\alpha$  through UVB radiation<sup>3,4</sup>. Ultraviolet induced inflammation and release of cytokines stimulates proliferation of Tenon's capsule fibroblasts to produce fibrovascular tissue of pterygium<sup>5</sup>.

If pterygium is left untreated it involves visual axis and leads to loss of vision. Many procedures are done to treat this problem for example, simple excision, use of conjunctival autograph and amniotic membrane. As a medical treatment, interferon, MMC, and anti VEGF are also used but they are expensive and may have complications and they do not have additional benefit of treating the dry eyes. So, we conducted study on cyclosporine-A which is already being used to treat dry eyes and safe even for long term use<sup>6</sup>.

Cyclosporine is an immune modulating substance. It is derived from the fungus *Typhlocyba inflatum* and approved by world health organization as a safe medicine. It decreases the production of inflammatory cytokines by T-lymphocytes. It has also been used topically to reduce sub-epithelial infiltrates in epidemic keratoconjunctivitis<sup>6</sup>. Systemic use can increase the risk of lymphoma.

Cyclosporine-A shows a selective effect against T-helper cells and prevents the synthesis and secretion of ILs. Cs-A also blocks angiogenic effect induced by VEGF. Therefore, we have evaluated the effects on pterygium recurrences. The aim of this study was to investigate the outcome of topical Cs-A in prevention of pterygium recurrence after simple excision.

## MATERIAL AND METHODS

A comparative study on 130 eyes of 65 patients having bilateral pterygium, encroaching on the cornea at least 2 mm, was done using convenient sampling. The study was conducted in the department of Ophthalmology, Liaquat University of Medical and Health Sciences, Jamshoro from 2015 to 2017. The patients with pseudo-ptyerygium and other causes of corneal vascularization were excluded from study. After informed consent and explanation of research procedure, patients were seen on slit lamp, the extent of pterygium was assessed. Half of the eyes with pterygium were selected for post-operative cyclosporine and were named as cyclo-eyes and half fellow eyes were selected for simple excision done by the same surgeon after an interval of one to two week and were named as non-cyclo eyes. Immediate post-operative treatment was tobramycin dexamethasone eye ointment twice and moxifloxacin eye drops three

times daily until corneal epithelium was restored, followed by moxifloxacin and Cyclosporine 0.05% eye drops twice daily until complete healing of ocular surface. Then moxifloxacin was stopped and only cyclosporine 0.05% eye drops once daily in the evening were continued upto three months. In the fellow eye only tobramycin dexamethasone eye ointment and moxifloxacin eye drops were used for complete healing time followed by tears three times daily up to three months. Follow up was done after one week, one month, three months and six months. one mm growth of conjunctival blood vessels on the cornea was considered as recurrence. The results of cyclo-eyes were compiled and compared with the fellow eyes and processed on SPSS to see the significance.

The results were evaluated by SPSS 2014. The variables used were healing time and pterygium recurrence period in days. Quantitative data were evaluated by independent samples T-test, paired T-test, and Chi-square test.

## RESULTS

Fifty-three out of 65 patients who completed 6 months follow up were included in the final results. In cyclo-eyes recurrent pterygium was observed in 04 (07.55%) patients and recurrence in fellow non-cyclo eyes occurred in 23 (43.40%) patients (Table 1).

**Table 1:** Bio data of patients having bilateral pterygium (n=53 each group).

Total No: of eyes	106	(100.0%)
Male	31	(58.49%)
Female	22	(41.51%)
Average age		51.00 years
Cyclo-eyes	53	(50.00%)
Non cyclo-eyes	53	(50.00%)
Extent of pterygium	2 mm to 4 mm	

**Table 2:** Comparisons of results after 6 months follow up (n=53 each group).

Groups	Cyclo-eyes	Non-Cyclo-eyes
No: of eyes	53 (50.00%)	53 (50.00%)
Recurrence	04 (07.55%)	23 (43.40%)
Mean healing time	21.1354 days	15.0213 days
Standard deviation	1.3412	1.0413
P-value	0.002	0.004
Complications	None	None

Immediate post-operative use of cyclosporine interferes with healing process. It takes longer time for healing of corneo-scleral wound produced by pterygium excision. Mean healing time in cyclo-eyes was  $21.1354 \pm 1.3412$  days and in non-cyclo-eyes was  $15.0213 \pm 1.0413$  days. P-value was 0.002 and 0.004 respectively (table 2).

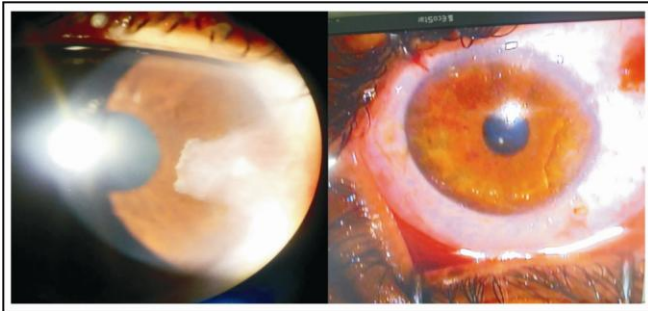


Fig. 1: Pterygium shown pre and postoperatively.

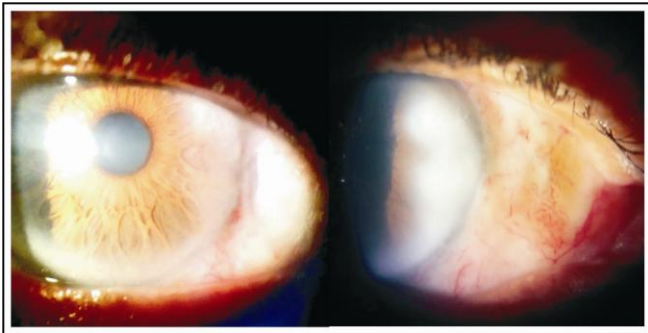


Fig. 2: Post op picture with Cyclosporin eye drops after 2 weeks and with no cyclosporine drops after 2 weeks.

## DISCUSSION

Pterygium is a growth disorder rather than degenerative condition, and mainly proliferative factors are investigated to find out etiology and pathogenesis. As sutures can increase the risk of recurrence therefore bare sclera suture-less technique was used in our patients. A definitive treatment without recurrence and minimal complications, has yet to be found. The main culprits for pterygium are UV radiation, dry and hot atmosphere, which, leads to release of inflammatory vascular growth factors and formation of pterygium. It varies in people living in the same environment. Hypersensitivity is also a powerful factor in the pathogenesis of pterygium<sup>7</sup>.

T-lymphocytes are elevated in the pterygium tissue. All available data shows the importance of T-lymphocyte-mediated strong cellular immunity in pterygium pathogenesis. Cs-A selectively suppresses functions of T-helper lymphocytes and production of both inflammatory cytokines and inflammatory mediators.

It also suppresses IgE production in a T-cell-dependent manner and inhibit histamine release from basophil and mast cells<sup>8</sup>.

In vivo and in vitro studies have showed that Cs-A inhibits angiogenesis triggered by VEGF. We believed that inhibiting all those paths with Cs-A, which are thought to have a role in pterygium pathogenesis, might be effective in preventing recurrence<sup>9</sup>. Cs-A 0.05% is effective in inhibiting the fibroblasts proliferation in Tenon's capsule<sup>10</sup>.

In another similar study, thiotepea and cyclosporine were compared following pterygium excision where Cs-A was found to be significantly more effective than thiotepea<sup>11</sup>.

In Turan-Vural study recurrence rate was 44.4% in simple bare sclera technique but 22.2% with 0.05% post-operative cyclosporine and no side effect except mild burning sensation. They also used fellow eye as control in patients having bilateral pterygium and reported recurrence in 12.9% with cyclosporine and 45.2% in simple bare sclera technique<sup>12,13</sup>.

In literature, recurrence of pterygium after simple excision exceeds 50%. In our study, we have used tears for three months which might have reduced the recurrence rate even in simple excision. Topical Cs-A plays a role in the inhibition of T lymphocyte proliferation and suppression of the inflammation of the ocular surface. It is reported in literature that topical Cs-A is effective in various concentrations in ocular inflammation cases such as vernal keratoconjunctivitis, ulcerative keratitis in rheumatoid arthritis, anterior uveitis, corneal graft rejection, superior limbic keratoconjunctivitis, graft versus host disease, mycotic keratitis, Cogan syndrome, Behçet's disease, herpetic stromal keratitis, Mooren ulcer, atopic keratoconjunctivitis and scleritis<sup>14</sup>. Topical 0.05% Cs-A relieves dryness of eyes in meibomian gland dysfunction without significant systemic or ocular side effects when compared to Bevacizumab and mitomycin-C<sup>15</sup>.

Treatment of patients with dry eye disease for 12 months with topical 0.05% Cs-A does not cause changes in the corneal endothelium.<sup>16</sup> According to

Duke-Elder, pterygium occurs frequently on the nasal side of conjunctiva. This can be explained on the basis of light, which is coming to the temporal cornea and focused on the nasal side. Pterygia on the temporal side are rare and should be differentiated from squamous cell tumor. Double-headed pterygium, is very rare, only 2.5%<sup>17</sup>.

In a retrospective study, it was seen that Pterygium recurrence rate was 5.3% with glue, versus 13.5% with sutures in conjunctival autograft<sup>18</sup>. Recurrence of 3.3% was reported with stem cell graft by another researcher<sup>19</sup>. Our recurrence rate was 06% in the Cyclosporine group, which was more than the recurrence observed by Aydin et al<sup>18</sup>. (3.4%), but lower than observed by Tok et al. (12.9%)<sup>17</sup>. It may be higher than observed by Aydin et al because of the study population of only vascularized and recurrent pterygium, which is more prone for higher recurrence compared to primary pterygium<sup>20</sup>.

## CONCLUSION

This short-term study has given promising results in reducing pterygium recurrence after primary excision. As pterygium is common in tear deficient eyes. It worsens with advancing age. Cyclosporine is effective in reducing the ocular surface dryness and pterygium recurrence. Neat and clean pterygium excision and post-operative topical use of cyclosporine is very safe and effective method to prevent recurrence of pterygium. Long term use of cyclosporine 0.05% eye drops twice daily is harmless to the ocular surface and intraocular structures. This is cheaper and safer method and should be adopted to reduce the risk of pterygium recurrence. Therefore, use of cyclosporine after primary excision is recommended.

## ACKNOWLEDGEMENT

I am thankful to my professor Sameen Afzal Junejo who always encouraged us for research projects.

## REFERENCES

1. Di Girolama N, Chui J, Coreneo MT, Wakefield D. Pathogenesis of pterygia: role of cytokines, growth factors, and matrix metalloproteinases. *Prog Retin Eye Res.* 2004; 23 (2): 195-289.
2. Girolama ND, Kumar RK, Cornea MT, Wakefield D. UVB. Mediated induction of interleukin-6 and 8 in pterygia and cultured human pterygium epithelial cells. *Inves Ophthalmol Vis Sci.* 2002; 143 (119): 3430-3437.
3. Coroneo MT, Girolamo N, Wakefield D. The pathogenesis of pterygia. *Curr Opin Ophthalmol.* 1999; 10: 282-288.
4. Chan CM, Liu YP, Tan DT. Ocular surface changes in pterygium. *Cornea.* 2002; 21: 38-42.
5. Turan-Vural E, Torun-Acar B, Kivanc SA, Acar S. The effect of topical 0.05% cyclosporine on recurrence following pterygium surgery. *Clin Ophthalmol.* 2011; 5: 881-885.
6. Okumus S, Coskun E, Tatar MG, Kaydu E, Yayuspayi R, Comez A et al. Cyclosporine a 0.05% eye drops for the treatment of subepithelial infiltrates after epidemic keratoconjunctivitis. *BMC Ophthalmol.* 2012; 18: 12: 42.
7. Nakamura M, Nishida T. Differential effects of epidermal growth factor and interleukin 6 on corneal epithelial cells and vascular endothelial cells. *Cornea,* 1999; 18 (4): 452-458.
8. Nussenblatt RB, Palestine AG. Cyclosporine: immunology, pharmacology and therapeutic uses. *Surv Ophthalmol.* 1986; 31: 159-169.
9. Okudaira H, Sakurai Y, Terada K, Terada E, Ogita T, Miyamoto T. Cyclosporin A-induced suppression of ongoing IgE antibody formation in the mouse. *Int Arch Allergy Appl Immunol.* 1986; 79 (2): 164-8. PubMed PMID: 3484729.
10. Hercules LA, Viveiros MM, Schellini SA, Cadeias J, Padovani CR. Exposure of Tenon's capsule fibroblasts of pterygium to cyclosporin 0.05% *Arg Bras Oftalmol.* 2006; (69): 831-834.
11. Wu H, Chen G. Cyclosporine A and thiotepa in prevention of postoperative recurrence of pterygium. *Yan Ke Xue Bao.* 1999; 15 (2): 91-92.
12. Turan-Vural E, Torun-Acar B, Kivanc SA, Acar S. The effect of topical 0.05% cyclosporine on recurrence following pterygium surgery. *Clin Ophthalmol.* 2011; 5: 881-885.
13. Hwang S, Choi S. A Comparative Study of Topical Mitomycin C, Cyclosporine, and Bevacizumab after Primary Pterygium Surgery. *Korean J Ophthalmol.* 2015; 29 (6): 375-81.
14. Irfan S, Iqbal H. Role of topical cyclosporine in scleritis; a case series. *Pak J Ophthalmol.* 2013; 29 (2): 68-72.
15. Pérez-Rico C, Germain F, Castro-Rebollo M, Moreno-Salgueiro A, Teus MÁ. Effect of topical 0.05% cyclosporine A on corneal endothelium in patients with dry eye disease. *Int J Ophthalmol.* 2013 Aug 18; 6 (4): 471-4.
16. Duman F, Köşker M. Demographics of Patients with Double-headed Pterygium and Surgical Outcomes. *Turk J Ophthalmol.* 2015 Dec; 45 (6): 249-253.
17. Tok O Y, Nurozler AB, Ergun G, Kocaoglu AF, Duman S. Topical cyclosporine A in the prevention of pterygium recurrence. *Ophthalmologica.* 2008; 222 (6): 391-6. Doi: 10.1159/000151740.
18. Aydin A, Karadayi K, Aykan U, Can G, Colakoglu K, Bilge AH. Effectiveness of topical cyclosporin A treatment after excision of primary pterygium and limbal conjunctival autograft. *J Fr Ophtalmol.* 2008 Sep;

- 31 (7): 699-704.
19. Zahid N, Qayyum I, Hanif A. Comparison of Recurrence after Pterygium Excision with Amniotic Membrane Graft Versus Stem Cell Graft Pak J Ophthalmol. 2018; 34 (1): 15-18.
20. Dhar SK, Kapoor G, Parihar JKS. Role of pre and postoperative topical cyclosporine (0.05%) on recurrent and vascularized pterygium. IOSR JDMS. 2017; 16 (1): 23-25.

**Author's Affiliation**

Munawar Ahmed  
Associate Professor Ophthalmology  
Liaquat University of Medical and Health Sciences  
Jamshoro

Dr. Noman Ahmed  
Assistant Professor  
Liaquat University of Medical and Health Sciences  
Jamshoro

Dr. Atif Mansoor Ahmed  
Associate Professor  
Shaikh Zayed PGMI & Medical complex Lahore

Dr. Ghazi khan Mari  
Assistant Professor  
Liaquat University of Medical and Health Sciences  
Jamshoro

Dr. Azfer Ahmed Mirza  
Assistant Professor  
Liaquat University of Medical and Health Sciences  
Jamshoro

**Author's Contribution**

Dr. Munawar Ahmed  
Study design, Data collection, Manuscript writing.

Dr. Noman Ahmed  
Data collections, manuscript writing.

Dr. Atif Mansoor Ahmed  
Shared his experience regarding topical use of cyclosporine.

Dr. Ghazi Khan Mari  
Surgical management, critical review of manuscript.

Dr. Azfer Ahmed Mirza  
Data collection, manuscript writing.