

Case Report

# Spontaneous Late Lens Subluxation Masquerading as Acute Angle Closure Glaucoma

Imran Akram

*Pak J Ophthalmol 2006, Vol. 22 No.2*

.....  
See end of article for  
authors affiliations

.....  
Correspondence to:  
Imran Akram  
Vitreoretinal Fellow  
Stoke Mandeville Hospital,  
Aylesbury  
Buckinghamshire HP21 8AL  
UK

Received for publication  
October' 2005  
.....

## CASE REPORT

A 45 year old lady was referred to the eye clinic in 1996 by her optician who had noticed a rapid increase in her myopia and was querying keratoconus. She had previously been emmetropic and wore only reading glasses. No signs of keratoconus were seen although it was noted that she had thick crystalline lenses. Intraocular pressures were normal. Pupils were not dilated for ocular examination. There was no iridodonesis. Refraction showed the right eye had a -2.00 cyl axis 7, while the left eye had a -4.50 cyl axis 90. Keratometry showed minimal astigmatism in either eye and thus the astigmatism was attributed to lenticular changes. With this correction she saw 6/6 in each eye.

5 months later she was re-referred by her GP complaining of misting over her right eye for a few

days and symptoms what she described as "migraine" around the right eye. Visual acuities were Rt 6/9 and Lt 6/6. Intraocular pressures were 30mmHg and 20mmHg right and left eye respectively. The right anterior chamber was significantly shallow. On gonioscopy the drainage angle was completely closed in the right eye and only partially open in the left eye. A diagnosis of sub-acute angle closure glaucoma was made and she was commenced on guttae Pilocarpine 1% qds to both eyes. She was booked for bilateral YAG laser iridotomy for the following week. However, before that she came in as an emergency with the right intraocular pressure elevated at 55mmHg. She was admitted and the raised IOP treated medically with intravenous acetazolamide and topical beta-blockers. This was followed by bilateral YAG iridotomy. Following this her intraocular pressures stabilized around the early 20's in the right eye and below

20mmHg in the left. Visual fields were full despite the right disc appearing to be more cupped than the left.

Over the next 4 years the right intraocular pressure gradually crept up to 27mmHg and in January 2001 she was commenced on guttae Latanaprost nocte to the right eye which brought the pressure down to the mid-teens. Subsequently the intraocular pressure remained well controlled in both eyes.

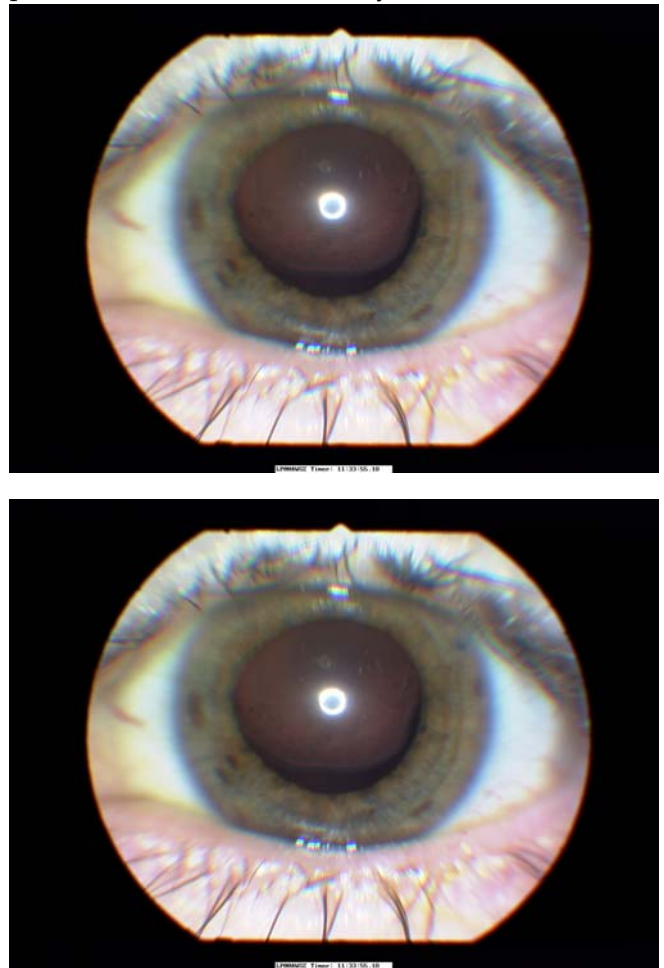
At her 6 monthly clinic review in March 2003 she complained of deterioration of vision in both eyes which her optician had correctly attributed to the development of cortical lens opacity in both eyes. In order to better visualize her lens opacity, her pupils were dilated for the first time. This revealed that both lenses were subluxated. The left was displaced superiorly and the right slightly nasally as well as superiorly (Fig 1). Her general health was fine and there was no family history of eye problems. She had no clinical features of Marfans or Weil Marchesani syndromes. Left cataract extraction was carried out three weeks later. The surgical technique involved superior clear corneal section and paracentesis followed by continuous curvilinear capsulorhexis. There was no zonular support so iris hooks were employed to lift up the capsular bag (Fig. 2). An uneventful divide and conquer type phacoemulsification was performed. A capsular tension ring was then introduced to support the capsular bag. This was followed by aspiration of soft lens matter and introduction of an Acrysof foldable IOL in the bag. The section was then hydrated. Unaided visual acuity on the first post operative day was 6/6. The fellow eye underwent a similar uneventful operation six weeks later. Corrected visual acuity was 6/6 in both eyes.

## DISCUSSION

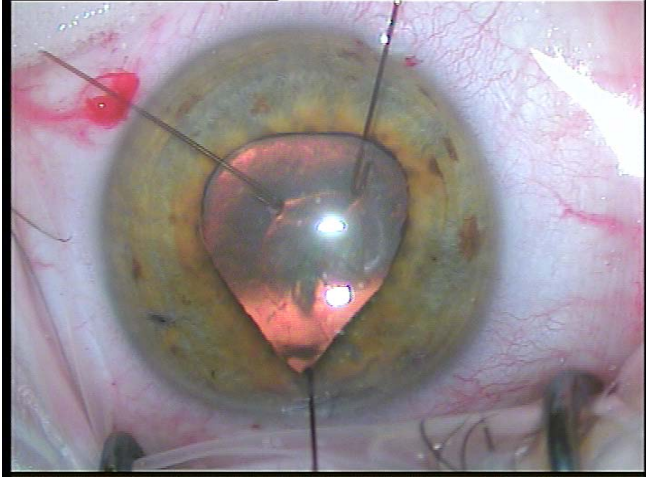
Spontaneous dislocation of the crystalline lens is a known feature of certain systemic conditions notably Marfans syndrome, Weil Marchesani syndrome and Homocysteinuria. The first two of these have well defined clinical features suggestive of the diagnosis. In the absence of any systemic condition however, spontaneously dislocated lens may present as progressive myopia, shallowing of anterior chamber and occasionally glaucoma<sup>1</sup>. Spontaneous dislocation of the lens occurring later in life may be an inherited condition, an observation first made by Vogt in 1905. Vogt and other subsequent workers have described several pedigrees throughout the 20th century. More

recently Malbran et al<sup>2</sup> described seven adult members of two families with dislocated lenses and labeled these as genetic spontaneous late subluxation of the lens (GSLSL). Hagan and Lederer<sup>3</sup> described three relatives who were myopic and apparently had primary angle closure glaucoma. They later reported the same patients again<sup>4</sup> revealing that the underlying pathology was infact lens subluxation and that these were also cases of GSLSL.

Our patient does not as yet have any family history of similar eye problems. Her mode of presentation however is very similar to cases of



**Fig. 1a & b:** Edge of subluxated crystalline lens visible through dilated pupil



**Fig. 2:** Iris hooks used to support capsular bag

GSLSL. She has normal axial lengths and never wore glasses prior to developing the lens-induced myopia. We suggest that ectopia lentis should always be considered in cases of unexplained adult-onset progressive myopia as well as narrow angle glaucoma occurring in individuals known to be myopic. We also draw attention to the surgical technique used. Whereas in the past most subluxated cataracts were removed via intracapsular technique followed by anterior chamber lens implant, the use of iris hooks and capsular tension ring in combination with small incision phacoemulsification can give very satisfactory results, allowing in-the-bag insertion of posterior chamber implants.

#### **Author's affiliation**

Imran Akram  
Ophthalmology Department  
Stoke Mandeville Hospital  
Aylesbury HP21 8AL, UK

#### **REFERENCES**

1. **McCulloch C.** Hereditary lens dislocation with angle closure glaucoma. *Can J Ophthalmol.* 1979; 14: 230-34.
2. **Malbran ES, Croxatto JO, D'Alessandro C, Charles DE.** Genetic late spontaneous subluxation of the lens. *Ophthalmology* 1989; 96: 223-9.
3. **Hagan JC III, Lederer CM Jr.** Primary angle closure glaucoma in a myopic kinship. *Arch Ophthalmol.* 1985; 103:363-5.
4. **Hagan JC III, Lederer CM Jr.** Genetic spontaneous late subluxation of the lens previously reported as a myopic kinship with primary angle closure glaucoma. *Arch Ophth* 1992; 110: 1199-1200.