

# Results and Complications of Photorefractive Keratectomy

Aneeq Ullah Baig Mirza, Khalid Masood Ashraf

*Pak J Ophthalmol 2006, Vol. 22 No. 3*

.....  
See end of article for  
authors affiliations  
.....

Correspondence to:  
Aneeq Ullah Baig Mirza  
Assistant Professor  
Ophthalmology  
Islamic International Medical  
College/ Railway Teaching  
Hospital, Rawalpindi

Received for publication  
November 2005  
.....

**Purpose:** To evaluate the results and identify the complications after photorefractive keratectomy (PRK).

**Materials and Methods:** This retrospective study was conducted at Laser Vision Center, Model Town, Lahore. It comprised of 200 patients(400 eyes) that underwent PRK on Summit Apex Plus excimer laser from 20<sup>th</sup> Feb 2004 to 3<sup>rd</sup> June 2005. All consecutive patients with complete relevant data were included in the study. Three months postoperatively, the uncorrected visual acuity and complications in each eye, were recorded. The overall result was designed, based upon the postlaser uncorrected vision, residual refractive error, quality of vision and complications.

**Results:** Out of 400 eyes, 383(95.9%) had a best corrected visual acuity of 6/9 or better preoperatively. At three months postoperatively, 369 eyes (92.3%) had an uncorrected vision of 6/9 or better. 51 eyes (12.8%) lost 2 or more lines of uncorrected visual acuity postoperatively. The main complications affecting the quality of vision postoperatively were under correction in 33 eyes (8.3%), poor contrast, shades, haloes and glare in 15 eyes (3.8%) and dry eye symptoms in 34 eyes (8.5%). The overall result was excellent in 311 eyes (77.8%).

**Conclusion:** We believe that PRK is a reasonably safe and effective procedure for the correction of low to moderate myopia.

The primary motivation behind PRK is decreased dependence upon glasses and better cosmesis. It is effective for low to moderate myopia, myopic astigmatism and low grades of hypermetropia.

PRK employs 193nm argon fluoride excimer laser which ablates the anterior corneal stroma to a new radius of curvature, thus correcting ametropia<sup>1</sup>.

Cornea has an extremely high absorption coefficient at 193nm. 193-nm photon has sufficient energy to directly break carbon-carbon and carbon-

nitrogen bonds that form the peptide backbone of corneal collagen molecules<sup>2</sup>.

Before proceeding with PRK, one must exclude progressive myopia, history of autoimmune disease and dermal keloid formation. Computerized videokeratography is essential for preoperative detection of subclinical keratoconus and contact lens induced corneal warpage<sup>3</sup>.

The most frequently reported complications include glare, haloes, difficulty with night vision, decreased contrast sensitivity, transient increase in intraocular pressure (IOP), mild subepithelial haze

and myopic regression. The corneal haze appears after a few weeks, peaks in intensity at 1 to 2 months and gradually disappears in the following 6 to 12 months. As a parameter of efficacy the dioptric refractive outcome is less meaningful than uncorrected visual acuity.

Visual improvement after PRK is slow but the severity of complications is far less as compared to Lasik.

## MATERIALS AND METHODS

A retrospective study of 400 eyes (200 patients) who underwent photorefractive keratectomy from 20<sup>th</sup> Feb 2004 to 3rd June 2005 at Laser Vision Center, Model Town, Lahore was conducted. All patients with complete relevant data consecutively, were included in the study.

The following data was collected from the patient's profile:

Name, age, sex, pre-laser refraction and best-corrected visual acuity, whether or not contact lens wearer, any other positive finding, laser settings, use of Mitomycin-C intraoperatively for high myopic eyes, complications of the procedure, unaided visual outcome 3 months post laser and any residual refractive error.

Based upon the above data, the number of patients and percentage in different visual groups pre and postoperatively was calculated. The percentage of cases with lost 2 or more lines of uncorrected visual acuity three months post-laser was calculated.

The overall result was designed based upon the final uncorrected visual acuity, residual refractive error and quality of vision. It was graded and categorized as follows:

**Excellent:** Visual acuity of 6/6 or comparable (post-laser uncorrected vision equal to the pre-laser corrected vision), emmetropia, good quality vision and no complications.

**Good:** Visual acuity of 6/6 to 6/7.5, residual refractive error  $\leq$  1.0 D, good quality vision and no complications or lost 1 line of pre-laser vision.

**Fairly Good:** Visual acuity of 6/6 to 6/9, residual refractive error of -1.0 to -1.50DS, good quality vision and no complications or lost 2 lines of pre-laser vision.

**Fair:** Visual acuity of 6/6 to 6/12, residual refractive error  $\leq$  -1.50DS with complaints of haze, decreased contrast, glare etc or lost 3 lines of pre-laser vision.

**Poor:** Visual acuity of 6/6 to 6/18, residual refraction  $>$  -1.50 D and complaints of haze, decreased contrast, glare etc or lost four lines of pre-laser vision.

## RESULTS

Of the 200 patients studied 78(39%) were males and 122(61%) were females. 78 patients were contact lens wearers while 122 were not (Graph1). Majority of the patients were in 20 to 24 years age group (41.5%) and 25-29 years age group (35%) (Table 1).

The pre-laser best corrected vision was 6/9 or better in 383 eyes (95.8%) (Table 2). The unaided vision 3 months post-laser was 6/9 or better in 369 eyes (92.3%) (Table 3). 51 eyes (12.8%) lost 2 or more lines of uncorrected visual acuity postoperatively (Graph 2).

The main complications of the procedure were under correction in 33 eyes (8.3%), dry eye symptoms in 34 eyes (8.5%) and complaints of poor contrast, shades, haloes or glare in 15 eyes (3.8%) (Table 4 and Graph 3). Minimal haze was seen in 85 eyes (21.3%). Since it did not effect the vision, it was not considered a complication.

The overall result was graded excellent in 311 eyes (77.8%) (Table 5 and Graph 4).

## DISCUSSION

PRK employs 193nm argon fluoride excimer laser to ablate and reshape the anterior corneal stroma. It is reasonably safe and effective for the treatment of mild to moderate myopia. The purpose of this study was evaluation of the results and identification of complications of PRK.

Our study consisted of 400 eyes with myopia ranging between -1.0 and -11.0D. At three months post-operatively 369 eyes(92.3%) achieved an uncorrected vision of 6/9 or better. 72.5% had an uncorrected visual acuity of 6/6. 12.8% of the eyes had a post laser uncorrected vision of 6/9 or less (which was considered as 2 or more lines lost). The last figure was much higher than the previous studies because of two reasons. Firstly, we took under consideration the post-laser uncorrected vision instead of best corrected vision. As the motivation for PRK is to get rid of glasses, the significance of post-laser uncorrected vision cannot be overemphasized. Secondly, considering the sensitive nature of the procedure, an acceptable below normal result was taken, when the vision was less than 6/6 but better than 6/9. In our

study, 2 or more lines lost, meant an uncorrected vision of 6/9 or less rather than 6/12 or less.

In the Summit phase III study, 701 eyes with myopia between -1.50 and -6.0D were enrolled<sup>4</sup>. Of these patients, 90.7% had an uncorrected visual acuity of 6/12 or better. 66.3% had an uncorrected visual acuity of 6/6 or better. Less than 1% lost 2 or more lines of best corrected visual acuity. In the VISX Food and Drug Administration study of 691 eyes with myopia ranging from -1.0 to -6.0D, 85% of the eyes had a visual acuity of 6/12 or better<sup>5</sup>. 1% of the eyes lost 2 more lines of best corrected visual acuity.

**Table 1:** Percentage of myopic eyes and different age group

Age in years	Frequency (%)	Cumulative (%)
15-19	16.0 (4.0)	4.0
20-24	166.0 (41.5)	45.5
25-29	140.0 (35.0)	80.5
30-34	46.0 (11.5)	92.0
35-39	24.0 (6.0)	98.0
40-44	8.0 (2.0)	100.0
Total	400 (100)	

**Table 2:** Pre-laser best-corrected visual acuity

Vision	Frequency (%)	Cumulative (%)
6/18	5 (1.3)	1.3
6/12	12 (3.0)	4.3
6/9	37 (9.3)	13.5
6/7.5	17 (4.3)	17.8
6/6	329 (82.3)	100.0
Total	400 (100)	

**Table 3:** Post-laser uncorrected visual acuity

Vision	Frequency (%)	Cumulative (%)
6/60	1 (0.3)	0.3
6/36	1 (0.3)	0.5

6/24	1 (0.3)	0.8
6/18	3 (0.8)	1.5
6/12	25 (6.3)	7.8
6/9	58 (14.5)	22.3
6/7.5	21 (5.3)	27.5
6/6	290 (72.5)	100.0
Total	400 (100)	

**Table 4:** Complications

Complications	Frequency (%)
None	278 (69.5)
Moderate haze	3 (0.8)
Scarring	3 (0.8)
Undercorrection	33 (8.3)
Overcorrection	7 (1.8)
Poor contrast, shades, haloes, glare	15 (3.8)
Night vision problem	7 (1.8)
Dry eye symptoms	34 (8.5)
Raised intraocular pressure (IOP)	4 (1.0)
Pain on reading	4 (1.0)
Near vision problem	10 (2.5)
Epithelial erosions	2 (.5)
Total	400 (100)

**Table 5:** Overall result

Results	Frequency (%)	Cumulative (%)
Poor	3 (0.8)	0.8
Fair	37 (9.3)	10.1
Fairly good	31 (7.8)	17.9
Good	18 (4.5)	22.4
Excellent	311 (77.8)	100

Total	400 (100)	
-------	-----------	--

The main complications seen at 3 months post-laser visit were, under correction in 33 eyes (8.3%) complaints of poor contrast, shades, glare or haloes in 15 eyes (3.8%) and dry eye symptoms in 34 eyes (8.5%). The most serious of the complications was corneal scarring seen in 3 eyes (0.8%). 2 of the eyes were high myopes with pre-laser refractive error of -11.0D in both eyes. Pre-laser best-corrected vision was 6/12 in each eye. Post-laser uncorrected vision

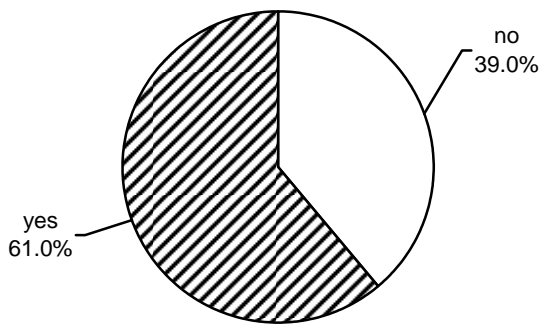


Fig. 1: Percentage of contact lens wearers

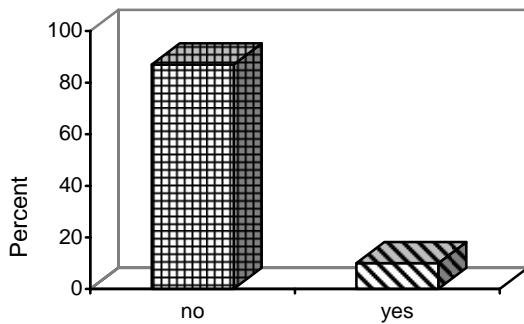


Fig. 2: Percentage of cases which lost 2 or more lines of uncorrected visual acuity

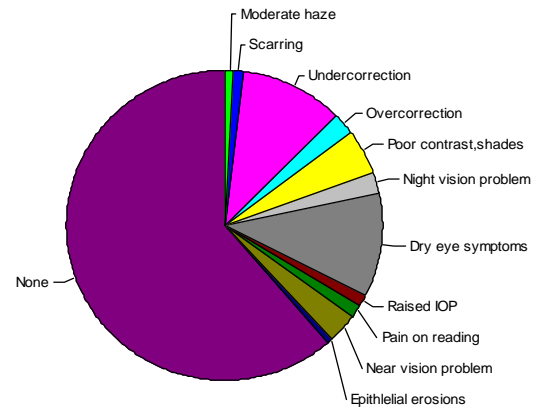


Fig. 3: Complications after PRK

was 6/36 and 6/60 respectively. 0.02% Mitomycin-C was applied upon both the eyes for 2 minutes (on the table). One eye with a pre-laser best-corrected vision of 6/6 with -6.50D developed corneal scarring. The post-laser uncorrected visual acuity was 6/9. Most of the studies have indicated that an increased amount of attempted correction is associated with an increased incidence and severity of haze and regression as well as decreased best-corrected visual acuity<sup>6</sup>. Topical intraoperative application of 0.02% Mitomycin-C can reduce haze formation in high myopic eyes undergoing PRK<sup>7</sup>. Subepithelial corneal haze typically appears after 1 month, peaks in intensity and gradually disappears in the coming 6 to 12 months. Histological studies have shown that corneal haze develops as a result of deposition of glycol-saminoglycans, non lamellar collagen and increase in number and activity of stromal keratocytes<sup>8</sup>.

Topical tranilast can reduce corneal haze by suppressing transforming growth factor (TGF) beta 1 synthesis in keratocytes after photorefractive keratectomy<sup>9</sup>. The complaints of decreased contrast sensitivity, ghost images, glare and haloes are related to peripheral spherical aberrations and pupillary diameter. The amount of spherical aberration introduced into the eye after PRK, increases with increased level of attempted correction. Theoretically, the ideal ablation pattern requires additional flattening of the peripheral part of ablation to prevent these aberrations<sup>10</sup>.

Post-laser dry eye symptoms zone in the form of lid heaviness, burning eyes and grittiness was quite common. Ocular surface dryness is related to decreased corneal sensitivity, which is more pronounced in post-lasik eyes as compared to post-PRK eyes. It might be related to the difference in early postoperative level of tear nerve growth factor, which is a potent nerve growth stimulator<sup>11</sup>.

The visual efficacy after PRK depends upon the final uncorrected visual acuity, emmetropia or level of ametropia, quality of vision and complications. The quality of vision was assessed based upon subjective complaints regarding contrast sensitivity, haze, poor night vision, glare and haloes. Accordingly, the overall result was categorized as excellent, good, fairly good, fair and poor.

## CONSLUSION

We conclude that PRK is a reasonably effective procedure for correction of myopia. No serious ocular complications are seen in low to moderate myopic eyes.

### Author's affiliation

Aneeq Ullah Baig  
Assistant Professor Ophthalmology  
Islamic International Medical College/  
Railway Teaching Hospital, Rawalpindi

Khalid Masood Ashraf  
Laser Vision Center, Lahore

## REFERENCE

1. **Salz JJ:** Radial keratotomy versus photorefractive keratectomy. In Thompson FB, Mc Donnell PJ: Color Atlas/Text of Excimer Laser Surgery: The Cornea. New York, Igako-Shoin, 1993, 63-75.
2. **Puliafito CA, Wong K, Steinert RF:** Quantitative and ultrastructural studies of excimer laser ablation of the cornea at 193nm and 248 nanometers. *Lasers Surg Med.* 1987; 7: 155-9.
3. **Wilson SE, Klyce SD:** Screening for corneal topographic abnormalities before refractive surgery. *Ophthalmology.* 1994; 147-52.
4. **Thompson KP, Steinert RF, Stulting RD:** Photorefractive keratectomy with the Summit excimer laser: The phase-III U.S. results. In Salz JJ (ed): Corneal laser surgery. St.Louis, Mosby-year book, 1995; 57-63.
5. **Seiler T, Mc Donnell PJ:** Excimer laser photorefractive keratectomy. *Surv Ophthalmol.* 1995; 40: 89-118.
6. **Taylor HR, Mc Carty CA, Aldred GR:** Predictability of excimer laser treatment of myopia. *Arch Ophthalmol.* 1996; 114: 248-51.
7. **Gambato C, Ghirlando A, Moretto E, et al.** Mitomycin C modulation of corneal wound healing after photorefractive keratectomy in highly myopic eyes. *Ophthalmology.* 2005; 112: 208-18.
8. **Malley DS, Steinert RF, Puliafito CA, et al:** Immunofluorescence study of corneal wound healing after excimer laser anterior keratectomy in the monkey eye. *Arch Ophthalmol.* 1990; 108: 1316-22.
9. **Song JS, Jung HR, Kim HM:** Effects of topical tranilast on corneal haze after photorefractive keratectomy. *J Cataract Refract Surg.* 2005; 31: 1065-73.
10. **Schwiegerling J, Snyder RW.** Corneal ablation patterns to correct for spherical aberration in photorefractive keratectomy. *J Cataract Refract Surg.* 2000; 26: 214-21.
11. **Lee HK, Lee KS, Kim HC, et al:** Nerve Growth Factor concentration and implications in photorefractive keratectomy vs Laser In situ keratomileusis. *Am J Ophthalmol.* 2005; 139: 965-71.