

Phacomorphic Glaucoma: An Easy Approach

Abdul Rasheed Qamar

Pak J Ophthalmol 2007, Vol. 23 No. 2

See end of article for authors affiliations

Correspondence to:
Abdul Rasheed Qamar
Assoc. Prof. of Ophthalmology
University College of Medicine
1-Km Raiwind Road, Lahore

Received for publication
April 2006

Purpose: To study an alternative method to reduce intraocular pressure in phacomorphic glaucoma at the time of cataract extraction.

Design: This is a prospective interventional study from clinical practice.

Material and Method: In 18 patients of phacomorphic glaucoma a modified controlled paracentesis was performed to decrease the intraocular pressure.

Results: In all the patients the intraocular pressure was reduced, so that the cataract extraction could be performed immediately after the modified paracentesis.

Phacomorphic glaucoma is more common in developing countries¹. Many patients first time consult for treatment when they have already developed phacomorphic glaucoma. For example in a study in India 3.91% of the cataract patients reported with phacomorphic glaucoma². This is partly because of the reason that most of the patients through centuries of tradition feel that a mature cataract is the proper stage for the cataract operation³. However when phacomorphic glaucoma has developed most of these patients are forced to report immediately because of the pain and sudden loss of vision⁴.

At this stage of the disease the treatment essentially consists of two steps.

1. To reduce intraocular pressure
2. Cataract surgery.

The intraocular pressure is usually reduced medically⁵ but some of the authors have reported successful results with Neodymium -Yag laser iridotomy³.

The medical treatment normally consists of:

1. Acetazolamide 500mg by intravenous injection.
2. Glycerine 1-1.5 g / Kg body weight.

3. 20% Mannitol Infusion. 1-2Gm / Kg body weight.

However medical treatment is uncomfortable, time consuming and not always successful.

MATERIALS AND METHODS

In a prospective interventional case series of 18 patients, between 2003 to 2005, I have used controlled paracentesis to reduce the intraocular pressure immediately before cataract extraction.

Procedure

Patients are prepared as for normal cataract extraction. However because postoperative inflammatory response is more common in these patients, intense topical steroids are administered preoperatively. It is better not to operate under topical anesthesia because the eye with phacomorphic glaucoma is very sensitive and the patient is usually apprehensive.

With a No. 11 blade a small nick is made on "clear cornea" about half thickness of the cornea. I being right handed make this nick superotemporally in the right eye and superonasally in the left eye. A disposable insulin syringe with attached fixed 27 gauge needle is taken. The plunger should not be

pulled back. The needle is gradually inserted into the anterior chamber at the site of the nick with its bevel anteriorly to avoid occlusion by the iris. When the tip of the needle has just entered the anterior chamber, index finger is placed at the back of the plunger to avoid a gush of aqueous into the syringe (Fig 1).

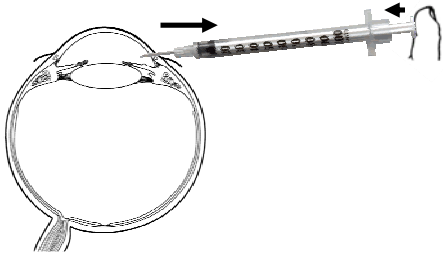


Fig. 1: The insulin syringe is used to remove the aqueous from the anterior chamber. Normally there is very high pressure in the anterior chamber (large arrow). To prevent sudden gush of aqueous a counterforce is applied on the plunger of the syringe (Small arrow). This counter force is then very slowly released to allow aqueous into the syringe.

Now the pressure on the plunger with the index finger is gradually released to allow the influx of the aqueous into the syringe. When 0.3 to 0.5 ml of aqueous has entered the syringe the cornea starts clearing. The IOP can be assessed by indenting the cornea with a blunt instrument. Normally no suction force is required. However if the pressure is not considered satisfactory the tip of the needle with its bevel still anterior should be taken close to the pupil and very slight suction applied to remove the aqueous trapped behind the iris. Once IOP is considered to be satisfactory, the syringe is removed.

Now the cataract extraction can be completed in a usual manner. I performed phacoemulsification in all cases. Because the iris is already inflamed, a bold peripheral iridectomy is a must at the end of the procedure. If cataract is removed with phacoemulsification, iridectomy is difficult because of the tunnel incision. In this case a separate small incision should be made for the iridectomy. I don't stitch this incision.

RESULTS

In all the patients, the IOP was reduced sufficiently to make the cornea clear and immediately proceed with the cataract extraction.

Four of my patients had complications which are not directly related with the procedure to reduce IOP. They are as follows:

Posterior Capsule Rupture	1 patient
Fibrinous exudate in AC	4 patients
Postoperative Glaucoma	2 patients

DISCUSSION

The ultimate treatment of phacomorphic glaucoma is the cataract extraction⁷. Control of intraocular pressure which is usually very high in these cases, is a prerequisite of surgery. Normally intraocular pressure is reduced medically⁵, but it is time consuming and unpredictable. The nausea and vomiting which is associated with the medical treatment adds to the miseries of a patient who is already in agony. Moreover in certain situations it is not possible to wait for the medical treatment to be effective, like when the patient is already too late or when operating a very heavy list of an eye camp.

The intraocular pressure in these patients should be brought down very gradually otherwise there is a risk of expulsive hemorrhage. So any uncontrolled paracentesis is dangerous. The procedure I have described is only a modified controlled paracentesis in true sense. In fact the crux of the procedure is the slowness.

The surgery in phacomorphic glaucoma is associated with more complications than surgery in normal cataract⁷. Fibrinous exudate in AC is one of the most common complication reported in literature^{5,7}. In spite of the fact that intense topical steroids were administered preoperatively 4 of my patients developed fibrinous exudates which were then treated by systemic steroids. I don't like subconjunctival or subtenon injections in these patients because the eyes are very sensitive and systemic steroids are more effective for fibrinous exudates in anterior chamber as the basic cause is the broken blood aqueous barrier.

Two patients developed post-operative glaucoma. This was controlled medically. Gonioscopy showed that angle was open and there was heavy pigmentation of the trabecular meshwork. I am not sure this was because of initial inflammatory process

or developed because of apposition of the iris with angle structures during pre-operative period.

I performed phacoemulsification in all patients. Phacoemulsification was easy in these soft cortical cataracts. However I feel extracapsular or even intracapsular cataract extraction can also be performed in usual manner once the IOP is controlled.

CONCLUSION

In conclusion it is recommended not to waste time in medically reducing the intraocular pressure in phacomorphic glaucoma. The intraocular pressure can be controlled reliably by the controlled paracentesis described. The patient should be straightway taken to the operation theatre and intraocular pressure reduced intraoperatively.

Author's affiliation

Abdul Rasheed Qamar
Associate Professor of Ophthalmology
University College of Medicine
1-Km Raiwind Road, Lahore

REFERENCE

1. **Kanski JJ.** Butterworth- Heineman 4th Edition, 1999; 229.
2. **Angra SK, Pradhan R.** Cataract induced glaucoma an insight into management. Indian J Ophthalmol. 1991; 39: 97-101.
3. **Tomey KF, Al-Rajhi AA.** Neodymium: YAG laser iridotomy in the initial management of phacomorphic glaucoma. Ophthalmology. 1992; 99: 660-5.
4. **Krishnadas R, Ramakrishnan R.** Secondary Glaucomas: The Tasks Ahead Community Eye Health. 2001; 14: 40-2.
5. **McKibbin M, Gupta A, Atkins AD.** Cataract extraction and intraocular lens implantation in eyes with phacomorphic or phacolytic glaucoma. J Cataract Refract Surg. 1996; 22: 633-6.
6. **Gressel MG.** Lens-induced glaucoma. In: Tasman W, Jaeger E, eds. Duane's Clinical Ophthalmology. 5th ed. Philadelphia: Lippincott Williams & Wilkins. 1998: 554.
7. **Johnson CN.** Heparin prophylaxis for intraocular fibrin. Ophthalmology. 1987; 94: 597- 601.

In glaucoma target IOP is considered that pressure where further optic nerve damage is unlikely. Recommended level of target IOP is below 13mm of Hg.

Prof. M Lateef Chaudhry